

CASE REPORT

Ischaemic cardiomyopathy and embolic stroke in a young adult with suspected synthetic cannabinoid use

Sumera Khan,¹ Ahmad Hanif,² Michael F Wilson^{3,4}¹Roswell Park Cancer Institute, Buffalo, New York, USA²Department of Medicine, Roswell Park Cancer Institute, Buffalo, New York, USA³University at Buffalo – The State University of New York, Buffalo, New York, USA⁴Nuclear Cardiology and Cardiovascular Computed Tomography, Kaleida Health Hospitals, Buffalo, NY, USA**Correspondence to**Dr Ahmad Hanif,
ahmad.hanif@roswellpark.org

Accepted 18 May 2018

SUMMARY

The incidence of cardiovascular disease is increasing in young adults. We are reporting a case of acute stroke in a young patient with severe ischaemic cardiomyopathy in the absence of traditional risk factors. After ruling out atherosclerotic disease, his presentation was attributed to synthetic cannabinoid use. We then discussed the typical barriers in early diagnosis and limitations of laboratory testing in this condition. Due to the increase in abuse of these synthetic drugs among young adults, there is a need for high clinical suspicion which can help with early recognition and improve morbidity and mortality associated with these chemicals.

BACKGROUND

Coronary artery disease (CAD) is the leading cause of mortality in the USA and worldwide. An estimated 14.8 million people in the USA carry a diagnosis of CAD.¹ Most of the cases are diagnosed in people aged ≥ 65 years. Recent data suggest a decrease in hospitalisations in the USA due to myocardial infarctions among elderly population, however, the same trend is not observed for young adults.^{2 3} We are writing this case to emphasise on the less known risk factors in young adults which may lead to cardiovascular disease. An accurate history is essential for timely diagnosis which can significantly decrease long-term morbidity and mortality.

CASE PRESENTATION

A 25-year-old African American male resident of a correctional facility was brought to the emergency room with acute-onset confusion, right-sided weakness with bowel and bladder incontinence. He was asymptomatic prior to the start of this episode. He did not report any medical problems and denied any family history of cardiac or neurological diseases. He had a 5 years history of cigarette smoking and quit 2 years ago. Staff from correctional facility expressed concerns about the use of synthetic marijuana as he was found on the bathroom floor with a suspicious substance lying next to him. The officers also gave a history of about five previous episodes of confusion without neurological deficits after exposure to synthetic cannabinoids over the last 6 months. On examination, he was found to be confused with left gaze deviation and right hemiparesis. His cardiovascular and pulmonary examination was otherwise unremarkable.

INVESTIGATIONS

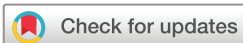The results of blood cell count and routine serum chemistries were within normal limits. Lipid panel showed total cholesterol of 126 mg/dL (7.0 mmol/L), low-density lipoprotein (LDL) level of 67 mg/dL (1.73 mmol/L) and triglycerides 34 mg/dL (0.383 mmol/L). Haemoglobin A1c was normal at 5.5%. The antinuclear antibody (ANA) screen was negative in blood. The results of serum and urine toxicology screen using immunoassay came back negative. A 12-lead electrocardiogram (EKG) revealed Q-waves in leads II, III and AVF along with poor progression of R-wave. CT scan of head showed a large subacute ischaemic left middle cerebral artery infarct with associated cerebral oedema suspicious for cardioembolic stroke. Echocardiogram showed severely reduced left ventricular ejection fraction (EF) of 20%–30% with periapical akinesis and severe hypokinesis of the mid to apical anterior wall. There was no evidence of left ventricular thrombus or patent foramen ovale on echocardiography. Cardiac enzymes were cycled three times and remained negative. During the hospital course, he was noted to have swelling of left upper extremity and a Doppler ultrasound showed acute deep venous thrombosis in the left brachiocephalic vein. Further hypercoagulable workup revealed a high coagulation factor VIII activity level of 384%.

DIFFERENTIAL DIAGNOSIS

In a young individual with a normal lipid profile and no family history of premature CAD, the diagnosis of acute ischaemic stroke along with ischaemic cardiomyopathy triggered workup for unusual causes. Due to reports of synthetic marijuana use from correctional facility, the diagnosis of cannabinoid-induced cardiovascular disease was considered. He was also found to have a high factor VIII protein activity level which can be associated with venous as well as arterial thrombosis leading to ischaemic strokes and myocardial infarction.⁴ Lastly there is possibility of genetic mutations affecting cholesterol transfer pathways resulting in premature CAD although we did not obtain genomic testing on this patient.

TREATMENT

The working diagnosis was acute embolic stroke with chronic ischaemic cardiomyopathy due to synthetic cannabinoid use. Decompressive left



To cite: Khan S, Hanif A, Wilson MF. *BMJ Case Rep* Published Online First: [please include Day Month Year]. doi:10.1136/bcr-2018-224755

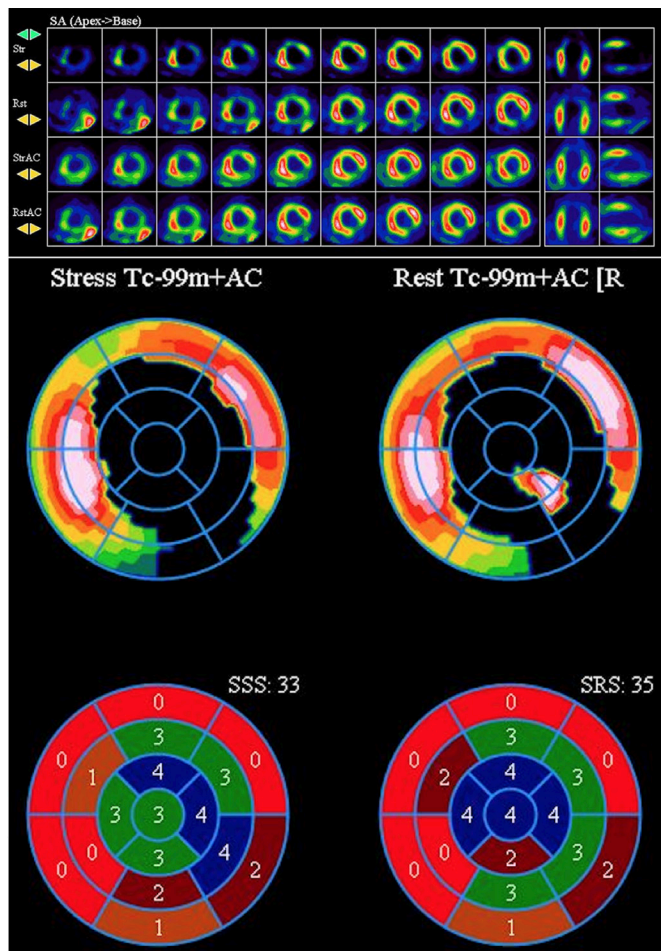


Figure 1 Cardiac stress imaging with Tc99m. Tomographic images revealing a large size, severe in intensity infarct within the mid to apical anterior, mid to apical inferior and apical segments. There is additionally mild intensity, small in size inferolateral peri-infarct ischaemia, with a sum difference score of 2. Visually normal TID of 0.76. Polar display confirms tomographic results. Gated images reveal periapical akinesis, severe hypokinesis of the mid to apical anterior wall, as well as moderate global hypokinesis. TID, transient ischaemic dilation.

craniectomy was performed for cerebral oedema with improvement in mental status. The patient was started on secondary stroke prevention with aspirin and atorvastatin along with lisinopril and metoprolol for heart failure with reduced EF. He was not started on anticoagulation for DVT due to high risk for intracranial bleeding. His weakness improved with physical therapy and he was discharged to acute rehabilitation centre.

OUTCOME AND FOLLOW-UP

The patient was lost to follow-up after discharge and re-established care 1 year later. He was started on anticoagulation for hypercoagulable state. His neurological deficits initially improved with physical therapy and then remained stable. For further evaluation of cardiomyopathy, a myocardial perfusion scan was obtained with Tc99m after Regadenoson stress which showed a large infarct involving the apical, apical anterior and apical inferior segments with mild peri-infarct ischaemia (see figure 1).

DISCUSSION

This is an interesting case of a young adult with significant cardiovascular disease in the absence of traditional risk factors of smoking, obesity, diabetes, hypertension and family history. In our case, the presumptive diagnosis of synthetic cannabinoid-induced myocardial infarction and ischaemic stroke was made based on a clinical history. Despite the negative urine toxicology, the suspicion of synthetic cannabinoids use remained the most probable diagnosis since traditional toxicology immunoassays aimed at detecting tetrahydrocannabinol (THC), the active ingredient in marijuana, are often not able to detect synthetic variants of illicit drugs.⁵ An interesting finding in this case was the high level of factor VIII protein activity which is associated with venous thromboembolism but arterial clot formation is rare. Furthermore, factor VIII levels can be elevated in the setting of acute inflammation and hence, this diagnosis remained low on our differential.

Synthetic cannabinoids (also known as K2 or Spice) are a heterogeneous group of street drugs that are different from THC in chemical structures and potency but activate the same cannabinoid receptors in brain creating a euphoric high after inhalation or ingestion.⁶ Multiple studies have demonstrated the increased risk of myocardial infarctions and ischaemic strokes with use of synthetic cannabinoids.⁷⁻¹¹ Other frequent side effects reported with synthetic cannabinoid use are anxiety, psychosis, tachycardia, bradycardia, chest pain, hypotension, syncope, acute tubular necrosis and thromboangiitis obliterans.¹²⁻¹⁶ The mechanism of cardiovascular side effects is largely unknown but thought to be related to haemodynamic stress caused by synthetic cannabinoids due to their sympathomimetic effect. These can include tachyarrhythmias, hypertension, postural hypotension and arterial spasm.¹⁷

Synthetic cannabinoids are classified as schedule I substances by Drug Enforcement Administration (DEA). However, its use among young adults in the USA is increasing due to ease of availability and cheap cost.¹⁸ In our case, the use of this drug may be the cause of severe ischaemic cardiomyopathy and ischaemic stroke with permanent right-sided weakness, thus leading to severe morbidity in a young adult. There is a need for education among general public and healthcare providers regarding the dangers associated with the use of synthetic drugs. The development of immunoassays aimed at detecting these drugs in serum or urine will also help in stratifying the population at-risk. However, the diversity among different drugs under this common umbrella of 'synthetic marijuana' will remain a barrier to successful testing of all chemicals with a single battery of tests.

Learning points

- ▶ Synthetic cannabinoids are human-made chemicals that all bind to cannabinoid receptors, but vary significantly in their structure and side-effects profile.
- ▶ Their use has been associated with development of cardiovascular disease in the absence of traditional risk factors.
- ▶ Traditional toxicology immunoassays are often not able to detect synthetic variants of illicit drugs.
- ▶ Cardiovascular disease in young adults should prompt a careful investigation into family history, inherited disorders of cholesterol metabolism, hypercoagulability and substance abuse.

Contributors All authors contributed to the writing of this manuscript. SK wrote the case report and discussion. AH performed the literature search. MFW edited the paper and did final approval.

Funding The authors have not declared a specific grant for this research from any funding agency in the public, commercial or not-for-profit sectors.

Competing interests None declared.

Patient consent Obtained.

Provenance and peer review Not commissioned; externally peer reviewed.

© BMJ Publishing Group Ltd (unless otherwise stated in the text of the article) 2018. All rights reserved. No commercial use is permitted unless otherwise expressly granted.

REFERENCES

- Kochanek KD, Murphy SL, Jq X, *et al.* *Deaths: Final data for 2014. National vital statistics reports.* Hyattsville, MD: National Center for Health Statistics, 2016:65:4.
- Chen J, Normand SL, Wang Y, *et al.* Recent declines in hospitalizations for acute myocardial infarction for Medicare fee-for-service beneficiaries: progress and continuing challenges. *Circulation* 2010;121:1322–8.
- Gupta A, Wang Y, Spertus JA, *et al.* Trends in acute myocardial infarction in young patients and differences by sex and race, 2001 to 2010. *J Am Coll Cardiol* 2014;64:337–45.
- Kamphuisen P, Eikenboom J, Bertina R. Elevated Factor VIII Levels and the Risk of Thrombosis. *Arteriosclerosis. Thrombosis* 2001;21:731–8.
- Franz F, Angerer V, Jechle H, *et al.* Immunoassay screening in urine for synthetic cannabinoids - an evaluation of the diagnostic efficiency. *Clin Chem Lab Med* 2017;55:1375-1384.
- Montecucco F, Di Marzo V. At the heart of the matter: the endocannabinoid system in cardiovascular function and dysfunction. *Trends Pharmacol Sci* 2012;33:331–40.
- Jouanjus E, Leymarie F, Tubery M, *et al.* Cannabis-related hospitalizations: unexpected serious events identified through hospital databases. *Br J Clin Pharmacol* 2011;71:758–65.
- Wolff V, Lauer V, Rouyer O, *et al.* Cannabis use, ischemic stroke, and multifocal intracranial vasoconstriction: a prospective study in 48 consecutive young patients. *Stroke* 2011;42:1778–80.
- Jouanjus E, Lapeyre-Mestre M, Micallef J. French Association of the Regional Abuse and Dependence Monitoring Centres (CEIP-A) Working Group on Cannabis Complications*. Cannabis use: signal of increasing risk of serious cardiovascular disorders. *J Am Heart Assoc* 2014;3:e000638.
- Hemachandra D, McKetin R, Cherbuin N, *et al.* Heavy cannabis users at elevated risk of stroke: evidence from a general population survey. *Aust N Z J Public Health* 2016;40:226–30.
- Rumalla K, Reddy AY, Mittal MK. Recreational marijuana use and acute ischemic stroke: A population-based analysis of hospitalized patients in the United States. *J Neurol Sci* 2016;364:191–6.
- Hoyte CO, Jacob J, Monte AA, *et al.* A characterization of synthetic cannabinoid exposures reported to the National Poison Data System in 2010. *Ann Emerg Med* 2012;60:435–8.
- Martin-Blondel G, Koskas F, Cacoub P, *et al.* Is thromboangiitis obliterans presentation influenced by cannabis addiction? *Ann Vasc Surg* 2011;25:469–73.
- Hermanns-Clausen M, Kneisel S, Szabo B, *et al.* Acute toxicity due to the confirmed consumption of synthetic cannabinoids: clinical and laboratory findings. *Addiction* 2013;108:534–44.
- Waugh J, Najafi J, Hawkins L, *et al.* Epidemiology and clinical features of toxicity following recreational use of synthetic cannabinoid receptor agonists: a report from the United Kingdom National Poisons Information Service. *Clin Toxicol* 2016;54:512–8.
- Bhanushali GK, Jain G, Fatima H, *et al.* AKI associated with synthetic cannabinoids: a case series. *Clin J Am Soc Nephrol* 2013;8:523–6.
- Müller HH, Kornhuber J, Sperling W. The behavioral profile of spice and synthetic cannabinoids in humans. *Brain Res Bull* 2016;126:3–7.
- Riederer AM, Campleman SL, Carlson RG, *et al.* Acute Poisonings from Synthetic Cannabinoids - 50 U.S. Toxicology Investigators Consortium Registry Sites, 2010-2015. *MMWR Morb Mortal Wkly Rep* 2016;65:692–5.

Copyright 2018 BMJ Publishing Group. All rights reserved. For permission to reuse any of this content visit <http://group.bmj.com/group/rights-licensing/permissions>.
BMJ Case Report Fellows may re-use this article for personal use and teaching without any further permission.

Become a Fellow of BMJ Case Reports today and you can:

- ▶ Submit as many cases as you like
- ▶ Enjoy fast sympathetic peer review and rapid publication of accepted articles
- ▶ Access all the published articles
- ▶ Re-use any of the published material for personal use and teaching without further permission

For information on Institutional Fellowships contact consortiasales@bmjgroup.com

Visit casereports.bmj.com for more articles like this and to become a Fellow