

Chromosome 14q11.2-q21.1 duplication: a rare cause of West syndrome

Özdem Ertürk Çetin¹, Cengiz Yalçınkaya¹, Birsen Karaman², Veysi Demirbilek¹, Beyhan Tüysüz³

¹ Department of Neurology, Cerrahpaşa Faculty of Medicine, Istanbul University,

² Department of Medical Genetics, Istanbul Faculty of Medicine, Istanbul University,

³ Department of Pediatric Genetics, Cerrahpaşa Faculty of Medicine, Istanbul University, Istanbul, Turkey

Received December 29, 2017; Accepted March 08, 2018

ABSTRACT – Proximal duplication of chromosome 14q, including the *FOXP1* gene located on 14q12, is a rare condition characterised by developmental delay, dysmorphic craniofacial features, epilepsy, and severe speech delay. Here, we report a patient with West syndrome whose chromosome analysis revealed 14q11.2-21.1 duplication. The patient was admitted due to infantile epileptic spasms at eight months of age, motor developmental delay, and dysmorphic features. Chromosome and array-CGH analysis revealed *de novo* 14q11.2-21.1 duplication, spanning ~20 Mb (minimal interval chr14:20203610_40396835). The patient was followed up to 13 years of age, and at the last examination was shown to have severe speech delay, seizures, and continuous spike-and-wave activity on EEG. The possibility of this chromosomal abnormality should be kept in mind in patients with developmental delay, epilepsy, and hypsarrhythmia, in the absence of any structural brain lesion or metabolic aetiology.

Key words: chromosome 14q duplication, West syndrome, epileptic spasms, neurodevelopmental encephalopathy, *FOXP1*-related disorders

Proximal duplication of chromosome 14q, including the *FOXP1* gene located on 14q12, is a rare condition characterised by developmental delay, dysmorphic craniofacial features, epilepsy, and speech delay (Brunetti-Pierri *et al.*, 2011; Pontrelli *et al.*, 2014). Depending on the size of the duplication and the included genes within the region, clinical features may vary between patients. Here, we report a patient with a *de novo* 14q11.2-21.1 chromosome duplication who had a dysmorphic face, epilepsy, and

speech and developmental delay. The aim of this report is to provide additional data in order to define the clinical characteristics of epilepsy associated with 14q duplication.

Case study

The patient was a female born at the 39th week of gestation following an uneventful pregnancy with normal spontaneous delivery. There was no consanguinity between the parents, and family history was unremarkable. The patient's birth weight

Correspondence:
Özdem Ertürk Çetin
Department of Neurology,
Cerrahpaşa Faculty of Medicine,
Istanbul University,
Fatih, Istanbul, Turkey
<ozdemerturk@yahoo.com>

was 2,770 g, with length of 48 cm and head circumference of 34.5 cm. Both maternal and paternal ages at birth were 30 years. The patient has an older healthy sister.

The patient was evaluated at two months of age because of intractable vomiting which was diagnosed as gastroesophageal reflux. The parents first noticed a motor developmental delay at eight months because she was unable to sit. Additionally, she experienced short periods of spasms with loss of consciousness and deviation of the eyes. The attacks lasted a few seconds and subsequently increased in frequency. Examination at 14 months revealed motor developmental delay and

dysmorphic features. She was unable to walk or sit without support. In addition, the attacks had increased to a frequency 9-10 times per day. She showed eye contact and could smile at her parents, however, she demonstrated a poor reaction to her surroundings and could not speak. Her laboratory examinations, including metabolic screening, were normal. EEG showed hypsarrhythmia (figure 1A). She was diagnosed with West syndrome and antiepileptic drugs were administered. Valproic acid, clonazepam, and ACTH were prescribed. Cranial magnetic resonance imaging (MRI) revealed an arachnoid cyst in the bilateral temporal lobes and beneath the third ventricle. Diffuse volume

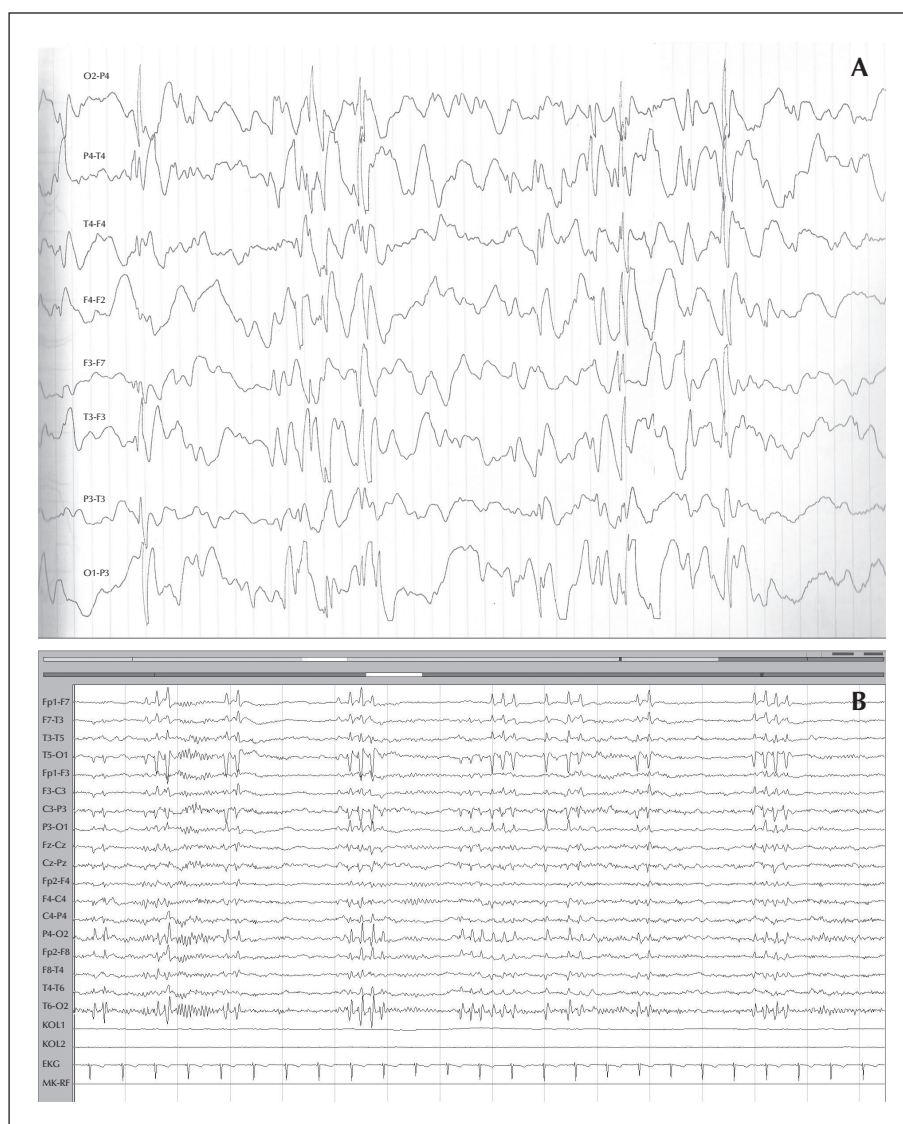


Figure 1. EEG showing hypsarrhythmia at 14 months (A), and diffuse and continuous spike-and-wave paroxysms during sleep at 13 years (B).

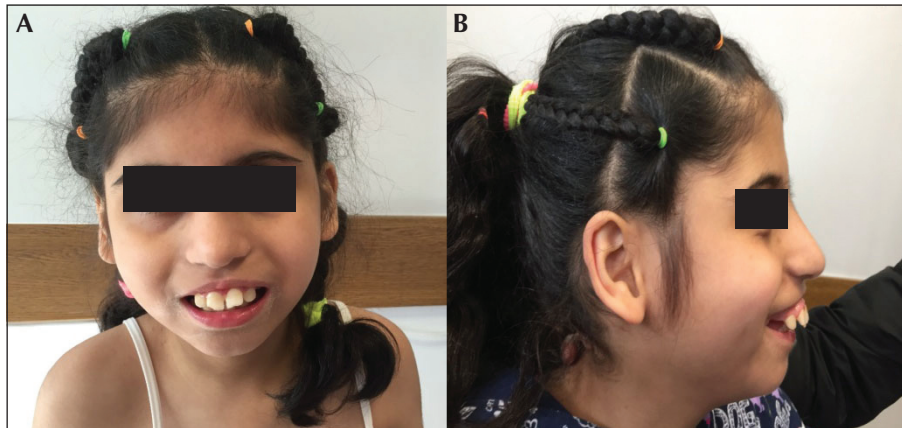


Figure 2. (A, B) Photographs of the patient. Note the triangular face, hypotelorism, deep-set eyes, grey sclera, open-mouth appearance, prominent upper jaw with central incisors, short philtrum (A), and microretrognathia (B).

reduction in the parietal and occipital white matter and enlargement of the frontal subarachnoid spaces were observed.

At two years and 10 months, her body weight was 12 kg (3-10 centile), body length was 86 cm (<3rd centile), and head circumference was 46 cm (<3rd centile). She had a triangular face, hypotelorism, deep-set eyes, grey sclera, a high-arched palate, an open-mouth appearance, a prominent upper jaw and central incisors, short philtrum, micrognathia, and bilateral pes cavus (*figure 2A, B*). She was able to walk with assistance and could manage a few words. Her seizures ceased at two years of age and subsequent EEGs during this time showed no abnormalities. However, she again developed seizures at four years of age, characterized by deviation of the eyes for 5-6 seconds. Also at four years of age, she was able to walk without support, could manage a few words, and was educated in special therapy classes. Her EEGs were normal during wakefulness; during sleep, multifocal spike-and-wave paroxysms were observed. She was diagnosed with arthritis at six years of age and received corticosteroids and methotrexate.

At her last evaluation at 13 years and four months of age, her body weight was 37 kg (10-25th centile), height was 144 cm (3rd-10th centile), and her head circumference was 51.5 cm (3rd-10th centile). She was able to walk unassisted, speak only with a few words, and follow some simple instructions. She had a Denver intelligence quotient score of 35-49, and demonstrated aggressive behaviour.

At present, she still has seizures, with deviation of the eyes and loss of consciousness lasting for seconds, however, the frequency of seizures has decreased to 1-2 per day. Her last EEG at 13 years of age showed diffuse and continuous spike-and-wave paroxysms

during sleep (*figure 1B*). She is now receiving valproic acid at 800 mg/day, levetiracetam at 800 mg/day, and clobazam at 10 mg/day.

Classic and molecular cytogenetic analysis

Standard G-banding chromosome analysis using cultured peripheral blood lymphocytes of the patient revealed 46,XX, dup(14)(q11.2;q21.1) (*figure 3A*). Chromosome analysis in both parents showed normal karyotypes, which indicated a *de novo* duplication.

Oligonucleotide array-CGH was performed using SurePrint G3 Human CGH Microarray ISCA 4 × 180K v2 (Agilent Technologies, Santa Clara, CA, USA). The 180 K kit (180,000 probes) has an overall median probe spacing of 13 kb. Analysis was performed according to the protocol provided by the supplier (Agilent Oligonucleotide Array-Based CGH for Genomic DNA Analysis). The array was scanned using a NimbleGen MS 200. Genomic positions were based on the UCSC February 2009 human reference sequence (hg19) (NCBI build 37 reference sequence assembly).

Array-CGH analysis confirmed a duplication of approximately 20 Mb in size on the long arm of chromosome 14 at 14q11.2 to 14q21.1, arr [GRCh37] 14q11.2q21.1(20203610_40396835)x3, according to the International System for Human Cytogenetic Nomenclature (2016) (*figure 3B*). The region encompasses 203 genes, including *FOXG1*.

Discussion

The clinical features associated with 14q proximal duplication syndrome include developmental

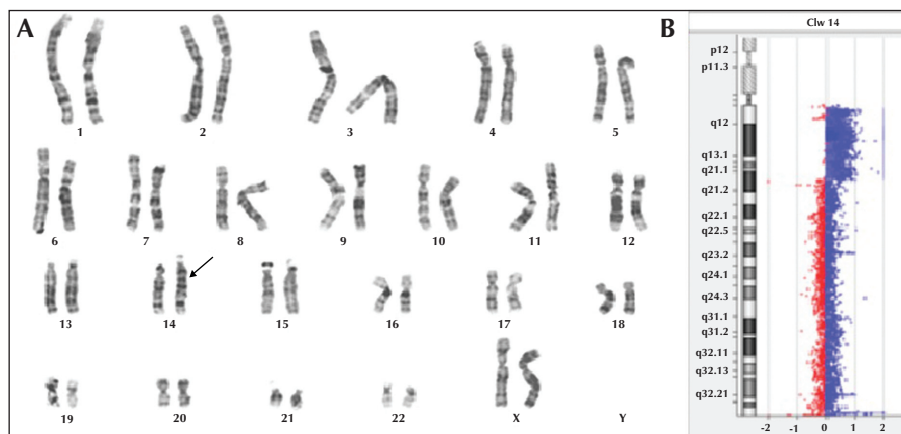


Figure 3. (A) Karyotype of the proband revealed an extra band for chromosome 14. (B) The array-CGH analysis confirmed 14q11.2q21.1 duplication spanning ~20 Mb (minimal interval chr14:20,203,610-40,396,835Mb).

delay, intellectual disability, dysmorphic findings, epilepsy, and speech delay (Yeung *et al.*, 2009; Brunetti-Pierri *et al.*, 2011; Pontrelli *et al.*, 2014; Seltzer *et al.*, 2014).

Here, we report a girl who had chromosome 14q11.2-q21.1 duplication. Her clinical findings were characterized by epilepsy, intellectual disability, severe speech delay, and dysmorphic features including a triangular face, hypotelorism, deep-set eyes, grey sclera, a high-arched palate, an open-mouth appearance, a prominent upper jaw and central incisors, short philtrum, micrognathia, and bilateral pes cavus deformities. The duplication size (~20 Mb) in our patient was large for detection by chromosome and array CGH

analysis. This region contains approximately 203 genes including the *FOXC1* gene.

The *FOXC1* gene is located at 14q12 and plays a role in the regulation of neurogenesis (Brancaccio *et al.*, 2010; Falace *et al.*, 2013). Although large duplications are reported to affect several genes, as in our case, the clinical phenotype of neurodevelopmental delay and epilepsy is believed to be associated with *FOXC1* when one considers the role of *FOXC1* in the developing brain (Brunetti-Pierri *et al.*, 2011). In particular, duplications that include the *FOXC1* gene at chromosome 14q12 are believed to be associated with neurodevelopmental delay and epilepsy (Brunetti-Pierri *et al.*, 2011; Bertossi *et al.*, 2014; Pontrelli *et al.*,

Table 1. Clinical features of patients with 14q duplication including the *FOXC1* gene.

	Present case	Yeung <i>et al.</i> , 2009	Brunetti-Pierri <i>et al.</i> , 2011	Bertossi <i>et al.</i> , 2014	Striano <i>et al.</i> , 2011	Pontrelli <i>et al.</i> , 2014	Yoon <i>et al.</i> , 2016
Number of patients	1	1	7	1	2	1	1
Sex (male/female)	-/1	-/1	6/1	-/1	2/-	1/-	-/1
Age	13 yr	9 yr	6 mo-35 yr	1 yr and 10 mo	3-14 yr	2 yr	1 mo
Duplication size	20 Mb	4.45 Mb	3.1-18.4 Mb	11.84 Mb	3-11 Mb	14.8 Mb	18.3 Mb
Dysmorphic features	yes	yes	4/7	yes	no	no	yes
Epilepsy	yes	yes	4/7	yes	2/2	yes	no
Speech delay	yes	yes	7/7	yes	1/2	NA	-
Developmental delay	yes	yes	7/7	yes	2/2	yes	-

Mb: million bases; yr: year; mo: months; NA: not available.

2014). Patients with deletions and inactivating mutations within the chromosomal region 14q12, including the *FOXP1* gene, have similar clinical features such as developmental delay, hand stereotypies, deceleration of head growth, and epilepsy. However, patients with duplications may be differentiated from those with deletions or inactivating mutations based on certain clinical aspects, such as the ability to walk within two years, severe speech disabilities, earlier seizure onset (seizure onset within the first years of life), the absence of the stereotypic hand movements, and significant microcephaly (Brunetti-Pierri *et al.*, 2011; Pontrelli *et al.*, 2014; Seltzer *et al.*, 2014). Additionally, infantile spasm is the most common seizure type in patients with chromosomal duplication, which is not the case for those with deletions or mutations (Seltzer *et al.*, 2014).

Cardiac anomalies may also be rarely associated with chromosome 14q proximal duplication syndrome. A recent case report documents a new-born with a similar large duplication (18.3 Mb) at chromosome 14q, which was clinically characterized by tetralogy of Fallot and clubfoot. The lack of a classic clinical phenotype was explained by the young age of the patient, and the importance of follow-up visits was highlighted (Yoon *et al.*, 2016).

There is no specific dysmorphic pattern associated with this syndrome. Although there are no dysmorphic features in some patients with duplications of similar size, others are reported to have deep-set eyes, short philtrum, micrognathia, and a prominent jaw (Brunetti-Pierri *et al.*, 2011; Bertossi *et al.*, 2014). Dysmorphic findings may be overlooked because they are not carefully considered in this respect.

There is no common specific MRI pattern for patients with 14q duplication and epilepsy. Non-specific white matter alterations, arachnoid cysts, heterotopic grey matter, and normal MRI are reported. The MRI findings in our patient were also non-specific (Pontrelli *et al.*, 2014; Seltzer *et al.*, 2014).

Epilepsy and West syndrome have previously been reported in association with chromosome 14q proximal duplication syndrome involving the *FOXP1* gene (Striano *et al.*, 2011). The onset of epilepsy occurs within the first year of life, and is most prevalent between three and seven months. Infantile spasm is the most common seizure type, however, generalized and focal seizures may also be observed (Bertossi *et al.*, 2014; Pontrelli *et al.*, 2014). The EEG usually shows hypsarrhythmia, and focal and bilateral epileptiform abnormalities may also be observed. Treatment with ACTH usually reduces seizures and improves the EEG (Seltzer *et al.*, 2014). During follow-up, most patients show normal or almost normal EEG, mild background activity changes, or focal epileptiform abnormalities (Bertossi *et al.*, 2014). Our patient had initial hypsarrhythmia, but later at four years of age, her EEG showed

no abnormality over a period of time. However, at 13 years of age, her EEG again showed continuous spike-and-wave activity, particularly during sleep. In addition, her seizures had not ceased completely. Therefore, it should be kept in mind that more resistant cases may seldom exist.

The clinical features of patients with 14q duplication, including *FOXP1* gene, are summarised in *table 1*.

Conclusion

FOXP1-related disorders may involve several phenotypes (Seltzer *et al.*, 2014; Caporali *et al.*, 2018). The clinical characteristics related to 14q duplication syndrome that involves the *FOXP1* gene include epilepsy, intellectual disability, speech problems, and dysmorphic features. Seizure onset is usually within the first year of life, and infantile spasms and hypsarrhythmic EEG are the most common aspects. Dysmorphic features may be minor. The degree of cognitive involvement may also differ between patients. (Brunetti-Pierri *et al.*, 2011; Pontrelli *et al.*, 2014; Seltzer *et al.*, 2014). Therefore, it is important to consider genetic aetiology in the differential diagnosis of West syndrome, particularly if there are additional dysmorphic features. □

Supplementary data.

Summary didactic slides are available on the www.epilepticdisorders.com website.

Disclosures.

A signed consent form was obtained from the parents of the patient in order to publish the photograph.

None of the authors have any conflict of interest to declare.

References

- Bertossi C, Cassina M, De Palma L, *et al.* 14q12 duplication including *FOXP1*: is there a common age-dependent epileptic phenotype? *Brain Dev* 2014; 36: 402-7.
- Brancaccio M, Pivetta C, Granzotto M, Filippis C, Mallamaci A. *Emx2* and *Foxg1* inhibit gliogenesis and promote neurogenesis. *Stem Cells* 2010; 28: 1206-18.
- Brunetti-Pierri N, Paciorkowski AR, Ciccone R, *et al.* Duplications of *FOXP1* in 14q12 are associated with developmental epilepsy, mental retardation, and severe speech impairment. *Eur J Hum Genet* 2011; 19: 102-7.
- Caporali C, Signorini S, De Giorgis V, Pichiecchio A, Zuffardi O, Orcesi S. Early-onset movement disorder as diagnostic marker in genetic syndromes: three cases of *FOXP1*-related syndrome. *Eur J Paediatr Neurol* 2018; 22: 336-9.
- Falace A, Vanni N, Mallamaci A, Striano P, Zara F. Do regulatory regions matter in *FOXP1* duplications? *Eur J Hum Genet* 2013; 21: 365-6.

Pontrelli G, Cappelletti S, Claps D, et al. Epilepsy in patients with duplications of chromosome 14 harboring FOXP1. *Pediatr Neurol* 2014; 50: 530-5.

Seltzer LE, Ma M, Ahmed S, et al. Epilepsy and outcome in FOXP1-related disorders. *Epilepsia* 2014; 55: 1292-300.

Striano P, Paravidino R, Sicca F, et al. West syndrome associated with 14q12 duplications harboring FOXP1. *Neurology* 2011; 76: 1600-2.

Yeung A, Bruno D, Scheffer IE, et al. 4.45-Mb microduplication in chromosome band 14q12 including FOXP1 in a girl with refractory epilepsy and intellectual impairment. *Eur J Med Genet* 2009; 52: 440-2.

Yoon JG, Shin S, Jung JW, Lee ST, Choi JR. An 18.3-Mb duplication on chromosome 14q with multiple cardiac anomalies and clubfoot was identified by microarray analysis. *Ann Lab Med* 2016; 36: 194-6.

TEST YOURSELF



- (1) What are the electro-clinical characteristics of West syndrome?
- (2) What is the role of the *FOXP1* gene?
- (3) What are the clinical characteristics related to 14q duplication syndrome?

Note: Reading the manuscript provides an answer to all questions. Correct answers may be accessed on the website, www.epilepticdisorders.com, under the section "The EpiCentre".