



# Primary meningeal myxoid liposarcoma with aggressive behavior after recurrence: case report

Noriyuki Watanabe<sup>1</sup> · Haruo Ohtani<sup>2</sup> · Shuichi Mori<sup>1</sup> · Masahiro Iguchi<sup>1</sup> · Alexander Zaboronok<sup>3</sup> · Noriaki Sakamoto<sup>4</sup> · Masahide Matsuda<sup>3</sup> · Eiichi Ishikawa<sup>3</sup> · Akira Matsumura<sup>3</sup>

Received: 3 June 2018 / Accepted: 11 June 2018  
© Springer-Verlag GmbH Austria, part of Springer Nature 2018

## Abstract

Although liposarcomas are the most common soft tissue sarcomas, their intracranial variants are extremely rare. Here, we present a case of a primary intracranial myxoid liposarcoma in a 23-year-old Japanese man who presented with generalized seizures and a mass in the left frontal lobe. The tumor was totally removed, and histological analyses pointed to liposarcoma. Thirteen years after his initial treatment, the patient presented with right-side weakness and local recurrence of tumor was discovered. Histology from the second resection confirmed the diagnosis of myxoid liposarcoma. Shortly after the second resection, progressive, new intracranial lesions were observed and despite a third resection, extensive intracerebral invasion by the tumor proved fatal. The histological features of myxoid liposarcoma were essentially similar with each recurrence, but the aggressive tumor behavior after the second operation did not align with expectations based on histological classification.

**Keywords** Primary tumor · Myxoid liposarcoma · Intracranial · Recurrence

## Introduction

As a common soft tissue sarcoma, liposarcomas are classified into four subtypes: atypical lipomatous tumor/well-differentiated, dedifferentiated, pleomorphic, and myxoid [4]. The myxoid subtype accounts for 20–50% of liposarcomas [4, 5] and most commonly involves the deep, soft tissues associated with the extremities in young to middle-aged adults [4, 8], rarely involving the intracranial space. However, if present, such intracranial tumors are classified

as primary mesenchymal tumors according to the World Health Organization's 2016 guidelines [1] although available data on primary intracranial liposarcomas are limited. To expand the literature on this rare cancer, we present a novel case of a brain-invading, primary meningeal myxoid liposarcoma that resurfaced long after initial onset.

## Case report

### History and examination

In 1997, a 23-year-old Japanese man presented with generalized seizures and no other neurological deficits. Magnetic resonance imaging (MRI) of the brain revealed a well-defined, homogeneously enhanced tumor in the left frontal lobe,  $4.8 \times 3.7 \times 4.5$  cm in size, showing high intensity on T2-weighted images and low intensity on T1-weighted images that seemed to originate from the cerebral falx (Fig. 1a, b, c, d). Preoperative angiography indicated the left middle meningeal artery as the main feeding artery and it was occluded before the tumorectomy with polyvinyl alcohol (PVA) particles via an endovascular procedure.

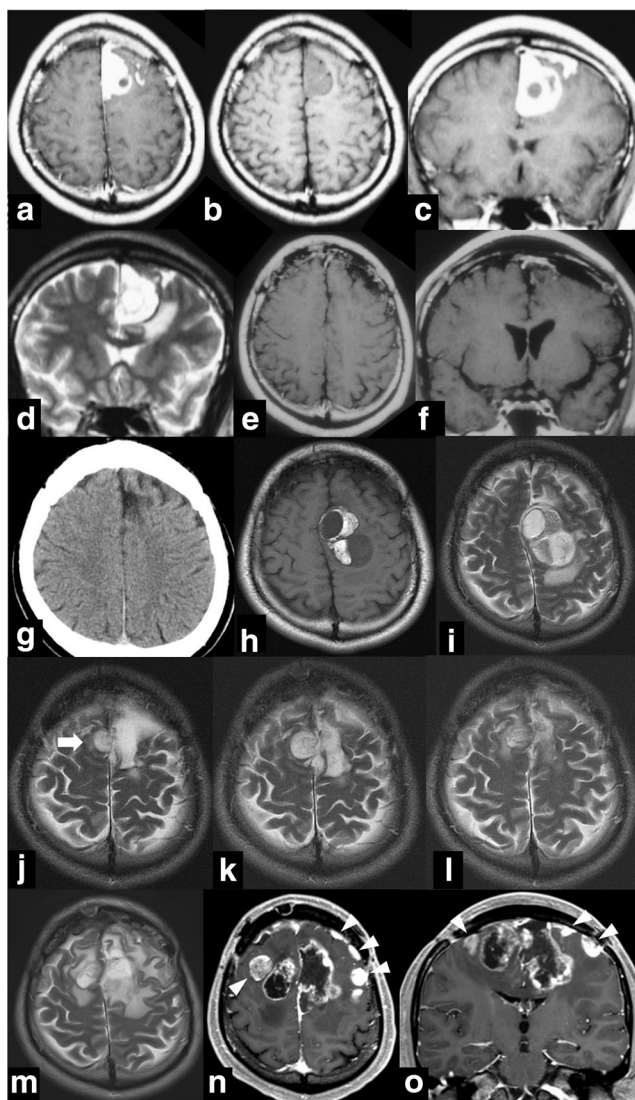
---

This article is part of the Topical Collection on *Brain Tumors*

---

✉ Eiichi Ishikawa  
e-ishikawa@md.tsukuba.ac.jp

- <sup>1</sup> Department of Neurosurgery, Mito Saiseikai General Hospital, Mito, Ibaraki, Japan
- <sup>2</sup> Department of Pathology, Mito Saiseikai General Hospital, Mito, Ibaraki, Japan
- <sup>3</sup> Department of Neurosurgery, Faculty of Medicine, University of Tsukuba, 1-1-1 Tennodai, Tsukuba, Ibaraki 305-8575, Japan
- <sup>4</sup> Department of Diagnostic Pathology, Faculty of Medicine, University of Tsukuba, Tsukuba, Ibaraki, Japan



**Fig. 1** Neuroimaging along the course of the disease. Initial axial T1-weighted MR images with (a) and without (b) gadolinium enhancement, coronal T1-weighted MR image with gadolinium enhancement (c), and coronal T2-weighted MR images (d) reveal left-sided enhancement of a homogeneous mass sized approximately  $4.8 \times 3.7 \times 4.5$  cm with small non-enhanced areas and surrounding edema. Axial (e) and coronal (f) T1-weighted MR images with contrast showed no residual lesions 2 years after the first resection. No recurrence was observed on CT scans until 12 years after the first resection (g). Axial T1-weighted (h) and T2-weighted (i) MR images showing local recurrence in the surgical cavity 13 years after the initial treatment with a size of approximately  $5.0 \times 3.0 \times 33.3$  cm. **j–m** Serial, T2-weighted MR images showing the time course of progression. A new T2-high intensity lesion was detected on the medial right frontal lobe 2 months after the second resection (white arrow) (j). The right frontal lesion and T2-high intensity area in the removal cavity increased over a few months (k). Although once decreased in size after additional irradiation 3 months after the second surgery (l), the T2-high intensity area in the bilateral frontal lobe increased over a half-year period after the second radiation therapy course (m). Axial (n) and coronal (o) T1-weighted MR images with gadolinium enhancement before the third surgery, showing enhancement along the wall of the removal cavity and newly confirmed multiple enhanced lesions in the bilateral frontal lobe (arrow heads) with surrounding edema

## Operation

The patient then underwent a bilateral frontal craniotomy and the tumor was totally removed. On gross examination, the tumor was a hypervascular, lipomatous mass with such a firm adhesion to the falx that excision of the dural attachment was required (Fig. 2a) but there was no obvious invasion into the brain tissue.

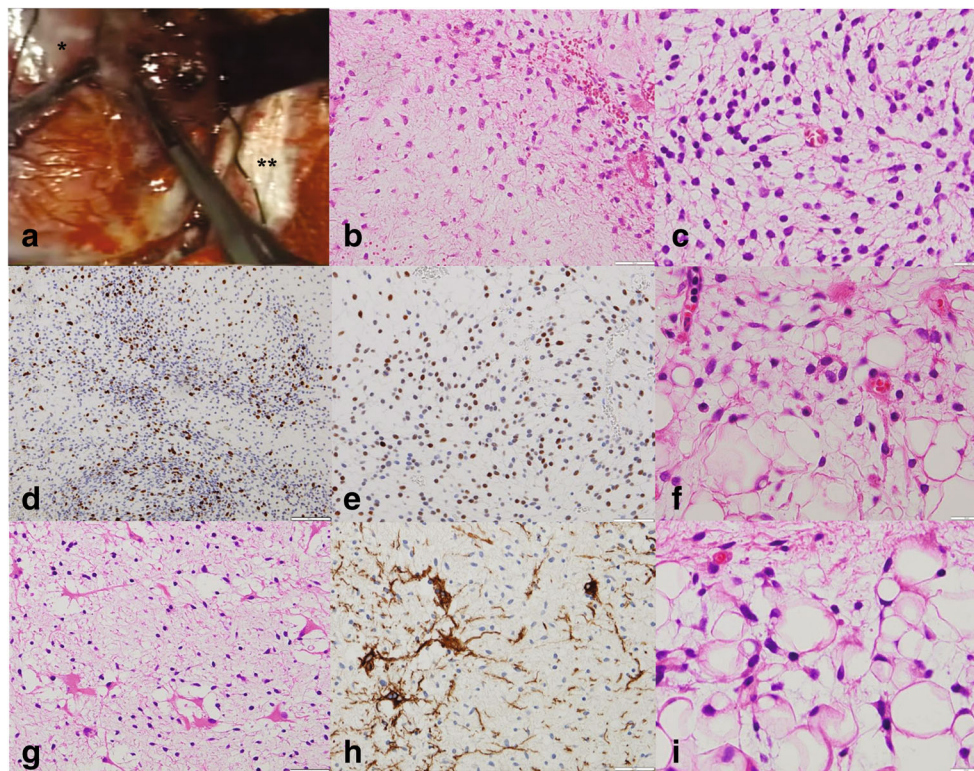
## Pathological findings

Histological evaluation revealed a sporadic distribution of short spindle cells with slight nuclear atypia in a myxoid matrix with the round cell component comprising approximately 20% of the specimen (Fig. 2b, c). The cellularity of tumor cells was higher in the round cell component. No areas showed either dense proliferation of tumor cells or prominent angiogenesis and no mitotic figures were observed. Immunohistochemical stains were approximately 20% positive for Ki-67 in the hot spot area (i.e., in areas of moderate cellularity) (Fig. 2d) and negative for S-100 protein while nuclear overexpression of p53 was observed in approximately 50% of tumor cells (Fig. 2e). The primary histopathological diagnosis at this time was “compatible with liposarcoma.”

## Postoperative course and follow-up

The patient was discharged after a local irradiation series of the surgical cavity with a total dose of 56 Gy. No clear local recurrence was observed during 12 years of follow-ups (Fig. 1e, f, g). However, 13 years and 3 months after the initial treatment, the patient presented with left hemiparesis. MRI showed a local recurrence of the tumor around the surgical cavity (Fig. 1h, i) and a second resection was performed. Intraoperatively, the tumor had solid and gelatinous components and was found attached to the dura of the superior sagittal sinus and the surrounding brain tissue, but there was no visible invasion. The histological findings were essentially similar to those of the first surgery but an occurrence of lipoblastic areas, not observed at the first operation, led to establishing a diagnosis of myxoid liposarcoma (Fig. 2f). As in the first surgery, no mitotic figures or proliferation of “chicken-wire” capillary vasculature were observed, suggesting that the tumor was of a low malignant grade.

Despite these findings, early recurrence was observed in the medial, right frontal lobe approximately 2 months later (Fig. 1j) with a gradual increase in tumor size (Fig. 1k). As gradual tumor growth was seen on the follow-up MRI, additional irradiation (total dose 40 Gy) was performed on the new right frontal lesion and the surgical cavity 3 months after the second resection. The tumor then progressed with multiple new lesions in the bilateral frontal lobes within a year after the second surgery (Fig. 1l, m, n, o).



**Fig. 2** Gross and microscopic findings of the tumor. **a–e** First operation. **f** Second operation. **g–i** Third operation. **a** In the first surgery, a hypervascular lipomatous mass (\*) was seen in the left frontal lobe, which adhered to the surrounding tissues, especially the falx (\*\*). **b** Proliferation of short spindle cells with slight nuclear atypia as seen in a myxoid matrix. H&E staining, original magnification  $\times 40$ . **c** Round cell components were observed in approximately 20% of the specimen. H&E staining, original magnification  $\times 40$ . **d, e** Immunohistochemical staining showing an approximately 20% positive rate for Ki-67 and p53 positivity

A third resection was performed with tumor histology essentially the same as the second operation, i.e., indicative of myxoid liposarcoma where spindle cells without marked cellular atypia were sporadically distributed in the myxoid matrix without obvious proliferation of blood vessels. Focal areas of round cell components were observed as in the first and second operations. Of importance, reactive astrocytes were observed in the myxoid liposarcoma areas, demonstrating intracranial invasion of the tumor (Fig. 2g, h). The Ki-67 positive rate at hot spots was 11.1%, indicating a stepwise decrease (Table 1). No areas in all surgical specimens of the first, second, or third operations showed any high-grade components such as densely distributed round cells without myxoid stroma or dedifferentiated liposarcoma. As seen before, half of the tumor cells did display p53 immunoreactivity but no MDM2 or CDK4 nuclear localization was observed in any specimens from any of the operations. Localization of these two markers is typically observed in atypical lipomatous tumors and dedifferentiated liposarcomas [4]. Subsequent progressive intracranial tumor invasion proved fatal and the total time course after the first operation was 14 years and 6 months. During

in the hot spot area. Original magnification  $\times 10$  and  $\times 20$ , respectively. **f** Prominent vacuolated cells, confirmed as lipoblasts and seen in the second resection, which confirmed the diagnosis of liposarcoma. H&E staining, original magnification  $\times 40$ . **g, h** In the third resection, GFAP-positive reactive astrocytes were observed in the tumor tissue. Note that the tumor mainly retained the features of a myxoid liposarcoma. Original magnification  $\times 20$ . **i** Prominent lipogenic areas (focal abundance of small lipoblasts) were also seen. H&E staining, original magnification  $\times 40$

this observation period, as no tumors were detected in other organs, the present case was judged to be a primary intracranial myxoid liposarcoma.

## Discussion

Primary intracranial liposarcomas are extremely rare [1] and the only six cases we could find in the literature are briefly summarized in Table 2 [2, 5–7, 9, 10]. To the best of our

**Table 1** Results of immunostaining

Surgery	1st	2nd	3rd
Ki-67 labeling index	20%	15%	11%
MDM2	(–)	(–)	(–)
CDK2	(–)	(–)	(–)
p53	(+)	(+)	(+)
S-100 protein	(–)	(–)	(–)
Reactive astrocytes	(–)	(–)	(+)

**Table 2** Summary of primary intracranial liposarcoma cases

Authors	Age at diagnosis (years), sex	Location	Subtype	Immunostaining, FISH	Follow-up duration after diagnosis	Survival time after diagnosis
Kothandaram 1970	2, F	Frontoparietal	N/A	N/A	1 month	1 month
Sima et al. 1976	70, F	Left frontal	Well-differentiated	N/A	3 months	N/A
Cinalli et al. 1997	3, F	Frontoparietal	N/A	Positive for vimentin, negative for vascular markers (HY, CD34, CD31), glial markers (GFA)	1 year	1 year
Mumert et al. 2010	56, M	Right frontal	Pleomorphic	Positive for vimentin, negative for glial fibrillary acidic protein, S-100 protein, epithelial membrane antigen	7 months	N/A
Garciaz et al. 2012	62, M	Right parietal	Dedifferentiated	positive for CDK4 and MDM2 amplifications in FISH, negative for $\alpha$ -smooth actin, CD34, PS100, CD68, EMA	46 months after surgery	N/A
Sivaraju et al. 2015	25, M	Right temporal	Pleomorphic variant	positive for S-100 protein, negative for desmin, myosin, MART-1, cytokeratin, epithelial membrane antigen, glial fibrillary acidic protein, synaptophysin, neurofilament, CD68	N/A	N/A
Present case	23, M	Left frontal	Myxoid	As above	14 years	14 years

*FISH* fluorescence in situ hybridization (abbreviations cited here are exactly the same as in the original text)

knowledge, not a single report listed in PubMed has ever described a primary myxoid liposarcoma originating from the dura.

The course of the present case suggests two important clinical issues. First, myxoid liposarcoma has a potential to relapse even after a decade or more. The longest follow-up of intracranial liposarcoma was reported by Garciaz et al., who described a dedifferentiated liposarcoma in the temporoparietal cranial vault of a 62-year-old man whose tumor was detected 10 years prior to resectioning. This patient underwent resection of the tumor because of lytic progression on the skull and was disease-free for 46 months after tumor removal [5]. In general, the risk of local recurrence is low for low-grade myxoid liposarcoma with an approximately 10% recurrence rate in the extremities over a 5-year period [3]. This could be related to current best practice, as myxoid-type liposarcomas are very sensitive to radiation and mean tumor volumes are markedly reduced after neoadjuvant radiation [3]. Therefore, additional radiation after the initial removal might be generally effective at controlling tumor recurrence.

The second important issue is apparent dissociation between histological findings and biological behavior. In the present case, local recurrence was seen only 2 months after the second resection, and multiple, altered invading lesions were observed less than a year later. In general, a

high proportion of the round cell component and p53 mutation are both associated with a poor prognosis in myxoid liposarcoma [4]. However, these histological findings continued unaltered through the long time course and did not seem to impact patient survival. Other findings regarding tumor proliferation or neovascularization in subsequent surgical specimens were basically similar to the first specimens with the exception of reactive astrocytes in the third specimen. Occurrence of these reactive astrocytes in tumor tissue is generally indicative of increased tumor invasiveness although the detailed role of this finding on the present case remains elusive. The authors speculate that irradiation could have induced invasion by residual lesions although details from the molecular analyses were not definitive evidence of this. As there is currently a lack of detailed data from similar cases, testing our hypothesis will require accumulation of a larger body of evidence from liposarcomas with potential radiation-induced transformation.

In conclusion, we presented a case of terminal, intracranial myxoid liposarcoma that recurred more than 13 years after the initial surgery with apparent dissociation between histological findings and biological behavior. Further clinical data will be beneficial for linking objective clinical and pathological classifications to the biological behavior of intracranial myxoid liposarcomas.

**Acknowledgements** We are grateful to Dr. K. Oka for the primary pathological diagnosis, Dr. I. Emura (Niigata University Hospital) for the helpful suggestions for the diagnosis, and Dr. M. Ito (Shimura Hospital) for supplying clinical data after the third operation. We also thank Dr. Bryan J. Mathis of the University of Tsukuba Medical English Communication Center for the native English language revision.

### Compliance with ethical standards

This manuscript was submitted to and approved by the ethics committee of Mito Saiseikai General Hospital.

**Conflict of interest** The authors declare that they have no conflicts of interest.

**Informed consent** Informed consent was obtained from the patient included in the study.

### References

1. Antonescu CR, Paulus W, Perry A, Rushing EJ, Hainfellner JA, Bouvier C, Figarella-Branger D, von Deiming A, Wesseling P (2016) WHO classification of tumours of the central nervous system. IARC, Lyon
2. Cinalli G, Zerah M, Carteret M, Doz F, Vinikoff L, Lellouch-Tubiana A, Husson B, Pierre-Kahn A (1997) Subdural sarcoma associated with chronic subdural hematoma. Report of two cases and review of the literature. *J Neurosurg* 86:553–557
3. Crago AM, Dickson MA (2016) Liposarcoma: multimodality management and future targeted therapies. *Surg Oncol Clin N Am* 25:761–773
4. Fletcher CDM, Bridge JA, Hogendoorn PCW, Mertens F (2013) WHO classification of tumours of soft tissue and bone. IARC, Lyon
5. Garciaz S, Bouvier C, Roche PH, Salas S (2012) Primary dedifferentiated liposarcoma of the dura mater: case report. *Acta Neurochir* 154:1737–1738
6. Kothandaram P (1970) Dural liposarcoma associated with subdural hematoma. Case report. *J Neurosurg* 33:85–87
7. Mumert ML, Walsh MT, Jensen EM, Jensen RL (2010) Pleomorphic liposarcoma originating from intracranial dura mater. *J Neuro-Oncol* 97:149–153
8. Murphey MD, Arcara LK, Fanburg-Smith J (2005) From the archives of the AFIP: imaging of musculoskeletal liposarcoma with radiologic-pathologic correlation. *Radiographics* 25:1371–1395
9. Sima A, Kindblom LG, Pellettieri L (1976) Liposarcoma of the meninges. A case report. *Acta Pathol Microbiol Scand A* 84:306–310
10. Sivaraju L, Aryan S, Siddappa AK, Ghosal N, Hegde AS (2015) Primary tentorial liposarcoma. *Clin Neuropathol* 34:364–367