

CASE REPORT

Delayed leucoencephalopathy after coil embolisation of unruptured cerebral aneurysm

Yoshihisa Fukushima,¹ Ichiro Nakahara²¹Department of Cerebrovascular Medicine, St. Mary Hospital, Fukuoka, Japan²Department of Comprehensive Stroke, Fujita Health University School of Medicine, Toyoake, Japan**Correspondence to**
Professor Ichiro Nakahara,
ichiro@mub.biglobe.ne.jp

Accepted 29 May 2018

SUMMARY

A 56-year-old right-handed woman was successfully treated by coil embolisation for a large unruptured paraclinoid aneurysm of the left internal carotid artery. Though she was discharged on day 3 after the intervention with uneventful clinical course, she was rehospitalised for continuous headache and right upper limb weakness 2 weeks after the treatment. Subsequent progression of cognitive dysfunction and right hemiparesis were observed. Repeated MRI revealed diffuse leucoencephalopathy within the ipsilateral brain hemisphere. Clinical course, serological examination, and radiological findings were consistent with localised hypocomplemental vasculitis caused by delayed hypersensitivity reaction. Immunosuppressive treatments using prednisolone successfully improved her symptoms. After a washout period for immunosuppressant, skin reaction test was performed and revealed polyglycolic-polylactic acid, coating material of the coil, positive for delayed allergic reaction. Given the increased frequency of endovascular treatment for unruptured aneurysms, even such a rare complication should be recognised and treated properly to avoid neurological sequelae.

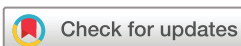BACKGROUND

A few cases of widespread leucoencephalopathy following after coil embolisation of cerebral aneurysm were reported,¹ while a lot of cases of perianeurysmal oedema or aseptic meningitis were assumed to result from its thrombosis and inflammatory reaction.^{2–6} Most cases with leucoencephalopathy were noted to be related to reversible posterior leucoencephalopathy syndrome caused by some kind of mechanical or cytotoxic disruption of blood brain barrier, such as severe hypertension, subarachnoid haemorrhage or contrast agent induced encephalopathy.^{7–11} We described in this report a case of leucoencephalopathy spreading within the hemispheric brain, not bilateral posterior, ipsilateral to the unruptured cerebral aneurysm after coil embolisation, supposed to be caused by delayed hypersensitivity to the bioactive polyglycolic-polylactic acid (PGLA) coil.

CASE PRESENTATION

A 56-year-old right-handed woman was introduced to our hospital for the purpose of coil embolisation to an unruptured paraclinoid aneurysm of the left internal carotid artery (ICA), measuring 11 mm in diameter. She also had chronic urticaria being treated with antihistamine agents by a dermatology clinic from a juvenile period. Coil embolisation

was successfully performed under general anaesthesia. In the treatment, five bare metal and two bioactive PGLA-coated coils were placed into the aneurysm. She was discharged without any complication or abnormality on MRI after the intervention. However, she was rehospitalised because of continuous headache and right upper limb weakness about 2 weeks after embolisation. MRI repeated at 3 weeks after embolisation revealed diffuse leucoencephalopathy spreading within the left brain hemisphere. Subcortical high-intensity signals on T2-weighted, fluid-attenuated inversion recovery and diffusion weighted image with elevated apparent diffusion coefficient indicated vasogenic oedema, and some of these lesions were enhanced by gadolinium on T1-weighted image and showed low-intensity signals on T2 star image indicating microbleeds (figure 1). In contrast, the fairly packed aneurysm on magnetic resonance arteriography had no change and magnetic resonance venography was normal. The white matter lesion localised in the ipsilateral brain hemisphere was naturally supposed to be related to the treatment. Blood cell count and serological data suggested mild systemic inflammation with hypocomplementemia as follows: white cell count $101/10^9$ L with normal differentiation, erythrocyte sedimentation rate (ESR) 35 mm/hour, complement activity <5 U/mL and C1q immunoconjugate 8.1 μ L/mL, besides IgE and C1 inhibitor activity within normal range: IgE 54 IU/mL, C1 inhibitor 127%. No specific autoimmune antibody was detected and cerebral spinal fluid analysis was normal. These serological and radiological examinations were thought to be consistent with hypocomplemental vasculitis, which might be induced by delayed allergic or hypersensitive reaction to the coil component. As hydrocortisone (100 mg two times per day) and edaravone (30 mg two times per day) started immediately after readmission could not prevent subsequent progression of cognitive dysfunction and right hemiparesis, alternated intravenous methylprednisolone pulse therapy (1000 mg daily) followed by oral prednisolone prescription (1 mg per kg daily) and glycerol (20 g per 200 mL three times per day) from the fourth day after rehospitalisation could successfully stop worsening and lead to improve her impairment. Abnormal serological findings, ESR, complement activity and C1q immunoconjugate soon recovered within normal range. She was fully recovered to discharge after 4 weeks except for slight cognitive impairment and residual white matter lesion on MRI.



To cite: Fukushima Y, Nakahara I. *BMJ Case Rep* Published Online First: [please include Day Month Year]. doi:10.1136/bcr-2018-224569

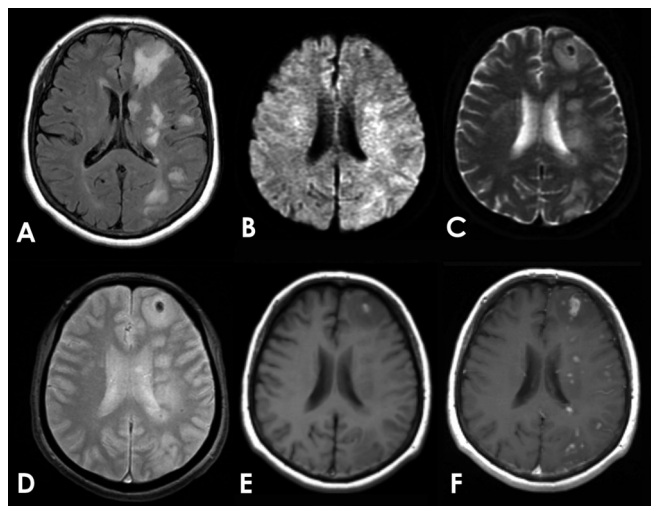


Figure 1 Brain MRI on the rehospitalised day. High-intensity signals on fluid-attenuated inversion recovery (FLAIR) image (A) and diffusion-weighted image (B) with elevated apparent diffusion coefficient in the territory of the left internal carotid artery (C) indicating vasogenic oedema. A micro bleed on T2* weighted image (D) and a small high signal intensity spot on T1-weighted image (E) in the left frontal lobe are shown. Spotty enhanced lesions are also observed within the high-intensity areas of FLAIR image (A) in the left hemisphere on gadolinium-enhanced T1-weighted image (F).

OUTCOME AND FOLLOW-UP

After discharge, oral prednisolone was decreased step by step every 2 weeks in outpatient manner. Though asymptomatic and transient worsening of brain MRI was seen when it was decreased to 10mg daily, short-term increased dose up to 20mg daily resolved it soon. Afterwards, careful decrease to discontinue the prescription was fulfilled after 10 months from the onset. Finally, immunosuppressive treatments using prednisolone successfully resolved her symptoms. Transient worsening dissolved by short-term dose-up of corticosteroid suggested reproductive response to the immunosuppressive treatment. After a month of washout period without any immunosuppressant or anti-allergic agent intake, a skin reaction test was performed to identify which substances might be causing delayed hypersensitivity in the patient. Among metals and other materials consisting the coil, PGLA solution mixed with Vaseline petroleum jelly were proven positive with redness for delayed allergic reaction by the patch test. These results suggested that immune complex-related hypersensitivity to PGLA followed by hypocomplemental vasculitis might cause her delayed hemispheric leucoencephalopathy.

DISCUSSION

We described in this report a case of leucoencephalopathy spreading within the brain hemisphere, not bilateral posterior as posterior reversible leucoencephalopathy syndrome (PRES), ipsilateral to the unruptured cerebral aneurysm after coil embolisation, supposed to be caused by delayed hypersensitivity to the bioactive PGLA coil. Abnormal white matter changes were reported after coil embolisation of basilar apex aneurysms using bioactive PGLA coils at 1 month after the treatment, and hypersensitivity to coil component was indicated as the cause in the previous reports.^{10 11} Because both of them improved spontaneously without definitive diagnosis and aggressive treatment, causal relationship between white matter changes and PGLA coils remained unknown. PRES could not be excluded as an

aetiology for the white matter lesion as their location was both in bilateral occipital subcortex, though their interventions were for basilar apex aneurysm. On the contrary, in this case, the white matter lesion located only within the ipsilateral hemisphere of the treated aneurysm, showing distinctly different pattern from PRES.

Delayed enhancement of lesions may be caused by foreign body reaction due to distal embolisation by fragmentation of the inner coating of microcatheter as reported by Barnwell *et al.*¹² After this report, same kinds of brain lesions indicating foreign body reaction after neurointervention had been reported in the literature.^{13 14} Recently, polyvinylpyrrolidone, one of the hydrophilic coating material, has been the focus as the origin.^{15–17} In addition, Oh *et al* conducted benchtop analysis of evaluation of foreign body material migration due to friction damage of microcatheter.¹⁸ However, in our case, the procedure was uneventfully performed without any unusual friction which might suggest fragmentation of the coated material between the guiding catheter and the microcatheter, between the microcatheter and the microguidewire and also between the microcatheter and the delivery wire of the detachable coil. In our case, the result of the patch test was consistent with the allergic foreign body reaction to PGLA.

Drug-induced hypersensitivity mediated by immune complex is well known as a kind of systemic serum sickness, or rarely as a localized leucocytoclastic vasculitis by arthus reaction. In these instances, immune complexes formation by high concentration of antigen and antibody may result in consumptive hypocomplementemia as shown in our case.^{19–21} Because of these findings in this case, immune complex formation and hypocomplementemia, positive reaction of PGLA to skin reaction test or reproductive reactivity to immunosuppressive treatment, it was suggested that immune complex-mediated hypersensitivity to PGLA might cause localised and delayed leucoencephalopathy. This is the first case report of delayed leucoencephalopathy after coil embolisation was proven to be caused by hypersensitivity to bioactive PGLA coils as far as we are aware in the literature.

Learning points

- ▶ Delayed leucoencephalopathy may occur after coil embolisation of cerebral aneurysm.
- ▶ Localised hypocomplemental vasculitis derived from delayed hypersensitivity to polyglycolic-polylactic acid may be its origin.
- ▶ Immunosuppressive treatments using prednisolone ameliorate this complication.
- ▶ Given the increased frequency of endovascular treatment for cerebral aneurysm, such a rare complication should be recognised and treated properly to keep away from neurological sequelae.
- ▶ Use of bioactive coils might be avoided for a patient with a history of allergy or hypersensitivity.

Contributors Both YF and IN were involved in the management of the patient. YF is the main author of the manuscript. IN provided critical feedback and helped to analyse the data. IN contributed to the final version of the manuscript.

Funding The authors have not declared a specific grant for this research from any funding agency in the public, commercial or not-for-profit sectors.

Competing interests None declared.

Patient consent Obtained.

Provenance and peer review Not commissioned; externally peer reviewed.

© BMJ Publishing Group Ltd (unless otherwise stated in the text of the article) 2018. All rights reserved. No commercial use is permitted unless otherwise expressly granted.

REFERENCES

- Skolarus LE, Gemmete JJ, Braley T, *et al.* Abnormal white matter changes after cerebral aneurysm treatment with polyglycolic-poly(lactic acid) coils. *World Neurosurg* 2010;74:640–4.
- Stracke CP, Krings T, Möller-Hartmann W, *et al.* Severe inflammatory reaction of the optic system after endovascular treatment of a supraophthalmic aneurysm with bioactive coils. *AJNR Am J Neuroradiol* 2007;28:1401–2.
- Schmidt GW, Oster SF, Golnik KC, *et al.* Isolated progressive visual loss after coiling of paraclinoid aneurysms. *AJNR Am J Neuroradiol* 2007;28:1882–9.
- Horie N, Kitagawa N, Morikawa M, *et al.* Progressive perianeurysmal edema induced after endovascular coil embolization. Report of three cases and review of the literature. *J Neurosurg* 2007;106:916–20.
- Fanning NF, Willinsky RA, ter Brugge KG. Wall enhancement, edema, and hydrocephalus after endovascular coil occlusion of intradural cerebral aneurysms. *J Neurosurg* 2008;108:1074–86.
- Craven I, Patel UJ, Gibson A, *et al.* Symptomatic perianeurysmal edema following bare platinum embolization of a small unruptured cerebral aneurysm. *AJNR Am J Neuroradiol* 2009;30:1998–2000.
- Hinchey J, Chaves C, Appignani B, *et al.* A reversible posterior leukoencephalopathy syndrome. *N Engl J Med* 1996;334:494–500.
- Saigal G, Bhatia R, Bhatia S, *et al.* MR findings of cortical blindness following cerebral angiography: is this entity related to posterior reversible leukoencephalopathy? *AJNR Am J Neuroradiol* 2004;25:252–6.
- Shinoda J, Ajimi Y, Yamada M, *et al.* Cortical blindness during coil embolization of an unruptured intracranial aneurysm--case report. *Neurol Med Chir* 2004;44:416–9.
- Niimi Y, Kupersmith MJ, Ahmad S, *et al.* Cortical blindness, transient and otherwise, associated with detachable coil embolization of intracranial aneurysms. *AJNR Am J Neuroradiol* 2008;29:603–7.
- Naito H, Yamazaki Y, Takahashi T, *et al.* [A case of posterior reversible encephalopathy syndrome associated with coil embolization of a basilar apex aneurysm]. *Rinsho Shinkeigaku* 2013;53:518–25.
- Barnwell SL, D'Agostino AN, Shapiro SL, *et al.* Foreign bodies in small arteries after use of an infusion microcatheter. *AJNR Am J Neuroradiol* 1997;18:1886–9.
- Cruz JP, Marotta T, O'Kelly C, O'Kelly C, *et al.* Enhancing brain lesions after endovascular treatment of aneurysms. *AJNR Am J Neuroradiol* 2014;35:1954–8.
- Grewal SS, López Del Valle EM, Gupta V, *et al.* Neurological changes with abnormal brain reactivity following coiling of cerebral aneurysm. possible reactivity to endovascular devices and material? *J Vasc Interv Neurol* 2015;8:28–36.
- Shapiro M, Ollenschleger MD, Baccin C, Becske BT, *et al.* Foreign body emboli following cerebrovascular interventions: clinical, radiographic, and histopathologic features. *AJNR Am J Neuroradiol* 2015;36:2121–6.
- Lorentzen AO, Nome T, Bakke SJ, *et al.* Cerebral foreign body reaction after carotid aneurysm stenting. *Interv Neuroradiol* 2016;22:53–7.
- Chopra AM, Mehta M, Bismuth J, *et al.* Polymer coating embolism from intravascular medical devices - a clinical literature review. *Cardiovasc Pathol* 2017;30:45–54.
- Oh SW, Shin NY, Lee HJ, *et al.* Delayed enhancing lesions after coil embolization of aneurysms: clinical experience and benchtop analyses. *J Neurointerv Surg* 2017;9:1243–7.
- Claudy A. Pathogenesis of leukocytoclastic vasculitis. *Eur J Dermatol* 1998;8:75–9.
- Bruculeri M, Charlton M, Serur D. Serum sickness-like reaction associated with cefazolin. *BMC Clin Pharmacol* 2006;6:3.
- Jennette JC, Falk RJ, Bacon PA, *et al.* 2012 revised international chapel hill consensus conference nomenclature of vasculitides. *Arthritis Rheum* 2013;65:1–11.

Copyright 2018 BMJ Publishing Group. All rights reserved. For permission to reuse any of this content visit <http://group.bmj.com/group/rights-licensing/permissions>.
BMJ Case Report Fellows may re-use this article for personal use and teaching without any further permission.

Become a Fellow of BMJ Case Reports today and you can:

- Submit as many cases as you like
- Enjoy fast sympathetic peer review and rapid publication of accepted articles
- Access all the published articles
- Re-use any of the published material for personal use and teaching without further permission

For information on Institutional Fellowships contact consortiasales@bmjgroup.com

Visit casereports.bmj.com for more articles like this and to become a Fellow