



Bilateral stereotypy after unilateral cerebellar infarction

Soyoun Choi¹ · Chaewon Shin² · Tae-Beom Ahn^{1,2} 

Received: 16 May 2018 / Accepted: 3 June 2018
© Belgian Neurological Society 2018

Abbreviations

MRI	Magnetic resonance imaging
¹⁸ F-FDG	¹⁸ F-fluorodeoxyglucose
¹⁸ F-FP-CIT	¹⁸ F-fluorinated <i>N</i> -3-fluoropropyl-2-beta-carboxymethoxy-3-beta-(4-iodophenyl) nortropane
PET	Positron emission tomography

Dear Editor,

Stereotypy is defined as repetitive and continuous non-goal-directed movement. It was reported in association with various disorders including developmental delay, autism, schizophrenia, tardive dyskinesia, and frontotemporal dementia. There were few cases with stereotypy secondary to cerebral infarctions in the putamen or cerebellum [1].

Here, we report a case with bilateral hand stereotypy after left cerebellar infarction.

An 82-year-old man was admitted to the hospital with acute onset dysarthria and gait disturbance. He was hypertensive and had a 60 pack-year smoking history. A neurological examination showed normal cognition (the Mini-Mental State Examination score = 25), dysmetria, and gait ataxia. Brain magnetic resonance imaging (MRI) showed an acute infarction in the left cerebellar hemisphere (Fig. 1a). He was treated with aspirin and clopidogrel, and discharged with only minimal residual symptoms.

Three weeks after the cerebellar infarction, abnormal movements of the bilateral hands developed. He continuously rubbed both thumbs against the index fingers (Supplemental Video). The movements were temporarily suppressible on demand or decreased when he was distracted. There was no urge to move his hands when he was holding the movements. A follow-up neurological examination showed asymmetric bradykinesia without postural instability in addition to stereotypic movements.

Follow-up neuroimaging studies were performed which revealed multiple areas of hypometabolism including the bilateral high frontal cortex, anterior temporal cortex, anterior cingulate gyrus, and left cerebellum using ¹⁸F-fluorodeoxyglucose (¹⁸F-FDG) positron emission tomography (PET), and decreased uptake in both putamen and caudate nuclei using ¹⁸F-fluorinated *N*-3-fluoropropyl-2-beta-carboxymethoxy-3-beta-(4-iodophenyl) nortropane (¹⁸F-FP-CIT) PET (Fig. 1b).

Medications did not improve his stereotypic movement. Levodopa treatment up to 600 mg/day was neither mitigating his parkinsonism nor aggravating stereotypic movements. The informed consents for the report and Supplemental Video were received from the patient.

The abnormal movements were continuous, patterned, and distractible. Without sensory urge, the movements can be best classified as stereotypy. This is the second case with stereotypy secondary to cerebellar infarction.

While the motor inhibitory system, consisting of the inferior frontal gyrus and pre-supplementary motor area, was underscored in the pathophysiology of stereotypy, the contribution of the cerebellum is also becoming increasingly recognized [2]. In autism, where stereotypy and repetitive behaviors are key motor symptoms, the correlation between these behaviors and the cerebellum (the anterior lobe and lobule VIII) was demonstrated [3]. We also had reported cortical hypometabolism in a patient with stereotypy after cerebellar infarction [1]. In this case, multiple areas including the motor inhibitory system were affected by a solitary lesion in the cerebellum. Therefore, these studies suggest that the cerebellum may play a leading role in the development of stereotypy via recruiting critical areas.

Electronic supplementary material The online version of this article (<https://doi.org/10.1007/s13760-018-0958-0>) contains supplementary material, which is available to authorized users.

✉ Tae-Beom Ahn
taebeom.ahn@khu.ac.kr

¹ Kyung Hee University College of Medicine, Seoul, Republic of Korea

² Department of Neurology, Kyung Hee University Hospital, 23 Kyungheedaero, Dongdaemun-gu, Seoul 130-872, Republic of Korea

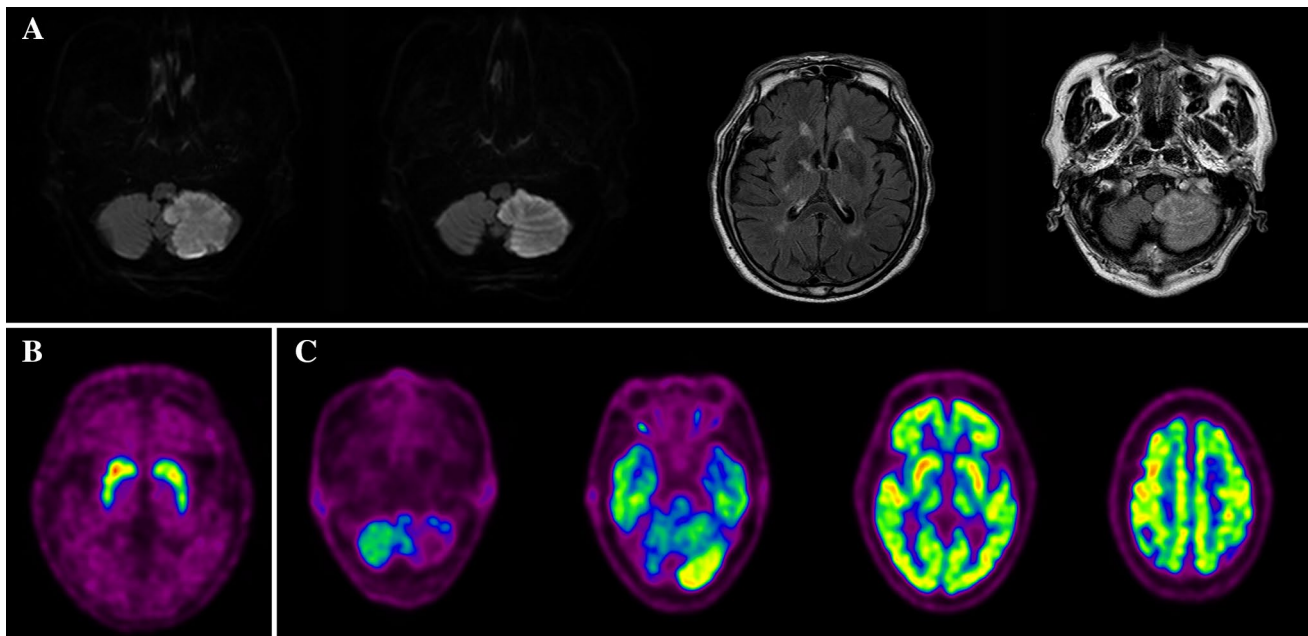


Fig. 1 Brain magnetic resonance imaging of the patient. **a** Diffusion weighted imaging shows acute infarction in the left cerebellum. In the fluid-attenuated inversion recovery images, cerebellar lesion is also shown, whereas the cerebral cortex and basal ganglia, which are related to stereotypy, are intact. **b** ^{18}F -fluorinated *N*-3-fluoropropyl-2-beta-carboxymethoxy-3-beta-(4-iodophenyl) nortropane (^{18}F -FP-

CIT) positron emission tomography (PET) showed decreased uptake of ^{18}F -FP-CIT in both putamen and caudate nuclei. **c** ^{18}F -fluorodeoxyglucose (^{18}F -FDG) PET showed decreased metabolism in the high frontal and anterior temporal cortices, anterior cingulate gyrus, right posterior putamen, left anterior and posterior putamen, and defects in the left cerebellum

Bilateral stereotypy after unilateral cerebellar infarction can be considered as unusual. However, functional studies reported bilateral connections of the cerebellum with other brain regions; unilateral cerebellar lesion could affect bilateral white matter tracts and cerebral regions [4], and bilateral asterixis was reported after unilateral cerebellar infarction [5]. Thus, the bilateral presentation in this patient may be related to intrinsic bilateral connections of the cerebellum.

Parkinsonism was also an unexpected finding. His parkinsonism was asymmetric, but was poorly responsive to levodopa treatment, decreasing the possibility of the patient having Parkinson's disease. Since no structural lesions were found in the substantia nigra and striatum, the abnormal uptake observed during ^{18}F -FP-CIT PET might be the result of subclinical degeneration of the presynaptic area, which might have been present before the cerebellar infarction. The hypometabolism in the putamen could be either a part of post-cerebellar metabolic derangement or a reflection of postsynaptic degeneration. Both presynaptic and postsynaptic mechanisms contributed to his parkinsonism, and may have rendered his parkinsonism levodopa-unresponsive.

Finally, unlike our previous case, this patient had no cognitive impairment. Hence, neither neurodegenerative dementia with stereotypy nor cerebellar cognitive affective syndrome was referable for his condition.

In conclusion, this is another illustrative case study revealing the important role of the cerebellum in stereotypy. Cerebellar stereotypy is a unique clinical syndrome providing a new insight on the pathophysiology of stereotypy.

Funding This research did not receive any specific grant from funding agencies in the public, commercial, or not-for-profit sectors.

Compliance with ethical standards

Conflict of interest The authors declare that they have no competing interest.

Ethical approval Ethical approval is waived for this study, because this is a retrospective report of a case.

Informed consent Informed consent about the use of medical record and video was taken from the patient.

References

1. Lee D, Lee D, Ahn TB (2014) Stereotypy after cerebellar infarction. *J Neurol Sci* 344(1–2):227–228. <https://doi.org/10.1016/j.jns.2014.06.019>
2. Picazio S, Koch G (2015) Is motor inhibition mediated by cerebello-cortical interactions? *Cerebellum (Lond, Engl)* 14(1):47–49. <https://doi.org/10.1007/s12311-014-0609-9>

3. D’Mello AM, Stoodley CJ (2015) Cerebro-cerebellar circuits in autism spectrum disorder. *Front Neurosci* 9:408. <https://doi.org/10.3389/fnins.2015.00408>
4. Olivito G, Dayan M, Battistoni V, Clausi S, Cercignani M, Molinari M, Leggio M, Bozzali M (2017) Bilateral effects of unilateral cerebellar lesions as detected by voxel based morphometry and diffusion imaging. *PLoS One* 12(7):e0180439. <https://doi.org/10.1371/journal.pone.0180439>
5. Kim JS (2001) Asterix after unilateral stroke: lesion location of 30 patients. *Neurology* 56(4):533–536