

# Reversible cerebral vasoconstriction complicated with brain infarction immediately after carotid artery stenting

Eiji Higashi<sup>1</sup> , Takeshi Uwatoko<sup>1</sup>, Taichiro Mizokami<sup>2</sup>, Yusuke Sakaki<sup>1</sup>, Shuji Sakata<sup>2</sup> and Hiroshi Sugimori<sup>1</sup>

## Abstract

Reversible cerebral vasoconstriction is a very rare complication after carotid artery stenting (CAS). It has been reported to occur more than several hours after CAS and to have a good clinical course. A 73-year-old man underwent CAS for a high-grade symptomatic stenosis of his left carotid artery. Immediately after CAS, he had consciousness disturbance and right hemiparesis. We first suspected hyperperfusion syndrome, but antihypertensive therapy exacerbated his symptoms. On repeated postoperative angiography, the middle cerebral artery (MCA) appeared to become progressively narrower. Perfusion computed tomography indicated hypoperfusion in the left MCA territory, so we diagnosed the patient with ischemic symptoms due to hypoperfusion associated with MCA vasoconstriction. Although these findings were temporary, right weakness and cognitive dysfunction lingered and caused severe disability. As vasoconstriction after CAS may result in a poor outcome, it must be promptly distinguished and treated accordingly.

## Keywords

Carotid artery stenosis, CAS, vasoconstriction

Received 7 April 2018; accepted 18 May 2018

## Introduction

Dysregulatory increase in the cerebral blood flow (CBF) with devastating neurological symptoms following carotid artery stenting (CAS) are well known as cerebral hyperperfusion syndrome (HPS). In contrast, the complete opposite etiology of dysregulation of the CBF—hypoperfusion due to vasoconstriction—has been rarely reported, and its mechanism and diagnosis are yet to be defined. We herein report a patient who developed cerebral hypoperfusion immediately after CAS that eventually caused severe disability.

## Case report

A 73-year-old man with a history of untreated diabetes mellitus (HbA1c 14.6%) presented to the emergency department of our hospital with a sudden onset of speech disturbance and weakness in the right extremities. We made a diagnosis of left watershed infarction due to severe stenosis of the left internal carotid artery (ICA). Within two weeks he made a full neurologic recovery, and we planned to perform CAS for the left ICA stenosis four months later. Although carotid endarterectomy might have been a better choice because he had no cardiac risk, the patient strongly desired CAS.

We performed CAS under general anesthesia. Because the plaque was supposed to be vulnerable, we chose flow reversal and filter protection for distal embolic protection (Figure 1(a)).<sup>1</sup> A Carotid Wallstent 10 mm × 24 mm (Boston Scientific, Natick, MA, USA) was deployed (Figure 1(b)). Post-dilation (4.5 mm × 30 mm) angiography showed no sign of in-stent thrombosis (Figure 1(c)) or embolism to the cerebral arteries.

Just after anesthesia wore off, the patient suffered a disturbance of consciousness, and right hemiparesis was suspected. Emergent magnetic resonance imaging (MRI) showed an acute but tiny infarction in the left watershed areas (Figure 2(a)), and a magnetic resonance angiography (MRA) of the carotid and intracranial arteries showed non-significant changes after CAS (Figure 2(b)). The disturbance

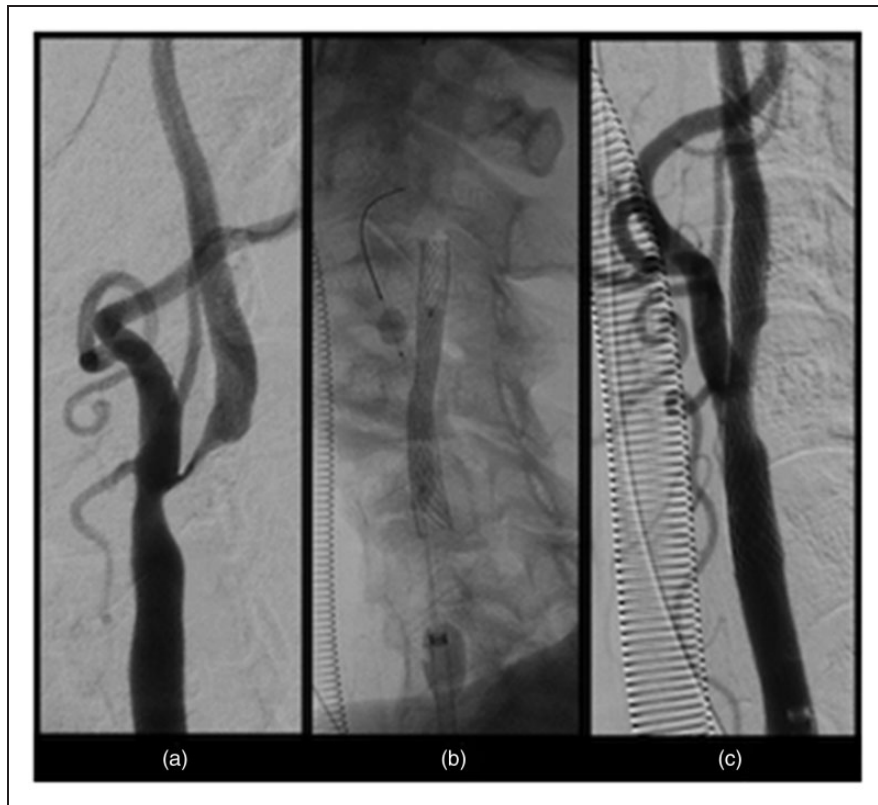<sup>1</sup>Department of Cerebrovascular Medicine, Saga Medical Centre, Saga, Japan

<sup>2</sup>Department of Neurosurgery, Saga Medical Centre Koseikan, Saga, Japan

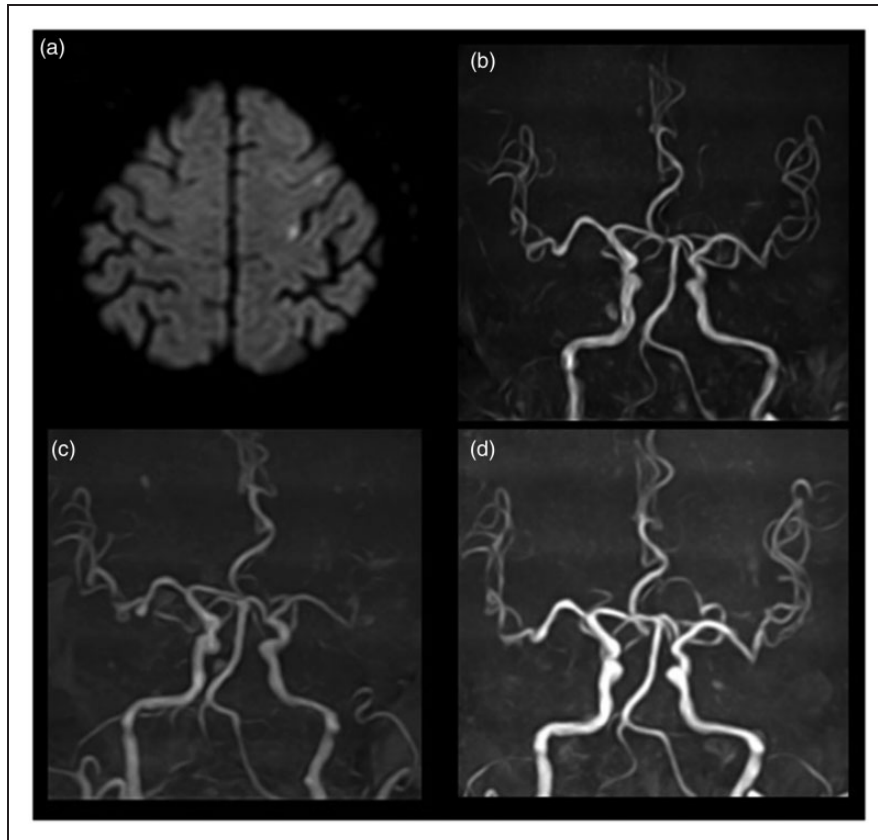
## Corresponding author:

Eiji Higashi, Department of Cerebrovascular Medicine, Saga Medical Centre Koseikan, 400 Nakabaru, Kasemachi, Saga City, Japan.

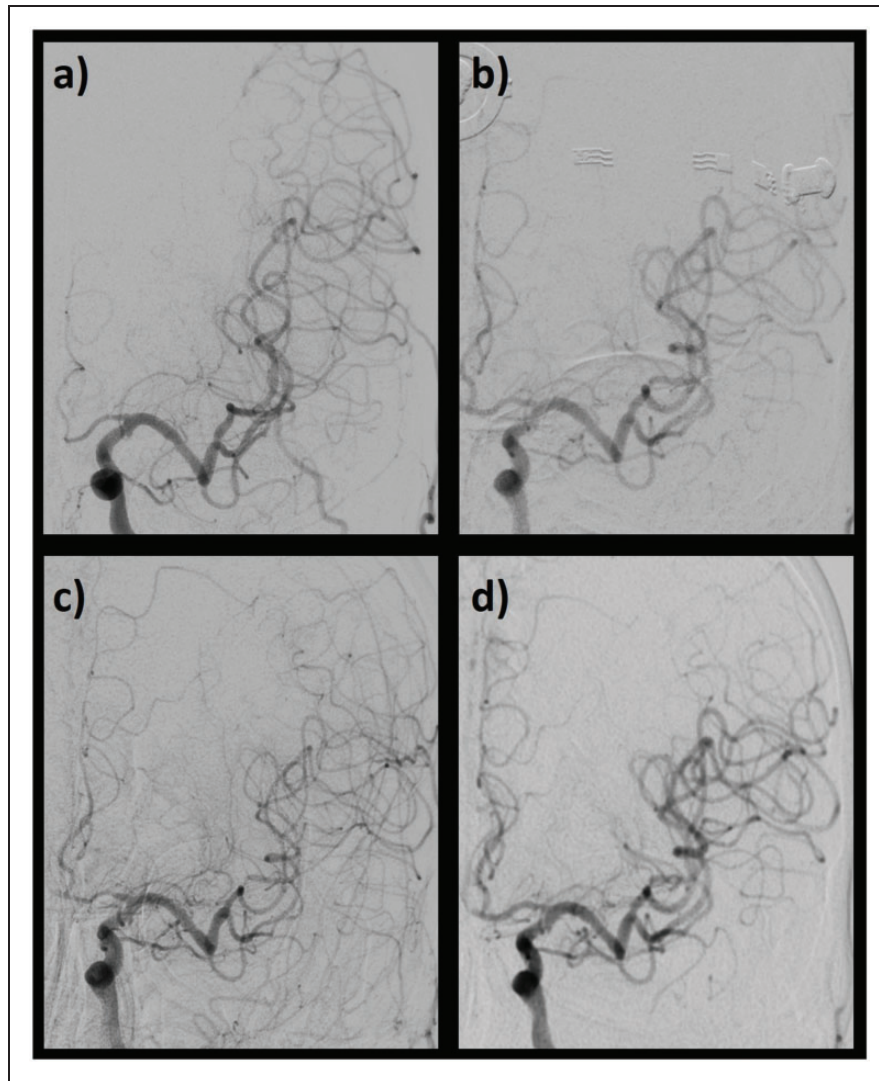
Email: eiji0016788@gmail.com



**Fig. 1.** Preoperative common carotid angiography (CCAG) showed severe stenosis (NASCET85%) of the left ICA (a). We performed CAS with flow reversal and filter protection (b). Postoperative CCAG showed good dilation of his left ICA and no signs of in-stent thrombosis (c).



**Fig. 2.** Diffusion-weighted imaging showed acute small infarction in the left watershed areas (a), and MRA revealed no occlusion of the main artery (b) just after CAS. At 10 h postoperatively, the left distal MCA beyond the M2 segment disappeared (c). The appearance of left MCA was improved on 6th postoperative day (d).



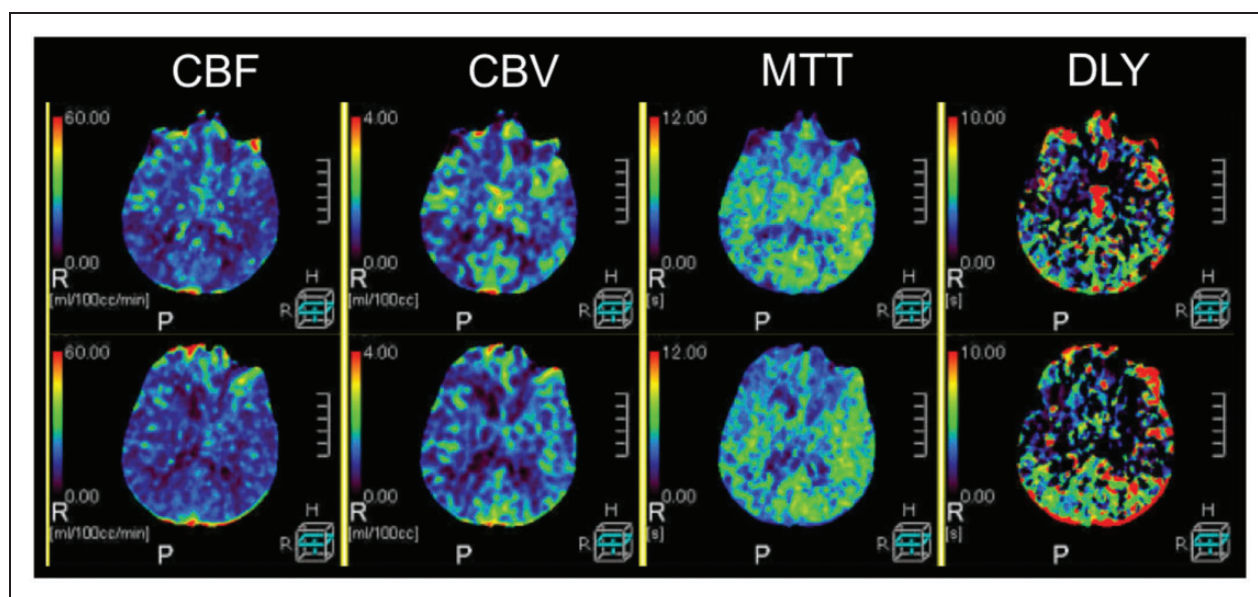
**Fig. 3.** Cerebral angiography showed the change in the transient vasoconstriction of the left MCA. (a) Preoperative status. (b) Immediately after CAS. (c) 10 h postoperatively. (d) 29th postoperative day.

of consciousness worsened at 10 h after CAS. Emergent repeated MRI showed that the number of small infarctions had slightly increased, and the left distal middle cerebral artery (MCA) beyond the M2 segment disappeared on MRA (Figure 2(c)). Emergent cerebral angiography clearly showed the cerebral arteries to the periphery and no signs of embolism to the cerebral arteries or in-stent thrombosis (Figure 3(c)), so we continued antihypertensive treatment considering its positive effects on HPS. Although the systolic blood pressure elevated to over 180 mmHg while waking from anesthesia, we reduced it to under 140 mmHg with nicardipine postoperatively.

While continuing the treatments described above, perfusion computed tomography at 20 h postoperatively confirmed an area with a reduced cerebral blood flow and increased mean transit time in the left frontal and temporal lobes (Figure 4). After carefully reviewing the findings, we found that the left distal MCA on postoperative angiography was narrower

than it had been before surgery, and progression of this narrowing was noted on repeated angiography (Figure 3(a) to (c)). The patient was thereby diagnosed with ischemic symptoms due to hypoperfusion associated with a narrowed MCA.

Antihypertensive treatment was stopped immediately, and antithrombotic treatment was intensified by the addition of intravenous argatroban. Oral lomerizine hydrochloride was also administered, as the cause of the narrowed cerebral arteries was considered to be vasoconstriction. After starting these therapies, the systolic blood pressure elevated to 160 mmHg, the concomitant deviation promptly improved, and spontaneous speech recovered. The appearance of the left MCA on MRA normalized over time until the 6th postoperative day (Figure 2(d)). Angiography on the 29th postoperative day showed complete resolution of the arterial vasoconstriction (Figure 3(d)). With persistent right weakness and cognitive dysfunction, the patient was transferred to a convalescent rehabilitation hospital.



**Fig. 4.** Perfusion CT at 20 h postoperatively showed an area with a reduced cerebral blood flow and increased mean transit time in the left frontal and temporal lobes.

**Table 1.** Summary of the previous cases of vasoconstriction after CAS.

	Age/Sex	Side of surgery	Stenosis (%)	Side of vasoconstriction	Onset from CAS	Anesthesia	Infarction	Perfusion imaging	Outcome
Arai <sup>3</sup>	72/M	R	78	R ACA+ MCA	13 hours	Local	Present	CTP	No deficit
Shiraga <sup>4</sup>	62/M	R	80	Bil. ACA+ MCA+ PCA	1.5 days	Local	Present	SPECT	No deficit
Soltanolkotachi <sup>5</sup>	49/F	L	70–80	L ACA+ MCA+ PCA	14 days	Local	Present	MRP	No deficit
Aghaebrahim <sup>6</sup>	60/M	R	Not available	R ACA+ MCA	1 month	Local	Not available	Not available	No deficit
Watanabe <sup>7</sup>	74/M	R	80	R ACA+ MCA	17 days	Local	Present	Not available	No deficit
Present case	73/M	L	84	L MCA	Immediately	General	Present	CTP	R weakness, higher brain dysfunction

ACA: anterior cerebral artery; Bil.: bilateral; CAS: carotid artery stenting; CTP: computed tomography perfusion; F: female; L: left; M: male; MCA: middle cerebral artery; MRP: magnetic resonance perfusion; PCA: posterior cerebral artery; R, right; SPECT: single photon emission computed tomography.

## Discussion

Perioperative ischemic strokes are the most common adverse events after CAS and can result from thromboembolism due to plaque disruption by the metal mesh of carotid stents at the site of intervention.<sup>2</sup> An extremely rare cause of hypoperfusion is cerebral vasoconstriction, the frequency of which is unknown.

Table 1 summarizes the reported cases of cerebral vasoconstriction following CAS, all of which had hypoperfusion and the symptoms were contralateral but corresponding with the treated side.<sup>3–7</sup>

Although the mechanism underlying how CAS triggers vasoconstriction is not clear—similar conditions

have been known as rare complication after carotid endarterectomy<sup>8</sup>—it has been considered to be a subtype of reversible cerebral vasoconstriction syndrome (RCVS).<sup>3–7</sup> RCVS is typically characterized by acute severe headache, but RCVS without headache has been reported in several literature and the absence of headache should not exclude the diagnosis of RCVS in patients with cerebral vasoconstriction.<sup>9</sup>

Chen et al. hypothesized that the central element in the pathogenesis of RCVS is dysregulation of the cerebral vascular tone, which may result from endothelial dysfunction.<sup>10</sup> Chronic cerebral hypoperfusion due to severe ICA stenosis may have led to dysfunctional regulation of cerebrovascular tone in the present case.

Additionally, acute increases in the CBF and/or extracranial arterial procedures may induce the production of catecholamines, vasoconstrictive prostaglandins and proinflammatory cytokines, thereby accentuating the vasoconstrictive response along with sympathetic overactivity.

Most previously reported patients with vasoconstriction after CAS were found to have ischemic lesions on MRI, but their neurologic symptoms were transient, and only the present case developed severe lasting symptoms in the earliest stage (Table 1). Among previous cases, three reports mentioned protection devices and all of them were treated with only distal filter protection, whereas the present case was treated with flow reversal protection.<sup>3,4,7</sup> During flow reversal there was potential for exacerbating the endothelial dysfunction due to its ischemia. Moreover, the present case was treated under general anesthesia to avoid the intolerance to ischemia caused by flow reversal, whereas all previous cases were treated under local anesthesia. The fluctuations of the blood pressure due to general anesthesia could accentuate the vasoconstrictive response. In diabetic patients, the production of vasodilator substances, including nitric oxide and endothelium-derived hyperpolarizing factor, by the endothelium is diminished, and proliferation of vascular smooth muscle cells is induced.<sup>11</sup> Together, uncontrolled diabetes mellitus, general anesthesia, flow reversal, and acute increases in the CBF due to CAS, might have induced significant changes in the cerebrovascular tone, thereby leading to such an early and serious complication in this case. A combination of these factors would need a warning for cerebral arterial vasoconstriction.

Vasoconstriction is a very rare complication following CAS and can result in a poor outcome. As the mechanism is the complete opposite of that underlying HPS, it must be distinguished and treated as early as possible.

#### Declaration of conflicting interests

The authors declared no potential conflicts of interest with respect to the research, authorship, and/or publication of this article.

#### Funding

The authors received no financial support for the research, authorship, and/or publication of this article.

#### ORCID iD

Eiji Higashi  <http://orcid.org/0000-0002-3461-9149>

#### References

1. Sakamoto S, Kiura Y, Okazaki T, et al. Carotid artery stenting for vulnerable plaques on MR angiography and ultrasonography: utility of dual protection and blood aspiration method. *J Neurointerv Surg* 2016; 8: 1011–1015.
2. Wu TY, Anderson NE and Barber PA. Neurological complications of carotid revascularization. *J Neurol Neurosurg Psychiatry* 2012; 83: 543–550.
3. Arai M, Kuwayama N, Koide K, et al. Transient right hemisphere hypoperfusion following right carotid artery stenting: a case report (in Japanese). *J Neuroendovasc Ther* 2013; 7: 119–126.
4. Shiraga S, Akai T, Takata H, et al. Possible cerebral infarction due to multiple segmental cerebral vasospasms after carotid artery stenting: a case report (in Japanese). *No Shinkei Geka* 2015; 43: 1081–1089.
5. Soltanolkotabi M, Ansari S, Patel B, et al. Reversible cerebral vasoconstriction syndrome following carotid artery stenting. *J Neurointerv Surg* 2012; 4: A49–A50.
6. Aghaebrahim A, Jadhav AP, Saeed Y, et al. Reversible cerebral vasoconstriction syndrome following carotid stenting. *Neurology* 2014; 83: 570–571.
7. Watanabe Y, Takechi A, Kajiura Y, et al. Reversible cerebral vasoconstriction syndrome following carotid artery stenting: a case report (in Japanese). *Jpn J Stroke* 2017; 39: 299–303.
8. Causey MW, Amans MR, Han S, et al. Reversible cerebral vasoconstriction syndrome is a rare cause of stroke after carotid endarterectomy. *J Vasc Surg* 2016; 64: 1847–1850.
9. Wolff V and Ducros A. Reversible cerebral vasoconstriction syndrome without typical thunderclap headache. *Headache* 2016; 56: 674–678.
10. Chen SP, Fuh JL and Wang SJ. Reversible cerebral vasoconstriction syndrome: current and future perspectives. *Expert Rev Neurother* 2011; 11: 1265–1276.
11. Nava P, Collados MT, Massó F, et al. Endothelin mediation of insulin and glucose-induced changes in vascular contractility. *Hypertension* 1997; 30: 825–829.