



Citation	Gijs J, Lambert J, Meyfroidt G, (2018), Cerebral microbleeds and intracerebral hemorrhage associated with veno-venous extracorporeal membrane oxygenation Acta Neurol Belg. 2018 Jul 6 (epub ahead of print)
Archived version	Author manuscript: the content is identical to the content of the published paper, but without the final typesetting by the publisher
Published version	http://dx.doi.org/10.10.1007/s13760-018-0975-z
Journal homepage	https://link.springer.com/journal/13760
Author contact	greet.vandenbergh@kuleuven.be + 32 (0)16 34 40 21
	url in Lirias https://lirias.kuleuven.be/handle/123456789/xxxxxx

(article begins on next page)



Cerebral microbleeds and intracerebral hemorrhage associated with veno-venous extracorporeal membrane oxygenation

Jeroen Gijs¹ · Julie Lambert² · Geert Meyfroidt^{3,4} · Jelle Demeestere^{1,5,6}

✉ Jelle Demeestere jelle.demeestere@uzleuven.be

¹ Department of Neurology, University Hospitals Leuven, Leuven, Belgium

² Department of Radiology, University Hospitals Leuven, Leuven, Belgium

³ Department of Intensive Care Medicine, University Hospitals Leuven, Leuven, Belgium

⁴ Laboratory of Intensive Care Medicine, Department of Cellular and Molecular Medicine, KU Leuven, University of Leuven, Leuven, Belgium

⁵ Department of Neurosciences, Experimental Neurology, KU Leuven, University of Leuven, Leuven, Belgium

⁶ Laboratory of Neurobiology, VIB, Center for Brain and Disease Research, Leuven, Belgium

Keywords Cerebral microbleeds · Cerebral microhemorrhages · Extracorporeal membrane oxygenation · Epilepsy · Hemorrhage · Cerebral

A 30-year-old woman, 26-week pregnant, was admitted to the intensive care unit (ICU) with an influenza-A pneumonia and severe acute respiratory distress syndrome (ARDS). She deteriorated while on protective lung ventilation, steroids and intermittent proning. Day 4, an emergency caesarian section was performed, followed by initiation of venovenous extracorporeal membrane oxygenation (ECMO). ECMO was continued for 12 days. She was extubated 2 days later. 1 week after extubation she had a tonic-clonic epileptic seizure, treated with diazepam and levetiracetam. On brain computed tomography (CT), a hyperdense lesion with surrounding edema in the right parietal lobe was seen (Fig. 1). Magnetic resonance imaging (MRI) showed multiple microbleeds (MB) at the cortico-subcortical junction and deep white matter, and one larger hemorrhage in the right parietal cortex, which caused the seizure (Fig. 2). The patient was discharged home after 1 month and remained seizure free under levetiracetam 500 mg bd. The baby is still in the neonatal ICU.

MB are small (< 10 mm), round and hypo-intense lesions readily visible on gradient-recall echo or susceptibility-weighted MRI which are often invisible on CT [1]. Histopathologically, they correspond to areas of hemosiderin deposition as a result of prior self-limiting microhemorrhage usually secondary to small vessel disease [1]. However, diffuse MB at the cortico-subcortical junction and the corpus callosum have been described in ARDS, ECMO, anoxic brain injury and high altitude cerebral edema [2–5], often in patients without small vessel disease. The pattern of MB seen in ARDS patients on

ECMO is not typically seen in conditions associated with MB likely caused by sporadic small vessel disease or thromboembolism, such as cardiac valve surgery [6]. The pathophysiology is unclear, but (a combination of) hypoxemia, rapid post-hypoxic reoxygenation, increased venous pressure, thromboembolism and systemic inflammation have been proposed [2–4, 7, 8]. The corpus callosum and subcortical U-fibers are relatively resistant to acute and chronic ischemia due to a rich vascular supply and vascular anastomoses [9]. In animal models, rapid reoxygenation after anoxic injury has shown to induce MB with a predilection for small penetrating blood vessels without smooth muscle layer, similar to the vasculature of the corpus callosum [7]. The selective vulnerability of this specific vascular region remains unexplained. Larger brain hemorrhages causing focal symptoms may occur in up to 15% of ECMO-treated patients [3]. Although good outcomes are reported in patients with isolated ECMO-associated MB, possible long-term effects on cognition are not known [4].

Acknowledgements The authors would like to acknowledge the patient, who consented to the publication of this manuscript. We would like to thank the medical and nursing staff of the departments of Intensive Care Medicine, Pneumology, and Neurology for their care to the patient. Prof Meyfroidt is supported by the Research Foundation, Flanders (FWO) as senior clinical investigator (1843118N). Dr Demeestere is supported by a clinical research and educational board (KOOR) grant from Leuven University Hospitals.

Funding No funding was received for this study.

Compliance with ethical standards

Conflict of interest All authors declare that they have no conflict of interest.

Informed consent Patient informed consent was obtained

Ethical approval Ethical approval was waived given the anonymous nature of the presented patient data.

References

1. Yates PA, Villemagne VL, Ellis KA, Desmond PM, Masters CL, Rowe CC (2014) Cerebral microbleeds: a review of clinical, genetic, and neuroimaging associations. *Front Neurol* 4:205
2. Liebeskind DS, Sanossian N, Sapo ML, Saver JL (2013) Cerebral microbleeds after use of extracorporeal membrane oxygenation in children. *J Neuroimaging* 23(1):75–78
3. Riech S, Kallenberg K, Moerer O, Hellen P, Bärtsch P, Quintel M et al (2015) The pattern of brain microhemorrhages after severe lung failure resembles the one seen in high-altitude cerebral edema. *Crit Care Med* 43(9):e386–e389
4. Luyt CE, Bréchet N, Demondion P, Jovanovic T, Hékimian G, Lebreton G et al (2016) Brain injury during venovenous extracorporeal membrane oxygenation. *Intensive Care Med* 42(5):897–907
5. Park D-W, Guri-si KR (2017) Microhemorrhages in the corpus callosum as the distinctive anoxic brain injury. *ECR, Vienna*
6. Jeon SB, Lee JW, Kim SJ, Chung CH, Kwon SU, Choi CG et al (2010) New cerebral lesions on T2*-weighted gradient-echo imaging after cardiac valve surgery. *Cerebrovasc Dis* 30(2):194–199
7. Hoff A, Kunze R, Helluy X, Milford D, Heiland S, Bendzus M et al (2016) High-field MRI reveals a drastic increase of hypoxia-induced microhemorrhages upon tissue reoxygenation in the mouse brain with strong predominance in the olfactory bulb. *PLoS One* 11(2):e0148441
8. Sumbria RK, Grigoryan MM, Vasilevko V, Krasieva TB, Scadeng M, Dvornikova AK et al (2016) A murine model of inflammation-induced cerebral microbleeds. *J Neuroinflammation* 13(1):218
9. Chrysikopoulos H, Andreou J, Roussakis A, Pappas J (1997) Infarction of the corpus callosum: computed tomography and magnetic resonance imaging. *Eur J Radiol* 25(1):2–8

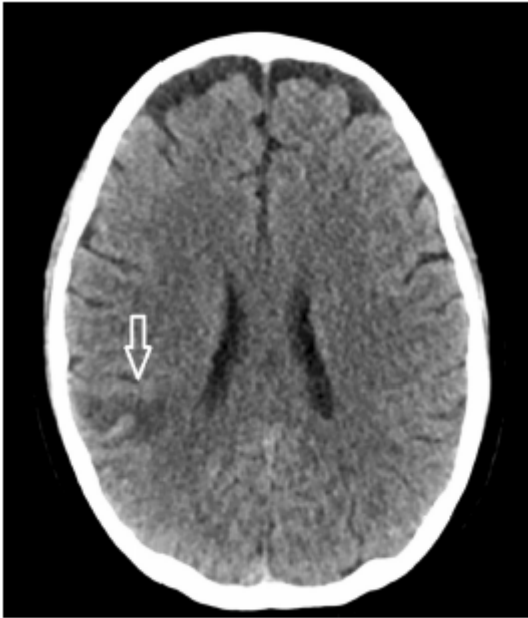

Fig. 1 Computed tomography image, axial slice through the lateral ventricles. The arrow shows a small, hyperdense hemorrhage, juxtacortical in the right parietal lobe. Perilesional edema is visible as a surrounding hypodense rim

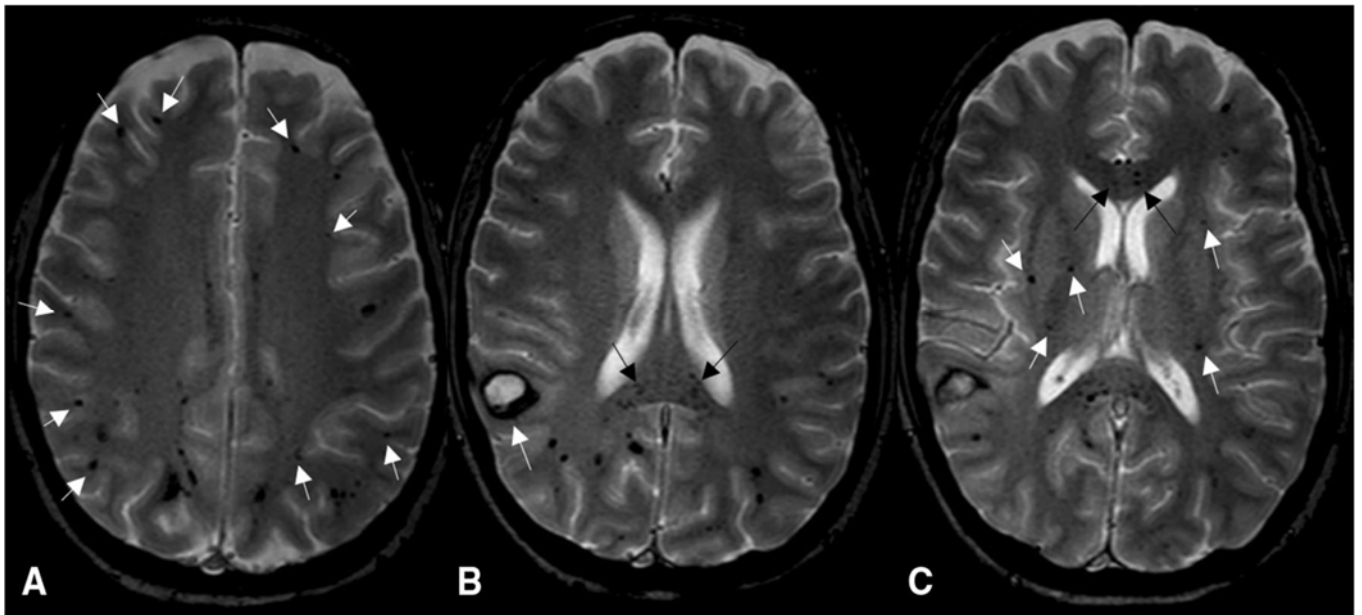


Fig. 2 Gradient echo magnetic resonance images, left to right correspond to axial slices from cranial to caudal through the brain. Microbleeds are shown as multiple hypo-intense foci of hemosiderin deposition bilaterally. These are most abundant in the juxtacortical white matter (white arrows in **a**) and in the corpus callosum (black arrows in **b** and **c**). There are also several lesions in the deep white matter (white arrows in **c**). A larger, symptomatic hemorrhage is also visible