

Acquired Cerebral Dyschromatopsia

Glenn J. Green, MD, Simmons Lessell, MD

• Color blindness developed in five patients apparently because of lesions in the posterior portions of both cerebral hemispheres. Three of them also had symptoms of prosopagnosia. The lesions were neoplastic in two and vascular in three of the patients. It would appear that bilateral, inferior, occipital lobe lesions may be responsible both for acquired cerebral dyschromatopsia and prosopagnosia. Evidence from experimental investigations in primates suggests that the areas of the cerebral hemispheres analogous to those involved in these patients, may be specialized for the processing of colored stimuli.

(*Arch Ophthalmol* 95:121-128, 1977)

Since the first case of acquired dyschromatopsia of cerebral origin was described in 1899,¹ there have been several additional cases reported in the neurological literature. To our knowledge, only one case has been reported in the ophthalmological literature.² In a recent review, Meadows³ was able to find only 13 adequately described cases. He inferred from these, and from one patient whom he personally evaluated, that bilateral occipital lesions are responsible for this disorder. We have recently examined five patients with acquired

dyschromatopsia apparently due to bilateral cerebral lesions. The purpose of this report is to present further clinical evidence that supports Meadows' conclusion and to review the subject of cerebral disorders of color vision.

REPORT OF CASES

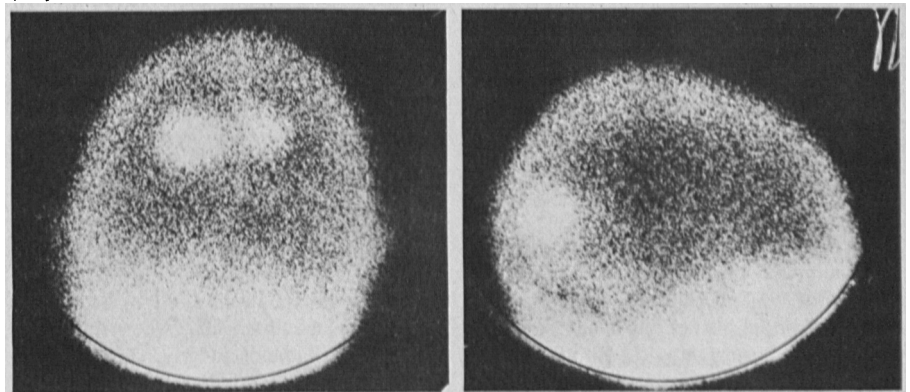
CASE 1.—A 64-year-old, married, retired, male mechanical engineer initially came to the hospital in December 1974 because of left-sided weakness of four weeks' duration. He had a left hemiparesis, but the rest of the findings of physical and neurological examination were normal. Neuro-ophthalmic examination revealed that his visual acuity was 15/15 in both eyes, and he had normal color vision when tested with the Ishihara plates. Pupillary reactions, eye movements, and optokinetic responses were normal. There was no lateral devia-

tion of the eyes on forced closure of the lids. His fundi were normal, and his visual fields were full to the 1-mm and 2-mm white objects on the 2-meter tangent screen.

Chest x-ray films showed a 3-cm density in the right upper lobe. A technetium 99m brain scan demonstrated discrete round areas of uptake, one in the parietal region of each hemisphere. A presumptive diagnosis of metastatic carcinoma of the lung was made, and the patient was treated with 3,000 rads of whole-brain irradiation. His left hemiparesis had improved by the time of his discharge in January 1975.

In May 1975, he returned because of increasing shortness of breath. The chest x-ray film now showed a right pleural effusion. Bronchoscopy was performed after the findings of thoracentesis did not lead to a diagnosis. It disclosed poorly differentiated squamous-cell carcinoma. A technetium 99m brain scan showed two

Fig 1.—Radionuclide brain scan in case 1. Left, Anteroposterior projection; Right, Lateral projection. Note areas of isotope uptake in occipital lobes.



Accepted for publication May 10, 1976.
From the Departments of Ophthalmology, Neurology, and Anatomy, Boston University School of Medicine, Boston.
Reprint requests to 720 Harrison Ave, Boston, MA 02118 (Dr Lessell).

areas of increased uptake in the left posterior region adjacent to the midline. The patient received 4,000 rads of therapy to the mediastinum and intrapleural mechlorethamine hydrochloride, which resulted in relief of his symptoms. He was discharged from the hospital in July 1975.

In September 1975 the patient began to have difficulty reading. The print seemed clear to him but for reasons he could not explain, he could not read. He also complained of difficulty in keeping his writing on a straight line across the page. Two weeks later, the patient began to see smooth, wavy, black and orange lines that did not disappear when he closed his eyes and that were present almost constantly. Ten days later, the patient awoke from a nap and found that his whole visual field was filled with blue, yellow, red, and green jagged lines, and other ill-defined shapes. This was not associated with any headache, alteration in consciousness, nausea, vomiting, involuntary movement, or weakness. The episode lasted between 10 and 15 minutes and ended suddenly without leaving any residual visual or other symptoms. This episode occasioned readmission to the hospital. His only other visual complaint was that for the preceding month everything appeared "dim" and he said that "things don't look as bright as they used to."

Findings of his general physical examination were remarkable for tenderness and decreased range of motion of his left hip. He was oriented as to time, place, and person, had excellent memory for recent and remote events, and was not aphasic. He had no left-right disorientation or constructional apraxia. He had a left hemiparesis, but no sensory abnormalities were found.

A neuro-ophthalmic examination in October revealed that his visual acuity was 20/20 in both eyes. On testing of his color vision with the Ishihara plates, he now could read only the "malingering" plate with each eye. He did not report the confusion numbers. He had no difficulty with color-naming when presented brightly colored objects, and he also had no difficulty answering such questions as "what color is a banana?" Pupillary reactions, eye movements, opticokinetic responses, and findings of exophthalmometry and slit-lamp examination were normal. There was no lateral deviation of his eyes on forced closure of the eyelids. His fundi were normal. He had a total, absolute, right homonymous hemianopsia. The patient could not read words (although he could read individual letters and numerals), but he could write normally. He did not appear to be illiterate (he could give the correct

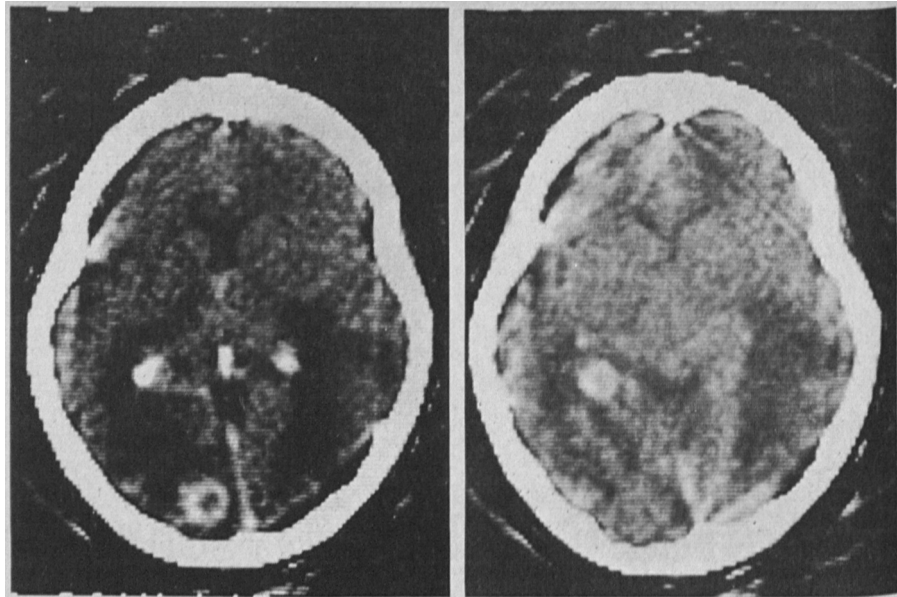


Fig 2.—Computerized axial tomographic scan in case 2.

spelling of words that were said to him and he could identify words if they were spelled to him). Face recognition was normal and there was no evidence of visual object agnosia. A technetium 99m brain scan at that time showed bilateral discrete round areas of increased uptake in the occipital lobes (Fig 1).

This man presumed to have metastatic brain disease was examined early in the course of his illness (when he had signs indicative of involvement only in the right hemisphere) and had normal color vision. Several months later, after he began to experience unformed, colored, visual hallucinations, he was color-blind. While he had normal visual acuity, he had a right homonymous hemianopsia and alexia without agraphia. There was good evidence by brain scan that he had lesions in both occipital lobes.

CASE 2.—A 43-year-old, unmarried, female insurance agency manager was transferred from another hospital on Nov 20, 1975, for evaluation of headaches and loss of vision, presumably due to metastatic carcinoma of the lung.

The patient's past medical, ocular, and neurological histories were unremarkable. She had smoked three packs of cigarettes a day for approximately ten years. One month prior to admission, she developed constant, moderately severe, nonthrobbing, bifrontal headaches.

There were no visual symptoms until two weeks before admission, when she found that she could not judge distances while driving her automobile. She could clearly

see the cars in front of her, but could not judge how far away she was from them. At that time, she also began to have difficulty reading, but had no difficulty writing. She also seemed to mislocalize objects in space. For example, when she reached for food on her plate it was not where she thought it was. Ten days before admission, the patient suddenly began to see flashing lights in the center of her visual field. The lights were not colored and did not form a pattern. The episode lasted two hours, stopping suddenly and leaving no residual.

The patient's relatives reported that around the same time she began to have difficulty recognizing them by sight when they visited her, although she would instantly recognize them when they spoke. A chest roentgenogram made at another hospital showed a left perihilar mass, and an EEG showed a right-sided abnormality. A computerized tomographic (CT) scan of the brain showed multiple discrete lesions, and she was transferred.

The findings of general physical examination were unremarkable. Her neurological examination showed that she was oriented as to time, place, and person. Memory for remote and recent events was intact, and she had no aphasia, apraxia, or right-left disorientation. Findings of the motor and sensory examinations were unremarkable.

A neuro-ophthalmological examination on the day of admission showed that her visual acuity was 20/25 in both eyes. When tested with the Ishihara test plates, the patient could read only the "malingering" plate and missed all of the other plates. She did not report the confusion numerals. The patient could correctly name the colors of

brightly colored objects that were shown to her, and she could correctly answer such questions as "what color is a banana?"

Her pupillary responses and eye movements were normal except that she had poor optokinetic responses in all directions. On forced closure of the eyelids the eyes deviated to her right. Slit-lamp examination and fundus examination were normal. She had bilateral, homonymous hemianopias which spared fixation and which was more dense on the right. The patient was alexic (although she could read individual letters and numerals) but was not agraphic. She had no object agnosia. Although the patient could correctly identify photographs of such famous people as President Ford and Katherine Hepburn, she could not recognize her sister who was brought silently to her for identification. A CT scan showed a discrete area of uptake in the lateral wall of the left lateral ventricle and another round area of increased uptake in the left occipital lobe, with distortion and displacement of the right occipital lobe (Fig 2).

In this woman with presumed metastatic disease of the brain, symptoms of impaired spatial orientation developed, followed in a few days by unformed, noncolored visual hallucinations and prosopagnosia. Despite good visual acuity, she was color-blind. She had a bilateral homonymous hemianopia that spared fixation, and alexia without agraphia. The CT scan demonstrated a left occipital lobe lesion and showed distortion and

displacement of the right occipital lobe.

CASE 3.—A 60-year-old married man was evaluated as an ambulatory patient in October 1975 because of loss of vision and difficulty in recognizing faces.

He had a history of myocardial infarction and hypertension, but his past ocular and neurological histories were negative prior to December 1974. At that time, he was admitted to another hospital because of severe, continual, throbbing pain above his right eye, which radiated to his right occipital region. Examination there showed that he had a left hemiparesis, but his ophthalmological examination was reported as normal. Lumbar puncture, skull x-rays, brain scan, and carotid arteriogram were reported as normal. An EEG showed slow-wave activity from the right temporo-occipital region and a "suggestion of slow-wave activity" in the left posterior temporal region. The patient was discharged with a diagnosis of "cerebrovascular accident."

During the next few months, the patient began to notice blurring in his left visual field and was examined in May 1975. His visual acuity then was 20/20 in both eyes, and his color vision was normal as determined by testing with the Ishihara plates. He had a dense, left homonymous hemianopia. The rest of the examination results were normal.

The patient returned in October 1975 because of loss of vision and difficulty reading and in recognizing faces. A neuro-ophthalmological examination then showed a visual acuity of 15/40 OD and 15/20 OS. His color vision was abnormal in both eyes (he missed five of ten plates in the Ishihara series and the ones that were identified correctly were identified with great difficulty). He did not report the confusion numerals. He could correctly name the colors of brightly colored objects that were presented to him.

Pupillary reactions and eye movements were normal except that optokinetic responses were reduced when the drum was rotated horizontally to either side.

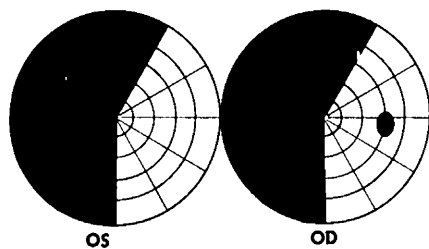
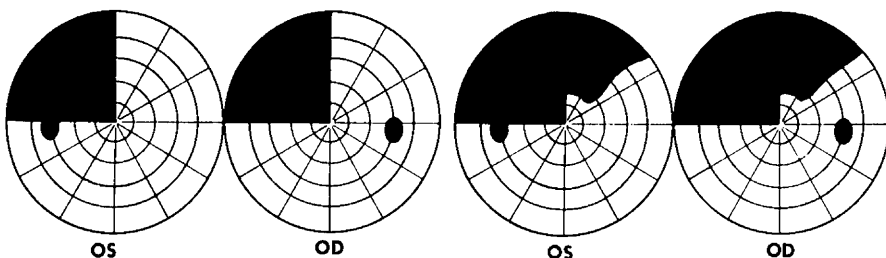


Fig 3.—Visual field in case 3.

Fig 4.—Visual fields in case 4. Left, Initial field test (color vision normal); Right, field test after dyschromatopsia developed.



There was no lateral deviation of the eyes on forced closure of the eyelids. The results of slit-lamp and fundus examinations were normal. He had a complete left homonymous hemianopia and a partial, right superior, homonymous quadrantanopia (Fig 3). Face recognition was severely impaired. He could not even recognize by sight the face of the person who had just driven with him for over an hour to come for the examination.

The patient was admitted to the hospital, where findings of his general physical examination were unremarkable. His neurological examination showed a normal mental status and no evidence of aphasia, alexia, or agraphia. Naming, calculations, dressing, and right-left orientation were normal. He had no object agnosia. Results of sensory and reflex examinations were normal but he had slight weakness of the left arm. The patient was unable to recognize pictures of President Ford, Henry Kissinger, Martin Luther King, Jackie Kennedy, and Bill Russell. An EEG was normal, but a lumbar puncture produced cerebrospinal liquid containing protein, 166 mg/100 ml. A brain scan and skull x-ray films were normal. Angiography showed complete occlusion of the parieto-occipital branch of the right posterior cerebral artery.

A left homonymous hemianopia developed in this man with occlusive cerebrovascular disease, but he retained good visual acuity and color vision. Subsequently, after a second stroke involving the left hemisphere (which produced a partial right superior homonymous hemianopia), prosopagnosia and impaired color vision developed. His visual acuity remained excellent.

CASE 4.—A 64-year-old, widowed, male cook was admitted to the hospital for the first time in February 1971 because of loss of memory, confusion, and weakness of his left side for 36 hours.

He was known to have had diabetes for five years and was taking oral medication. Two years before admission, he had suffered a myocardial infarction and subsequently had angina pectoris, for which he took nitroglycerin. Ten years previously he had the Landry-Guillain-Barré-Strohl syndrome. Few details of that illness are available, but he was alleged to have had no residua. His past ocular history was unremarkable.

One day prior to admission he was visited by relatives, who found him confused, disoriented, and weak on his left side. He was taken to another hospital,

where he was examined and sent home after equivocal neurological abnormalities were found. When his relatives visited him on the day of admission, they found him on the floor, where he apparently had urinated, soiling his clothes. They thought he was disoriented and had impairment of his memory. On admission to the hospital, the patient complained that the left side of his body was numb and that he had tingling in the lower part of his left leg.

Except for an enlarged prostate gland and a bruit over the right carotid artery, the findings of his general physical examination were unremarkable. He was oriented as to time, place, and person, but his memory for recent events was poor. There was no evidence of aphasia, apraxia, alexia, or agraphia, and he recognized faces and colors well. He did calculations accurately, and had no difficulty in abstract thinking. The admission neurological examination also showed a left hemisensory defect and left hemiparesis, and a left superior quadrantanopia by confrontation. A brain scan done shortly after admission was normal as were skull x-ray films and an examination of his cerebrospinal fluid.

A neuro-ophthalmological examination performed for the first time on Oct 8 showed that his best correctable visual acuity was 20/60 OD and 20/20 OS. When he read the Snellen chart, he ignored the numbers on the left hand side of each line. On color vision testing with Ishihara plates, the only errors that were made were that he occasionally missed the left hand numeral of some of the binary numbers in the series. He had a left superior quadrantanopia that was out to hand movements (Fig 4, left). Posterior subcapsular lens opacities, worse in the right eye, seemed to explain his reduced visual acuity. Pupillary responses and fundi were normal. Ocular motility was normal, including optokinetic nystagmus and deviation of the eyes on forced closure of the lids.

The day following that examination, the patient suddenly became confused and developed a right hemiparesis. Lumbar puncture was repeated, and it showed xanthochromic CSF, with a protein content of 179 mg/100 ml. A subsequent brain scan showed increased concentrations of isotope in the left temporal region and the right occipital region. The patient remained in the hospital, receiving physiotherapy, but prior to transfer to a long-term nursing facility, a repeat neuro-ophthalmological examination was requested. This was performed on April 26, 1971.

The main reason why consultation was requested was that his family thought that he was unable to recognize the faces of people familiar to him. He would, however,

identify them correctly when they spoke. His visual acuity was found to be unchanged from before, but his visual fields now had bilateral homonymous defects involving the upper quadrants on both sides (Fig 4, right). He was now completely color-blind, as tested with the Ishihara test plates. He could read the "malingering" numerals but got all of the other numerals wrong. He did not read any of the confusion numerals. He had no difficulty with naming the colors of large, brightly colored objects. Findings of the rest of the examination were entirely normal, including ocular motility and other visual psychological functions.

Despite the family's impression, the patient was able to recognize familiar faces and to match photographs of unfamiliar faces. He was not aphasic, alexic, or agraphic. He performed calculations normally and had no left-right disorientation.

In this man, a left superior homonymous quadrantanopia developed from a stroke, but he retained good visual acuity and normal color vision. After a second stroke, difficulty in recognizing faces developed, and he was found to have a partial, right, superior homonymous quadrantanopia, in addition to the previous field defect. Despite the fact that his visual acuity remained good, he had become color-blind. A radionuclide brain scan showed a left temporal and right occipital lesion.

CASE 5.—A 37-year-old machine worker and housewife was referred in January 1973, complaining that her eyesight had failed since a surgical operation in August 1972. She had a long history of migraine headaches, as did her father, but she had never had any visual disturbances in association with her headaches. Her general health was good and her past neurological and ocular histories were said to be negative. In August 1972, she underwent a hysterectomy under general anesthesia. On awakening from anesthesia she noted that her side vision was severely impaired and she had prolonged nausea and vomiting. Findings of the neurological examination were normal.

A neuro-ophthalmic examination showed that her visual acuity was 16/15 OD and 16/20+ OS. She missed many of the Ishihara plates with each eye when her color vision was tested. She did not report the confusion numbers. Visual fields showed a very dense, bilateral, homonymous hemianopia that spared fixation. It was total on the left but involved only an inferior wedge

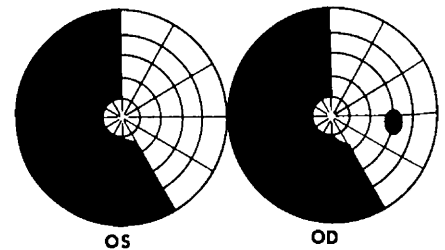


Fig 5.—Visual field in case 5.

on the right (Fig 5). Findings of the rest of her eye examination were entirely normal, and she had no deviation of her eyes on forced closure of the lids and normal optokinetic responses.

Her memory for recent and remote events was normal, and she was not aphasic. She had no color-naming defect, alexia, right-left disorientation, or agnosia. Face recognition was not impaired. Skull x-ray films and a brain scan were normal. Other information was not available, and the patient has not been seen since the original examination.

This woman became aware of a defect in her visual fields when she awoke from general anesthesia after an operation. She probably suffered infarction of both occipital lobes as a result of some intraoperative hemodynamic episode. Although there is no previous record of her color vision, she did show moderate evidence of color vision impairment as tested by the Ishihara plates. However, there was no evidence of color-naming defect or any agnosia, and her impaired color vision occurred despite retention of excellent visual acuity.

COMMENT

Acquired disorders of color vision due to lesions of the central nervous system may be divided into two groups—those in which the color sense is normal but in which the naming or recognition of colors is impaired, and those in which there is inability to see colors (dyschromatopsia or achromatopsia).

Aphasia

The former group includes patients with certain aphasias. If, for example, a patient has Wernicke aphasia, he will fail to name the color of an object that he is shown because he does not comprehend the task and because he is deficient in language. Patients with

anomic aphasia may also fail to name colors, but they can choose the correct name when they are given several choices. In the case of these aphasias, the defective performance is not limited to tasks involving color, but extends to all tasks of naming.

However, there are also patients with a specific inability to name colors who have no other disturbance of naming. Most of the patients with a specific color-naming problem have also had the syndrome of alexia without agraphia¹⁰ (pure word blindness). These patients are not aphasic in the ordinary sense, but they have "an inability to match seen colors to their spoken name."¹¹ Nevertheless, their color sense is intact, since they can read the numerals on the pseudoisochromatic plates and can match colors (eg, divide chips of various colors into separate piles according to color). They can correctly place the shades of one color in order, correctly name the colors that are associated with particular objects (such as a banana), and can indicate when an object has been colored inappropriately (such as a blue fire engine).

Pathological examination of such cases has shown lesions in the left occipital lobe and the splenium of the corpus callosum.^{10,11} Disconnection of visual inputs to the left hemisphere is thought to be responsible for the alexia and the defect in color-naming.¹² It should be noted that this constellation of lesions does not necessarily produce a disorder of color naming, since some patients with the syndrome of alexia without agraphia name colors normally.^{10,11}

There has also been a case report of a nonalexia patient who had a disturbance of color-naming.¹² Extensive testing of that patient showed that "a persistent deficit occurred only on those tasks requiring the patient to respond to a single-color test stimulus for which no simultaneous comparison with other colors was available to him." That patient also had a defect in memory and difficulty in giving the proper names of people, despite the fact that it could be shown that he recognized them. Autopsy disclosed lesions in the left lateral geniculate nucleus, lateral dorsal nucleus of the

thalamus, pulvinar, hippocampal and lingual gyri.

Visual Agnosia

Another category of dysfunction that must be considered in the differential diagnosis of impaired color vision is visual agnosia. Visual agnosia may be defined as a disorder in which a patient is unable to recognize by sight something that he can see and with which he was previously familiar. Teuber¹³ had described it as a "normal percept stripped of its meaning." The diagnosis supposes that there is good visual acuity, excellent cooperation, and the absence of aphasia. Those cases are most convincing in which the patient, failing to recognize an object by sight, immediately recognizes it by palpation or by sound.

There is considerable disagreement concerning the existence of visual agnosia, and such authorities as Critchley,¹⁴ Bender¹⁵ and Bay¹⁶ believe that visual agnosia actually results from a disturbance in perception combined with a disturbance in language. Even if one accepts the existence of visual agnosia, it is difficult to determine whether the disorder is properly classified as an agnosia or as an aphasia.

We believe that visual agnosia for objects does exist, since at least one case⁷ has been described that seems to meet the objections of those who doubt the existence of visual agnosia. In this case, the patient was a cooperative, intelligent, nonaphasic man who, despite good visual acuity, was unable to recognize familiar objects by sight. He immediately recognized those objects when he was given non-visual clues. Dramatic proof of his ability to see the drawings of familiar objects that he could not recognize, was his ability to make accurate copies of those drawings! He also was alexic (without being agraphic) and was unable to recognize the faces of people with whom he was familiar. Color-naming was impaired, but he performed normally on the pseudoisochromatic plates and on tests of color matching. The patient could assign the correct color to objects that were named to him. The authors who

reported the case called his color vision deficit a "color agnosia"; however, it would seem that his color-naming defect was indistinguishable from the defect in color-naming that has been found in other patients who have had alexia without agraphia but who did not have impaired recognition of objects or faces.

There is inadequate information available concerning the types of tests that were done to determine how well the patient recognized colors. The authors did report that when the patient was shown a green piece of paper and asked if it was the color of a banana, he replied that it was "too green." This suggests that recognition of color was preserved, at least to some extent. If it was preserved, it would be unreasonable to classify his color-naming defect as an agnostic defect.

However, we must acknowledge that defects in higher mental functions are often partial rather than complete, and that one should no more demand total failure of function before diagnosing a disorder of higher mental function than one would in diagnosing a disorder of fundamental motor or sensory function. Perhaps if more extensive testing had been done and reported on this patient, it would have been apparent that although some preservation of color recognition existed, he did show evidence of recognition failure.

An autopsy of that patient showed that his brain contained the classical lesions that would result in alexia without agraphia (infarction of the left occipital lobe and the splenium of the corpus callosum), plus a small lesion in the right occipital lobe that involved the inferior longitudinal fasciculus and nicked the inferior portion of the optic radiation.⁸

Interestingly, color recognition was also preserved in another patient¹⁷ who had a more profound variety of visual agnosia. That patient had a variety of visual agnosia that has been designated as "aperceptive," in which there is evidence of imperfect perception as well as impaired recognition. That patient sometimes used the colors that he recognized to identify objects. For example, he realized that

a picture that he was inspecting was that of a soldier because the clothing was khaki-colored. That patient probably had bilateral lesions of the posterior portions of the cerebral hemispheres, but histopathological confirmation of the sites of his lesions is unavailable.

It is difficult to be certain whether a patient who fails to correctly name a color also fails to recognize it. That is the central issue in determining whether a patient's disorder is fundamentally aphasic (a color-naming defect) or agnostic (a color-recognition defect). Recognition is often tested by correlating the heard *name* of a color to the *names* of objects or to actual objects that are shown to the patient. That is probably an inadequate test.

Since cognition of colors is only possible visually, recognition of color can be tested only by a patient's ability to derive meaning from a color that he sees. There are several tests that can be used to learn indirectly whether a patient can recognize a color that he is shown, even though he cannot name it. The patient could be shown a color and asked if it is that of an object that is characteristically of that color. For example, he could be shown a patch of yellow and asked if that is the color of a lemon. The patient also could be asked to select from a series of colors the appropriate choice for an object that is named to him. One could give him a display of patches of many colors and ask him to point to the patch that contained the color of a beet.

Tests have also been used in which colored objects are presented and the patient is requested to determine whether or not they are colored correctly. Finally, the patient can be asked to select crayons with which to color black-and-white outline drawings. The appropriateness of choice could be used as a test of his ability to recognize the colors. We must acknowledge that DeRenzi et al¹⁸ have shown that some aphasic brain-damaged patients will perform poorly on this type of test. Tests like these have not been uniformly or extensively applied; however, we were able to locate descriptions of two patients who clearly seemed unable to name

and recognize colors despite good color vision.^{19,20} Both of those patients also had pure word blindness.

Dyschromatopsia

The commonest cause of acquired dyschromatopsia due to disease of the central nervous system is that which occurs when there is a generalized depression of all visual functions. The lesions responsible can be in the optic nerve, chiasm, or in one or both of the cerebral hemispheres. Thus, the defect may be unocular or binocular; hemianopic, or present throughout the visual fields. Generally, the impairment of color vision is accompanied by a commensurate impairment in visual acuity; however, exceptions do occur.

A common exception is found among patients with optic neuropathies whose performance on pseudoisochromatic tests of color vision may be worse than one would predict from their visual acuities. As indicated here, an elevated threshold for color perception may occur within hemianopic visual field defects.

Teuber et al²¹ has indicated that defects in flicker-fusion or dark-adaptation can always be demonstrated in patients with hemiachromatopsia, but for practical purposes, an isolated hemiachromatopsia may be the only manifestation of a developing or receding hemianopia. It has been suggested that a lesion involving the fusiform and lingual gyri might be the cause of a contralateral hemiachromatopsia.²² This is of interest, since Meadows²³ has implicated bilateral lesions in this region in cases of acquired cerebral dyschromatopsia.

Albert et al²² have recently described a patient with hemidyschromatopsia due to an inferior occipital lobe lesion. The patient had recently suffered an episode of geniculocalcarine blindness from cerebrovascular disease but had recovered normal color vision and near normal visual acuity. Perimetry showed a partial, right superior quadrantanopia, but there was no defect in the left field. Special tests of color vision (by hemifield presentation of color-matching tasks) demonstrated dyschromatopsia in the intact left visual field but not in the right visual field. There was an

area of increased isotope uptake in the inferior portions of both occipital lobes on radionuclide brain scan.

Cortical Blindness.—In cortical or geniculocalcarine blindness, color sense is not only impaired, but it is usually impaired early (before movement or light sense is impaired). However, in a case of cortical blindness secondary to asphyxia described by Wechsler,²⁴ color vision was preserved despite severe impairment of visual acuity.

Cerebral Dyschromatopsia.—Acquired cerebral dyschromatopsia involving the entire visual field differs from all of the other disorders of color sense, color-naming, and color-recognition. In many ways it resembles the type of dysfunction that characterizes the prevalent form of congenital, sex-linked, recessive color blindness. The patients are unable to identify the figures on pseudoisochromatic test plates but can correctly name the colors of brightly colored objects. Both eyes are equally affected, and the dyschromatopsia occurs despite excellent visual acuity.

Patients with acquired cerebral dyschromatopsia may or may not even realize that their color sense is impaired. Appreciation of their handicap probably depends not only on the severity of the dyschromatopsia, but also on the intelligence, curiosity, and alertness of the patient. However, they frequently describe everything as being gray or lacking its normal brightness.²⁵

Cerebral dyschromatopsia also differs from congenital dyschromatopsia in several ways. First, the defect in cerebral dyschromatopsia does not follow a particular pattern of color loss—the defect is "random."²⁶ Second, patients with acquired cerebral dyschromatopsia, unlike some patients with congenital color blindness, do not see the confusion numbers on the pseudoisochromatic plates. Third, defects in the visual field are usually present and may be extensive; however, the dyschromatopsia cannot be blamed on the hemianopias, since similar visual-field defects in other patients fail to impair color vision.

Our five patients showed all of the characteristics of acquired cerebral

dyschromatopsia. Their deficit involved both eyes equally and occurred despite good visual acuity. There was no evidence of disease of their retinas, optic nerves, or chiasmata. Color-naming was normal, and there was no aphasia or agnosia. Not only did they fail to see the numerals on the Ishihara test plates, but they also failed to see the confusion numerals. Three of the five patients had had their color vision tested before their most recent neurological problem developed and had been found to have normal color vision. The other two patients were women and it would seem unlikely that they had congenital dyschromatopsia. One of the men, alone among our patients, commented on the change in his color vision in association with his neurological illness ("things don't look as bright as they used to").

To our knowledge, these five patients constitute the largest series of patients with cerebral dyschromatopsia that has so far been reported from a single source. Our three male patients are the only ones with acquired dyschromatopsia due to cerebral disease in whom there is a previous record of normal color vision. As far as we know, our series includes the only two cases in which the defect is the consequence of tumor.

The localization of the lesion or lesions responsible for acquired cerebral dyschromatopsia has recently been studied by Meadows.³ He found 13 well-described cases of acquired cerebral dyschromatopsia in the literature and added one patient that he had evaluated personally. Of the 14 patients, seven, all of whom had visual field defects, had bilateral, superior, altitudinal hemianopias, which indicates that they had bilateral lesions involving the inferior portions of the visual cortices or the optic radiations. Autopsies were not done in any of these cases. They were done in three of the other cases and, although none of them had exhibited superior altitudinal defects in the visual fields in life, they all had bilateral, inferior, occipital lesions in their brains. In two of the cases, there was infarction that primarily involved the fusiform gyri, and in the third case the lingual gyri

were predominantly involved. The areas maximally involved correspond to Brodmann's areas 18, 19, and probably 37.

Thus, 10 of the 14 patients in that series had findings consistent with bilateral, inferior, occipital lesions. It is possible that bilateral lesions were present in the remainder, but the available information is not adequate to be certain. Meadows inferred that these bilateral anterior, inferior, occipital lesions were responsible for the acquired dyschromatopsia.

Prosopagnosia is frequently associated with cerebral dyschromatopsia, as evidenced by the fact that it was present in 12 of Meadows' 14 cases. Since a recent review²⁵ of the autopsy findings in cases of prosopagnosia has shown the predominance of bilateral, inferior, occipitotemporal lesions, this is an expected association. Our patients' findings generally support Meadows' conclusions. All of our cases had clinical or laboratory evidence of bilateral lesions in the posterior portions of the cerebral hemispheres. Two of our patients had had their color vision tested after they developed the lesion in the first hemisphere and had normal color vision. Only when their second hemisphere became involved did their color vision become impaired. In four of five patients, the upper fields on both sides were involved, although in one of them (case 4) the right superior field defect appeared to be due to a temporal lobe lesion. Three of our patients had some symptoms that suggested impairment of face recognition, and in two of them testing showed frank prosopagnosia.

Although the data strongly indicate that bilateral lesions are required for the development of generalized cerebral dyschromatopsia, one must acknowledge the possibility that unilateral cerebral lesions might cause impairment of color perception throughout the visual field. DeRenzi et al^{26,27} and Scotti and Spinnler²¹ have shown that patients with right hemisphere lesions and visual-field defects perform worse than patients with left hemisphere lesions or controls on tests of color perception. These patients also perform worse on tests involving

face identification.²⁷ However, these patients are neither clinically color-blind nor prosopagnostic.

Syndromes Affecting Color

The existence of syndromes due to focal brain lesions in which color-naming, color recognition, or color perception are either selectively implicated or selectively spared indicates that some area or areas of the cerebrum must be reserved for the perception, recognition, and naming of colors. There have been investigations of the central mechanisms of visual processing, which permit some speculation about the localization of color perception in the cerebral hemispheres.

The visual cortex of monkeys contains cells responsive only to stimuli of a specific color. These cells do not respond to white stimuli. Andersen et al²⁸ and his colleagues have demonstrated that there are cells in the visual cortex of the monkey that respond specifically to blue, red, green, or yellow stimuli. Trichromatic mechanisms have been demonstrated in single neurons of the rhesus monkey foveal striate cortex,²⁹ and color opponent cells³⁰ have also been demonstrated in this area.

If color perception is dependent on the function of these cells or similar cells in man, it is easy to see that cortical blindness would be associated with a concomitant impairment of color vision. It is also possible that these cells might have a susceptibility to damage that is different from that of the other cells of the visual cortex, and there is some evidence to suggest this.

For example, these color-sensitive cells may be more vulnerable to the effects of anoxia and pressure than are the other cells of the calcarine cortex, since studies performed at various altitudes show that above 9,000 to 10,800 meters above sea level, colors appear less vibrant.³¹ Selective dyschromatopsia (in the absence of impaired visual acuity) could also be explained if there were secondary color vision areas adjacent to the primary visual cortices. That is what the clinical evidence presented by Meadows³ and found in our own cases

would suggest. There is experimental evidence to support the existence in primates of a prestriate area specialized for the processing of color vision.

Zeki³² has shown that the prestriate cortex of the monkey is anatomically organized into "a mosaic of subareas into which it may be divided, . . . which no doubt reflect a functional division of labor within the prestriate cortex for handling the various parameters of vision." He investigated a region ("the fourth visual area") that may be analogous to the area postulated in humans to cause loss of color perception on a cerebral basis. Zeki has

found that the neurons within this region respond selectively to particular wavelengths of light. These neurons are organized in columns within which all neurons respond to the same wavelength of light and are similar to the neuronal columns in the striate cortex that respond to specific receptive field orientations.

Every neuronal unit studied in the fourth visual area of the monkey was found to be color-coded. Zeki tentatively suggests that "this is an area in which color is emphasized." Is a neuronal system analogous to this one located in the area of the lingual and fusiform gyri in the human cortex?

Unilateral lesions would produce a contralateral hemiachromatopia or hemidyschromatopsia, while bilateral lesions would prevent any perception of color. It is impossible to identify what the next level of the process might be, but it would be at the next level that recognition defects might occur and explain the existence of color agnosia. One would expect the lesion responsible for agnosia to be bilateral, or if not bilateral, to be so situated as to impair transmission from the intact hemisphere to the damaged hemisphere.

References

1. MacKay G, Dunlop JC: The cerebral lesions in a case of complete acquired colour-blindness. *Scott Med Surg J* 5:503-512, 1899.
2. Tamler E: Dissociation of color and form sense following stroke. *Am J Ophthalmol* 70:101-103, 1970.
3. Meadows JC: Disturbed perception of colours associated with localized cerebral lesions. *Brain* 97:615-632, 1974.
4. Geschwind N: The varieties of naming error. *Cortex* 3:97-112, 1967.
5. Geschwind N, Fusillo M: Color-naming defects in association with alexia. *Arch Neurol* 15:137-146, 1966.
6. Oxbury JM, Oxbury SM, Humphrey NK: Varieties of colour anomia. *Brain* 92:847-860, 1969.
7. Rubens AB, Benson DF: Associative visual agnosia. *Arch Neurol* 24:305-316, 1971.
8. Benson DF, Segarra J, Albert ML: Visual agnosia-prosopagnosia: A clinicopathologic correlation. *Arch Neurol* 30:307-319, 1974.
9. Geschwind N: Disconnexion syndromes in animals and man. *Brain* 88:237-294, 585-644, 1965.
10. Cumming WJK, Hurwitz LJ, Perl NT: A study of a patient who had alexia without agraphia. *J Neurol Neurosurg Psychiatry* 33:34-39, 1970.
11. Benson DF, Geschwind N: The alexias, in Vinken PJ, Bruyn GW (eds): *Handbook of Clinical Neurology*. Amsterdam, North-Holland Publishing Co, 1969, vol 4, pp 112-140.
12. Mohr JP, Leicester J, Stoddard LT, et al: Right hemianopia with memory and color deficits in circumscribed left posterior cerebral artery territory infarction. *Neurology* 21:1104-1113, 1971.
13. Teuber HL: Alteration of perception and memory in man, in Weiskrantz L (ed): *Analysis of Behavioral Change*. New York, Harper & Row Publishers Inc, 1968.
14. Critchley M: The problem of visual agnosia. *J Neurol Sci* 1:274-290, 1964.
15. Bender MB, Feldman M: The so-called "visual agnosias." *Brain* 95:173-186, 1972.
16. Bay E: Disturbances of visual perception and their examination. *Brain* 76:515-550, 1953.
17. Benson DF, Greenberg JP: Visual form agnosia: A specific defect in visual discrimination. *Arch Neurol* 20:82-89, 1969.
18. De Renzi E, Faglioni P, Scotti G, et al: Impairment in associating colour to form, concomitant with aphasia. *Brain* 95:293-304, 1972.
19. Lhermitte F, Beauvois MF: A visual-speech disconnection syndrome: Report of a case with optic aphasia, agnosia alexia and colour agnosia. *Brain* 96:695-714, 1973.
20. Kinsbourne M, Warrington EK: Observations on colour agnosia. *J Neurol Neurosurg Psychiatry* 27:296-299, 1964.
21. Teuber HL, Battersby WS, Bender MB: *Visual Field Defects After Penetrating Missile Wounds of the Brain*. Cambridge, Harvard University Press, 1960.
22. Albert ML, Reches A, Silverberg R: Hemianopic colour blindness. *J Neurol Neurosurg Psychiatry* 38:546-549, 1975.
23. Wechsler IS: Partial cortical blindness with preservation of color vision: Report of a case following asphyxia (carbon monoxide poisoning?): A consideration of the question of color vision and its cortical localization. *Arch Ophthalmol* 9:957-965, 1933.
24. Scotti G, Spinnler H: Colour imperception in unilateral hemisphere-damaged patients. *J Neurol Neurosurg Psychiatry* 33:22-28, 1970.
25. Meadows JC: The anatomical basis of prosopagnosia. *J Neurol Neurosurg Psychiatry* 37:489-501, 1974.
26. De Renzi E, Spinnler H: Impaired performance on color tasks in patients with hemispheric damage. *Cortex* 3:194-217, 1966.
27. De Renzi E, Scotti G, Spinnler H: Perceptual and associative disorders of visual recognition: Relationship to the side of the cerebral lesion. *Neurology* 19:634-642, 1969.
28. Andersen VO, Buchmann B, Lennox-Buchthel MA: Single cortical units with narrow spectral sensitivity in monkey. *Vision Res* 2:295-307, 1962.
29. Gouras P: Trichromatic mechanisms in single cortical neurons. *Science* 168:489-492, 1970.
30. Dow BM, Gouras P: Color and spatial specificity of single units in Rhesus monkey foveal striate cortex. *J Neurophysiol* 36:79-100, 1973.
31. Walsh FB, Hoyt WF: *Clinical Neuro-Ophthalmology*, ed 3. Baltimore, Williams & Wilkins Co, 1969, p 2466.
32. Zeki SM: Colour coding in Rhesus monkey prestriate cortex. *Brain Res* 53:422-427, 1973.