



Contents lists available at ScienceDirect

Journal of Clinical Neuroscience

journal homepage: [www.elsevier.com/locate/jocn](http://www.elsevier.com/locate/jocn)

## Case report

# Internal carotid artery dissection without intracranial infarct following a minor shoulder trauma: The second pediatric case and review of the literature

Dilek Cebeci <sup>a,\*</sup>, Ebru Arhan <sup>a</sup>, Ercan Demir <sup>a</sup>, Murat Uçar <sup>b</sup>, Habibe Koç Uçar <sup>a</sup>, Ayşe Serdaroğlu <sup>a</sup>, Zeynep Öztürk <sup>a</sup>

<sup>a</sup> Department of Pediatric Neurology, Gazi University Faculty of Medicine, 10th Floor Besevler, Ankara, Turkey

<sup>b</sup> Department of Radiology, Gazi University Faculty of Medicine, Ankara, Turkey

## ARTICLE INFO

## Article history:

Received 1 April 2018

Accepted 8 July 2018

Available online xxxxx

## Keywords:

Carotid artery dissection

Minor trauma

Without infarct

## ABSTRACT

**Introduction:** Carotid artery dissections may occur in severe trauma such as motor vehicle accidents or may also develop due to minor trauma. We aimed to present a case with internal carotid artery dissection that referred to the pediatric neurology department due to speech impairment after minor shoulder trauma. **Case:** A previously healthy 10-year-old male patient was admitted to the pediatric emergency clinic due to headache, vomiting and speech impairment. In his story, we learned that he had bumped shoulder to shoulder with his friend about 6 h ago. He did not fall or hit his head. On his admission he could not speak and had right central facial paralysis. There was no infarct or diffusion limitation in MRI but MR angiography showed thinning in left internal carotid artery calibration. Fat-suppressed, non-contrast T1-weighted MRI showed that the left carotid artery had ring-shaped pathological signal changes. Low-molecular-weight heparin therapy was initiated with the diagnosis of carotid artery dissection (CAD). No hemiparesis or hemiplegia occurred in the follow-up of the patient. Within a few days, his speech improved. At the end of the first month, facial paralysis completely recovered.

**Conclusion:** In carotid artery dissections, prodromal symptoms such as transient ischemic attack, like in our patient, are rarely present in children. For good long term outcomes, it is very important to suspect, diagnose and initiate appropriate treatment in a rapid manner in carotid artery dissection before severe neurological findings such as acute ischemic stroke develops.

© 2018 Elsevier Ltd. All rights reserved.

## 1. Introduction

Carotid artery dissections occur following a vessel wall tear or rupture of the vasa vasorum. It causes an intramural hematoma and a hemodynamically significant stenosis. Secondary thromboembolism in the vessel territory can cause an ischaemic stroke. Early recognition and adequate therapy are important to prevent or limit brain ischemia [1,2].

We present a case of internal carotid artery (ICA) dissection that occurred after a minor shoulder trauma and was detected before intracranial infarct developed.

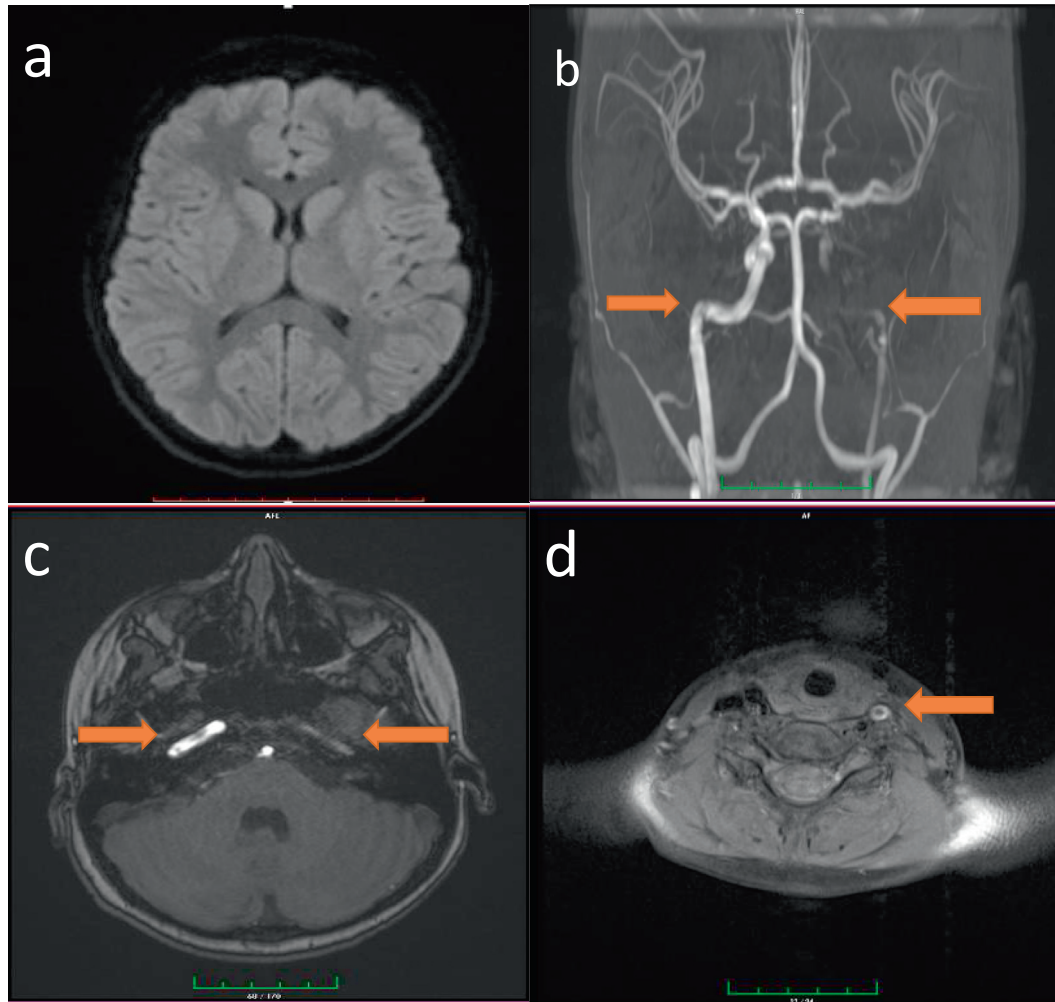
## 2. Case report

A previously healthy 10-year-old male patient was admitted to the pediatric emergency clinic due to headache, nausea, vomiting

and speech impairment. In his story, we learned that he had bumped shoulder to shoulder with his friend about 6 h ago. He did not fall or hit his head. The patient complained of headache and nausea after the collision. At first the patient had applied to another medical center and in the follow-up as he had swollen speech and could not speak, he was referred to our hospital. There was no flu symptoms, fever, diarrhea, syncope, seizure, motor loss in his anamnesis. He had no infection recently. He had no chronic illness and not using any medication. The parents were relatives. However, there was no neurological or rheumatologic disease in the family. The vital signs of the patient were normal. He could not speak, the cooperation was limited due to agitation. The right side of the mouth was immobilized and the mouth was pulling to the left. He could close his eyes bilaterally. The further neurological examination was normal. The hemogram, blood gas and biochemical parameters of the patient were normal. Because of the trauma primarily intracranial hemorrhage was doubted and the brain CT was planned, yet it was normal. Because of dysphasia and central facial paralysis, brain MR and MR angiography were planned as it

\* Corresponding author.

E-mail address: [dilekcebeci@yahoo.com](mailto:dilekcebeci@yahoo.com) (D. Cebeci).



**Fig. 1.** (a) Diffusion MRI, normal. (b) MR angiography of the supra-aortic vessels, occlusion of the left ICA. (c, d) T1 fat-suppressed MRI, left carotid artery occlusion.

might be acute ischemic stroke. There was no infarct or diffusion limitation in MRI but MR angiography showed that the left internal bifurcation was thin in the internal carotid artery calibration and some parts of internal carotid artery could not be visualized (Fig. 1). And also fat-suppressed, non-contrast T1-weighted MRI showed that the left carotid artery had ring-shaped pathological signal changes from the separation of the aortic arch to the cranial base. Low-molecular-weight heparin therapy was initiated with the diagnosis of carotid artery dissection (CAD). Thrombophilia panel, vasculitis markers, homocysteine and echocardiography were normal in terms of risk factors. No hemiparesis or hemiplegia occurred in the follow-up of the patient. Within a few days, his speech improved. At the end of the first month, facial paralysis completely recovered.

### 3. Discussion

Arterial dissections of brain and neck are a major cause of cerebrovascular injuries in children and it's seen in 20% of pediatric acute ischemic stroke [1] Dissections may be traumatic or spontaneous. In addition to severe traumas like motor vehicle accident, direct neck trauma; mild traumas like vomiting or coughing can also be seen (Table 1) [2–14]. Furthermore in roller coaster rides or water slide uses, sudden acceleration, deceleration, and rotation of the neck can stretch and compress ICA resulting in dissection.

Moyamoya disease, inherited connective tissue disorders, arteriopathies, fibromuscular dysplasia, pharyngeal infections, atherosclerosis, cystic medial necrosis and infection can be the reasons of spontaneous or minor trauma dissections [2,15].

As it is in our case, in children carotid artery dissection (CAD) typically occurs in the distal cervical segment of the ICA before entering the carotid canal at the skull base. This is due to the immature craniocervical stability resulting from the weak neck musculature, more lax pediatric ligaments, large head to neck proportion and less protective reflexes [16,17].

The most common signs and symptoms in patients undergoing craniocervical artery dissection are hemiparesis, headache, aphasia, dysphasia, anopsia and an altered level of consciousness [3,18] (Table 1). In our case, dysphasia and facial palsy were present. Hemiparesia, which can result due to the progress of the dissection, didn't develop.

Spontaneous CADs are more commonly intracranial, whereas traumatic ones are more commonly extracranial [19]. In our case, post-traumatic extracranial dissection extending to the intracranial part of ICA was observed. However, as it is a minor trauma possible underlying diseases was investigated. Thrombophilia panel, echocardiography, vasculitis markers and homocysteine levels were normal.

In pediatric CAD, prodromal symptoms rarely predict upcoming acute ischemic stroke (AIS). Usually, posttraumatic CAD is diagnosed after onset of focal neurological symptoms due to AIS. In

**Table 1**

Presenting symptoms, cause of injury and MRI or CT/MRA or CTA findings in pediatric cases.

Study/year	No. of patients	Cause of injury	Symptoms possibly linked with dissection	Ischemic symptom	MRI or CT/MRA or CTA
Borges, 2000	2	Intraoral trauma	Left hemiparesis, somnolence, confusion	Yes	Infarct/Right MCA
		Intraoral trauma	Left hemiparesis, aphasia	Yes	Infarct/Left ICA
Bar, 2002	1	Intraoral trauma	Right hemiparesis, aphasia	Yes	Infarct/Left ICA
Payton, 2004	1	"Laser tag" accident–bumped head	Slurred speech & headache; tongue deviated to right side and eyes deviated to left side, speech was dyarthric and pt was confused	Yes	Infarct/Left ICA
Agner, 2005	2	Child abuse	Seizures, left gaze unsteady gait, tremors right arm	Yes	Infarct/Left ICA
Pierrot, 2006	2	Fall	Decreased consciousness, left hemiplegia, central facial palsy	Yes	Infarct/Right ICA
		Fall	Asymptomatic	No	No infarct/Right ICA
Jariwala, 2006	1	Motor vehicle accident	Increased confusion & lack of strength & sensation of entire left upper extremity; GCS	Yes	Infarct/Right ICA
Lin, 2007	1	Water slide injury	Headache, vomiting, neck pain, numbness over left limbs, facial palsy, hemiplegia, & slurred speech	Yes	Infarct/Right ICA
Levack, 2009	1	Shoulder belt	Right hemiplegia & aphasia	Yes	Infarct/Left CCA
Moriarty, 2009	1	Intraoral trauma	Decreased level of consciousness, rightsided Weakness	Yes	Infarct/Left MCA
Agostini, 2013	2	Vigorous somersaults	Headache and visual trouble	Yes	Infarct/Left ICA
		Violent head hyperextension-rotation episodes	Irritability, right-sided weakness	Yes	Infarct/Left MCA
Nouh, 2015	1	Roller coaster ride	Left-sided weakness and left facial drop	Yes	Infarct/Right MCA
Akbaş, 2016	1	Water slide use	Slurring of speech, right-sided weakness	Yes	Infarct/Left ICA
Bent, 2016	1	Intraoral trauma	Diminished left extremity movement, dysconjugate gaze, fluctuating mental status	Yes	Infarct/Right ICA
Zant, 2017	1	Minor head trauma	Encephalopathy, left-sided hemiplegia	Yes	Infarct/Right MCA and ICA
Our patient	1	Minor shoulder trauma	Disphasia, facial palsy	Yes	No infarct/Left ICA

contrast to adult patients in which prodromal signs of upcoming AIS are frequently noted (transient ischemic attacks, amaurosis fugax, or local symptoms) children rarely present with these warning signs. Ideally, the diagnosis of CAD and the onset of therapy should occur during this latent period to prevent ischemic lesions and subsequently, improve the long-term outcome [1]. In our case, the patient had central facial paralysis and speech impairment. We defined it as transient ischemic attack, so we suspected of dissection and the diagnosis was confirmed by MRI. The treatment was initiated abruptly before intracranial infarct developed.

In the diagnosis of CAD carotid artery ultrasonography, brain MR imaging, MR angiography, CT angiography, or conventional angiography may be used. Conventional angiography has been considered the diagnostic gold standard for CAD [1]. However conventional angiography has some disadvantages in children: the need for general anesthesia, difficulty and morbidity associated with obtaining arterial vascular access, the limiting use of ionizing radiation and the greater costs compared to MRI/MRA. MRI and MRA have also been shown to be as sensitive and specific as conventional angiography. Fat-suppressed, non-contrast T1-weighted MRI of both head and neck is diagnostic for intramural hematoma and dissection. Moreover, MRI allows to simultaneously rule out or detect acute ischemic stroke [1]. In our patient, as infarct or severe neurological deficits did not occur and also considering the complications, angiography was not performed. Fat-suppressed, non-contrast T1-weighted MRI showed that the left carotid artery had ring-shaped pathological signal changes from the separation of the aortic arch to the cranial base.

In the pediatric population the treatment of CAD remains a controversial issue as controlled studies are lacking. Supportive measures such as hydration, control of hyperthermia, and seizures are complemented with the use of antiplatelet and anticoagulant medication. In adults, anticoagulation therapy is suggested for 3 to 6 months [20] to prevent injuries progressing to a higher injury grade, to reduce the number of strokes, and to prevent neurologic deterioration [20]. The use of antiplatelet therapy is even more controversial for patients who suffer a stroke following an intracranial dissection because of a real risk of intracranial hemorrhage [4].

Pandey et al. recommended 3 months of anticoagulation therapy and then change the regimen to antiplatelet therapy. We started anticoagulation, enoxaparin sodium in our case and planned to continue for 3 months.

#### 4. Conclusion

Besides the severe traumas, minor head and neck traumas may also cause carotid artery dissection. In contrast to adult patients in which prodromal signs of upcoming AIS like transient ischemic attacks are frequently noted, children rarely present with these warning signs [1]. For good long term outcomes, it is very important to suspect, diagnose and initiate appropriate treatment in a rapid manner in carotid artery dissection before severe neurological findings such as acute ischemic stroke develops.

#### References

- [1] Gunes Orman MD, Aylin Tekes MD, Andrea Poretti MD, et al. Posttraumatic carotid artery dissection in children: not to be missed! *J Neuroimaging* 2014;24(5):467–72.
- [2] Agostini M, Lupica MM, Mostert M, Deluca N, Cordero, di Montezemolo L. Cervical arterial dissection and ischaemic stroke in children: two cases. *Acta Paediatr* 2013;102(4):e142. 3.
- [3] Mortazavi MM, Verma K, Tubbs RS, Harrigan M. Pediatric traumatic carotid, vertebral and cerebral artery dissections: a review. *Childs Nerv Syst* 2011;27(12):2045–56.
- [4] Akbaş Y, Arhan E, Serdaroglu A. Intracranial internal carotid artery dissection following waterslide use: the first case report. *Childs Nerv Syst* 2016;32(3):411–3.
- [5] Mortazavi MM, Verma K, Tubbs RS, et al. Pediatric traumatic carotid, vertebral and cerebral artery dissections: a review. *Childs Nerv Syst* 2011;27(12):2045–56.
- [6] Borges G, Bonilha L, Santos SF, et al. Thrombosis of the internal carotid artery secondary to soft palate injury in children and childhood. Report of two cases. *Pediatr Neurosurg* 2000;32(3):150–3.
- [7] Payton TF, Siddiqui KM, Sole DP, et al. Traumatic dissection of the internal carotid artery. *Pediatr Emerg Care* 2004;20(1):27–9.
- [8] Agner C, Weig SG. Arterial dissection and stroke following child abuse: case report and review of the literature. *Childs Nerv Syst* 2005;21(5):416–20.
- [9] Pierrot S, Bernardeschi D, Morrisseau-Durand MP, et al. Dissection of the internal carotid artery following trauma of the soft palate in children. *Ann Otol Rhinol Laryngol* 2006;115(5):323–9.

- [10] Jariwala SP, Crowley JG, Roychowdhury S. Trauma-induced extracranial internal carotid artery dissection leading to multiple infarcts in a young girl. *Pediatr Emerg Care* 2006;22(10):737–42.
- [11] Levack MM, Pettitt BJ, Winston AD. Carotid artery thrombosis and delayed stroke associated with the use of a shoulder belt in a teenager. *J Pediatr Surg* 2009;44(8):E29–33.
- [12] Moriarty JM, Lukas C, Rossler L, et al. Carotid artery dissection following a minor household accident in a 10-month-old child. *Ir J Med Sci* 2009;178(4):535–9.
- [13] Nouh A, Vela-Duarte D, Grobelny T, et al. Internal carotid artery dissection after a roller coaster ride in a 4-year-old: case report and review of the literature. *Pediatr Neurol* 2015;52(3):349–51.
- [14] Zant R, Melter M, Doerfler C, et al. Carotid artery dissection with associated territory stroke after a minor head trauma in a healthy 4-month-old child. *Pediatr Emerg Care* 2017;33(12):e177–9.
- [15] Rafay MF, Armstrong D, Deveber G, Domi T, Chan A, MacGregor DL. Craniocervical arterial dissection in children: clinical and radiographic presentation and outcome. *J Child Neurol* 2006;21:8–16.
- [16] Pinto PS, Meoded A, Poretti A, et al. The unique features of traumatic brain injury in children. Review of the characteristics of the pediatric skull and brain, mechanisms of trauma, patterns of injury, complications, and their imaging findings-Part 2. *J Neuroimaging* 2012;22:e18–41.
- [17] Pinto PS, Poretti A, Meoded A, et al. The unique features of traumatic brain injury in children. Review of the characteristics of the pediatric skull and brain, mechanisms of trauma, patterns of injury, complications and their imaging findings-Part 1. *J Neuroimaging* 2012;22:e1–e17.
- [18] Pandey AS, Hill E, Al-Holou WN. Management of pediatric craniocervical arterial dissections. *Childs Nerv Syst* 2015;31(1):101.
- [19] Roukoz B, Chamoun MD, Michele E, Mawad MD. Extracranial traumatic carotid artery dissections in children: a review of current diagnosis and treatment options. *J Neurosurg Pediatr* 2008;2(2):101–8.
- [20] Schievink WI. The treatment of spontaneous carotid and vertebral artery dissections. *Curr Opin Cardiol* 2000;15:316–21.