

CASE REPORT

Spinal myoclonus: a rare presentation of cervical myelopathy

Ioannis Christodoulides, Anastasios Giamouriadis, James Bashford, Konstantinos Barkas

Department of Neurosurgery,
King's College Hospital NHS
Foundation Trust, London, UK

Correspondence to

Mr Ioannis Christodoulides,
ychristodoulides@gmail.com

Accepted 4 July 2018

SUMMARY

Myoclonus describes a movement disorder characterised by brief, abrupt and involuntary contractions of muscles or groups of muscles, usually associated with intracranial lesions, with limited evidence linking it to spinal pathologies. The pathophysiology of spinal myoclonus is extensive and multifactorial. Infection, intramedullary and extramedullary space-occupying lesions, trauma, vascular abnormalities, degenerative processes and cervical spondylosis have been implicated with the disease, the latter been associated with cervical stenosis with no reported cases linking it to an underlying cervical disc herniation. Although medical therapy with clonazepam, levetiracetam, valproate, tetrabenazine hydrochloride and spinal block injections has been equivocal, spinal myoclonus secondary to disc herniation requires surgical intervention. This report describes a case of segmental spinal myoclonus, secondary to a herniated cervical intervertebral disc. After corpectomy and a cage-augmented fusion technique, the myoclonic symptoms resolved. To our knowledge, this was the first report to describe the successful management of discogenic spinal myoclonus with spinal surgery.

BACKGROUND

Myoclonus describes a movement disorder that is characterised by brief, abrupt and involuntary contractions of muscles or groups of muscles. A well-established association between intracranial lesions and myoclonus exists but there is only limited evidence to link spinal pathology with this clinical presentation. The pathophysiology of spinal myoclonus is extensive and often multifactorial. Infection, intramedullary and extramedullary space-occupying lesions, trauma, vascular abnormalities, degenerative processes and cervical spondylosis have all been implicated with the disease with only a handful of cases linking it to underlying intervertebral disc herniation. Furthermore, to our knowledge, cervical disc herniation as a cause of segmental myoclonus has not been reported yet, with most published cases reporting cervical stenosis as the main cause. Although medical therapy with drugs such as clonazepam, levetiracetam, valproate and tetrabenazine hydrochloride as well as spinal or epidural block injections for resistant cases has proven to be equivocal, spinal myoclonus secondary to a disc herniation requires surgical intervention. In the present report, we describe a case of segmental spinal myoclonus, secondary to a

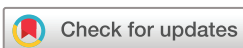herniated cervical intervertebral disc. After corpectomy and a cage-augmented fusion technique, the myoclonic symptoms gradually resolved. To our knowledge, this was the first report to describe the successful management of discogenic segmental spinal myoclonus with spinal surgery.

CASE PRESENTATION

A 75-year-old female patient, with a background of controlled hypertension, diet-controlled diabetes mellitus and asthma, presented with progressive cervical myelopathy. She initially experienced neck and bilateral shoulder pain that worsened over a period of 3 months and was associated with progressively worsening symmetrical hand paraesthesia involving the C6-8 dermatomes, reduced power in the hands, predominantly grip strength and ataxia mainly in her upper limbs that impaired her functional status. These were later accompanied by involuntary, jerky movements in her upper limbs. She denied any bladder or bowel symptoms. With regards to her family history, her father suffered from a tic disorder. Her medication history included amlodipine 5 mg OD, symbicort 400/12 two puffs OM, salbutamol inhaler when required and as required tramadol and chlorphenamine tablets. On physical examination, cranial nerve examination was unremarkable with no evident dysphasia, cognitive decline, head tremors or dystonia or nystagmus, with normal saccades and facial, tongue and palatal movements. The patient was well orientated with no clinical suspicion of a psychogenic source of her movement disorder.¹ On examination of her upper limbs, tone and power were normal with an obvious involuntary, intermittent jerking movement. More specifically, this involved fast, frequent jerky movements mainly focused at the fingers and forearm both at rest but worse on the outstretched hand (postural). There was no associated rubral tremor with otherwise normal coordination, symmetrically brisk reflexes and no bradykinesia. Regarding her lower limbs, neurological examination was unremarkable. Her basic bedside observations were all within normal parameters.

INVESTIGATIONS

A cervical spine MRI study showed a soft disc extrusion at C3/4 level causing cord compression with an associated T2-weighted hyperintensity in the cord at the same level (figure 1). Routine laboratory



© BMJ Publishing Group Limited. No commercial re-use. See rights and permissions. Published by BMJ.

To cite: Christodoulides I, Giamouriadis A, Bashford J, et al. *BMJ Case Rep* Published Online First: [please include Day Month Year]. doi:10.1136/bcr-2018-225455

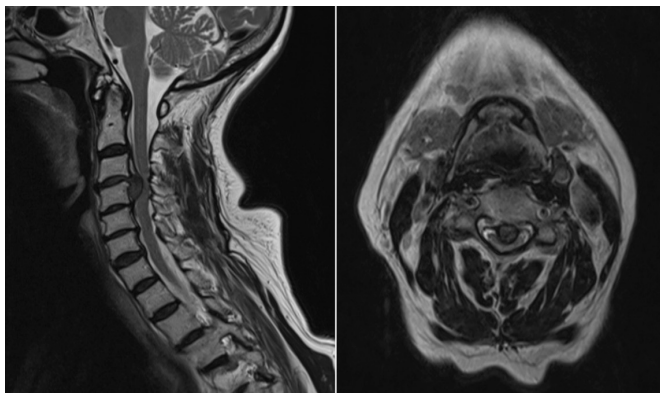


Figure 1 MRI T2WI sagittal (left) and axial (right) views demonstrating a large disc prolapse at C3/4 with inferior migration behind the vertebral body of C4 causing severe spinal cord compression. T2WI, T2-weighted image.

biochemical studies included full blood count, renal profile with electrolytes, calcium, magnesium and C reactive protein, all of which were unremarkable. In addition, liver and thyroid function tests were normal. No electromyographic or electroencephalographic (EEG) investigations were performed.

TREATMENT

After discussion in the spinal multidisciplinary meeting, the patient underwent a standard C4 corpectomy with the disc fragment posterior to the posterior longitudinal ligament identified and removed. The operation was uneventful with no immediate postoperative complications and the patient recovered very well (figure 2).

OUTCOME AND FOLLOW-UP

She maintained full power in her upper limbs with residual paraesthesia to her hand, which was later attributed to carpal tunnel syndrome that resolved post release of the flexor retinaculum. Her myoclonic movements in the upper limbs resolved completely immediately postoperatively. Plain radiographs demonstrated appropriate and satisfactory positioning of the cage and plate. Additionally, on subsequent neurological review

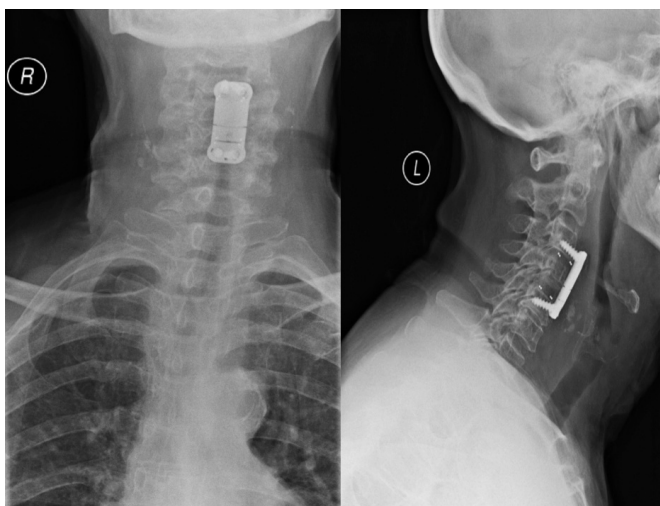


Figure 2 Anteroposterior (left) and lateral (right) postoperative cervical X-rays demonstrating a satisfactory positioning of the cage and plate.

and considering the absence of any evidence of underlying neurodegenerative condition, this was largely attributed to her discogenic, spinal pathology. She has now been discharged fully from our care.

DISCUSSION

Overview

Myoclonus is commonly classified according to its location of origin: cortical, subcortical, spinal and peripheral.² Clinical history is essential to assess the underlying cause and includes age of onset, character of the myoclonus, precipitating and alleviating factors (spontaneous vs reflex), family history and other associated symptoms. Clinical examination also helps to identify additional characteristics such as distribution of muscle jerks (focal vs generalised), occurrence at rest, postural or during an action and their sensitivity to stimuli. Sometimes, further localisation of the source relies on investigations such as electromyography and electroencephalography.¹ Spinal myoclonus can be further subclassified into focal spinal myoclonus (FSM), segmental spinal myoclonus (SSM) and proprioceptive spinal myoclonus (PSM).³ FSM corresponds to myoclonus confined to single spinal myotomes while SSM describes muscle twitches that correspond to several associated spinal myotomes,⁴ originating from one or few adjacent segments of the spinal cord.⁵ This is usually due to localised damage to spinal nerves or changes in the function of the underlying spinal cord, with the clinical presentation affecting those body parts correlated to the anatomical location of the lesion. It produces rhythmic muscle jerks at a typical frequency of 1–3 Hz, that are frequently associated with pain and demonstrate no particular association to stimulus intensity⁶ or EEG changes.⁷ On the contrary, PSM, a rare manifestation of the disorder, describes complex, multisegmental simultaneous myotomal involvement of the trunk and limbs, mediated through intersegmental fibre tracts,⁸ while sparing cranially innervated and bulbar muscles.^{3,9–11} These are usually arrhythmic with direct correlation to stimulus sensitivity. All subtypes of spinal myoclonus appear to be resistant to supraspinal effects that involve fatigue, stress and lack of sleep, thus they are present during both sleep and at rest, despite some published cases that support the opposite.^{12–14} In our case, the myoclonic twitches were rhythmic in nature, involving the upper limbs with sparing of the trunk and the lower limbs, while demonstrating no relation to extrinsic stimulation, for example, during head and neck movements. Thus, the clinical presentation in this case is more consistent with SSM. With the majority of spinal myoclonus being idiopathic in origin, various other pathologies have been implicated as potential causes, including infective/inflammatory,^{15–17} post-infective,¹⁸ intramedullary or extramedullary neoplasms,¹⁹ paraneoplastic,²⁰ syringomyelia,^{10,21} spinal cord trauma,^{22,23} vascular abnormalities, degenerative motor neuron disease and demyelination²⁴ and cervical spondylosis.^{21,25} Thus, a contrast-enhanced MRI of the whole neuro-axis is essential to identify the segmental lesion responsible for the myoclonus which should be later supplemented with additional investigations to exclude a systemic disorder (eg, vitamin B₁₂ deficiency and HIV).⁸ Several reports have also linked spinal myoclonus with postoperative changes associated with laminectomies²⁶ but no clear correlation has been demonstrated between degenerative spinal disease and movement disorders, that included myoclonus,^{7,21,27} dystonia^{28–30} and choreoathetosis.³¹ Of important note however is that despite these underlying pathologies, only a small fraction presents clinically with myoclonal disorders, with the majority presenting simply as cervical myelopathy, suggesting that the type of lesion

itself is not the culprit, but instead the underlying involvement of the interneuronal fibres (see below).⁸

To our knowledge, there has only been one case report of a cervical disc herniation causing PSM that was successfully treated with surgical management. Several other reports have been published, suggesting the possible link between degenerative spinal disease and movement disorders, that has been estimated to lie around 0.17%. To date, this current report might be the first description of a cervical disc herniation that caused SSM.

Pathophysiology

Neurophysiological studies have demonstrated that the resulting rhythmic myoclonic jerks can be attributed to a dysfunction of the underlying spinal cord circuitry at the specific segment involved, in what is referred to as a spinal segmental generator (SSG). This represents a group of neurons within the spinal cord that are able to generate rhythmic motor activities in the absence of any sensory or other afferent input.^{5 32} This occurs in the absence of any EEG evidence of cortical involvement.³³ The inappropriate function of the SSG is reflected on the EMG trace as muscle contractions in the range of usually 1–3 Hz lasting between +50 and –500 ms.^{34–37} Experimental animal studies have launched the discussion on the pathophysiological mechanisms responsible for SSG dysfunction, through iatrogenically induced spinal cord lesions and infections,^{15 38–40} with deficiencies in inhibitory neurotransmitters and vitamin B₁₂ supplementing the key hypotheses.⁴¹ This was explored further in the late 1980s, demonstrating that neuronal destruction within the grey matter of the spinal cord at the involved segments could precipitate myoclonal movements.^{42 43} This ultimately results in disruption of the local neuronal circuitry and uncontrolled, simultaneous motor neuron firing within the affected segment. Subsequent evidence suggested that imbalances between dorsal, inhibitory interneurons and ventral horn, excitatory motor neurons, alongside active reorganisation of the spinal circuits could cause hyperactivity and re-excitation within the specific spinal segment, establishing this as the main culprit.^{44–46} Additionally, despite the lack of cerebral involvement, central recordings from segmental peripheral sensory stimulation have revealed responses with abnormally reduced latencies that may indeed reflect the hyperexcitable background that drives myoclonic movements.^{8 47 48} However, these findings were case-dependent with still low levels of evidence in their favour and sometimes conflicting evidence.⁴⁹ Combining the above suggestions, it is therefore likely that SSM does originate from a dysfunctioning SSG, which is further influenced by supraspinal and afferent inputs due to the local reorganisation and plasticity within the spinal cord.

Treatment

Following the above-suggested mechanisms, the overall aim in treatment rests to re-establish the equilibrium between inhibitory and excitatory neuronal activity.⁸ This is generally achieved through antiseizure medication that dampens the hyperexcitable state of the ventral horn neurons by stimulating the remaining, functioning inhibitory interneurons. SSM secondary to degenerative spinal disease has been managed successfully previously with pharmacotherapy, with clonazepam and tetrabenazine being the only medications that have demonstrated encouraging results,⁷ with the latter being used in refractory cases. Recent reports on the use of levetiracetam have also demonstrated optimistic results.^{37 50} More invasive approaches involve

local injections of local anaesthetic or botulinum toxin, mainly for their analgesic effect, via the transforaminal approach that achieves a more uneven distribution towards the ventral part of the cord that houses motor neurons, rather than the dorsolateral part that houses inhibitory interneurons.^{51 52} Surgical intervention through decompressive laminectomies and foraminotomies has proved the only successful intervention in other movement disorders including dystonias.^{28–31} In our case, considering the progression of the clinical signs and radiographic appearances of an underlying signal change in the spinal cord, it is believed that the herniated cervical disc had caused local spinal cord dysfunction due to mechanical irritation and ischaemia, in a similar way to the one described above. Thus, surgical intervention to extract the disc fragment will eventually relieve the spinal cord from the extrinsic pressure and improve its chances of recovery, something that was demonstrated postoperatively with the gradual resolution of symptoms and the confirmation of this cause–effect relationship.⁵³ Nevertheless, the rarity of this clinical manifestation does suggest the existence of a very complex underlying mechanism, which despite being not fully understood yet should be kept in mind when managing patients presenting with cervical disc pathologies.

Learning points

- ▶ Herniated intervertebral discs could be a rare but still potential cause of myoclonus.
- ▶ Do not overlook this differential as it may lead to misdiagnosis.
- ▶ Surgical management (discectomy +/- cage fusion) has been demonstrated to be a successful treatment option.
- ▶ Consider epidural nerve root injections via the transforaminal approach in less severe case.
- ▶ Remember however the sometimes evolving natural history of this pathology, with symptomatic treatment providing an ultimate buffer for the underlying pathology to resolve.

Contributors IC: conducted the main literature review and writing of the case report. AG, JB and KB: conducted the patient's operation and supervised the patient's postoperative recovery and follow up, as well as reviewed the current manuscript.

Funding The authors have not declared a specific grant for this research from any funding agency in the public, commercial or not-for-profit sectors.

Competing interests None declared.

Patient consent Obtained.

Provenance and peer review Not commissioned; externally peer reviewed.

REFERENCES

- 1 Fahn S, Williams DT. Psychogenic dystonia. *Adv Neurol* 1988;50:431–55.
- 2 Martinez MS, Fontoira M, Celester G, et al. Myoclonus of peripheral origin: case secondary to a digital nerve lesion. *Mov Disord* 2001;16:970–4.
- 3 Brown P, Thompson PD, Rothwell JC, et al. Axial myoclonus of propriospinal origin. *Brain* 1991;114:197–214.
- 4 Savrun FK, Uluduz D, Erkol G, et al. Spinal myoclonus following a peripheral nerve injury: a case report. *J Brachial Plex Peripher Nerve Inj* 2008;3:18.
- 5 Termsarasab P, Thammongkolchai T, Frucht SJ. Spinal-generated movement disorders: a clinical review. *J Clin Mov Disord* 2015;2:18.
- 6 Caviness JN, Brown P. Myoclonus: current concepts and recent advances. *Lancet Neurol* 2004;3:598–607.
- 7 Hoehn MM, Cherington M. Spinal myoclonus. *Neurology* 1977;27:942–6.
- 8 Caviness JN. Segmental Myoclonus. *Hyperkinetic Movement Disorders Differential Diagnosis and treatment*. 1st Edition, 2012:221–35.
- 9 Chokroverty S. Propriospinal Myoclonus. *Clin Neurosci* 1996;3:219–22.
- 10 Brown P, Rothwell JC, Thompson PD, et al. Propriospinal myoclonus: evidence for spinal "pattern" generators in humans. *Mov Disord* 1994;9:571–6.
- 11 Chokroverty S, Walters A, Zimmerman T, et al. Propriospinal myoclonus: a neurophysiologic analysis. *Neurology* 1992;42:1591–5.

- 12 Lagueny A, Tison F, Burbaud P, et al. Stimulus-sensitive spinal segmental myoclonus improved with injections of botulinum toxin type A. *Mov Disord* 1999;14:182–5.
- 13 Massimi L, Battaglia D, Paternoster G, et al. Segmental spinal myoclonus and metastatic cervical ganglioglioma: an unusual association. *J Child Neurol* 2009;24:365–9.
- 14 Marrufo M, Politsky J, Mehta S, et al. Paroxysmal Kinesigenic Segmental Myoclonus due to a spinal cord glioma. *Mov Disord* 2007;22:1801–3.
- 15 Campbell AM, Garland H. Subacute myoclonic spinal neuronitis. *J Neurol Neurosurg Psychiatry* 1956;19:268–74.
- 16 Levy R, Plassche W, Riggs J, et al. Spinal myoclonus related to an arteriovenous malformation. Response to clonazepam therapy. *Arch Neurol* 1983;40:254–5.
- 17 Casazza M, Bracchi M, Girotti F. Spinal myoclonus and clinical worsening after intravenous contrast medium in a patient with spinal arteriovenous malformation. *AJNR Am J Neuroradiol* 1985;6:965–6.
- 18 Bhatia K, Thompson PD, Marsden CD. "Isolated" postinfectious myoclonus. *J Neurol Neurosurg Psychiatry* 1992;55:1089–91.
- 19 Garcin R, Rondot P, Guiot G. Rhythmic myoclonus of the right arm as the presenting symptom of a cervical cord tumour. *Brain* 1968;91:75–84.
- 20 Phanthumchinda K. Syndrome of progressive ataxia and palatal myoclonus: a case report. *J Med Assoc Thai* 1999;82:1154–7.
- 21 Jankovic J, Pardo R. Segmental myoclonus. Clinical and pharmacologic study. *Arch Neurol* 1986;43:1025–31.
- 22 Bussel B, Roby-Brami A, Azouvi P, et al. Myoclonus in a patient with spinal cord transection. Possible involvement of the spinal stepping generator. *Brain* 1988;111:1235–45.
- 23 Fouillet N, Wiart L, Arné P, et al. Propriospinal myoclonus in tetraplegic patients: clinical, electrophysiological and therapeutic aspects. *Paraplegia* 1995;33:678–81.
- 24 Alroughani RA, Ahmed SF, Khan RA, et al. Spinal segmental myoclonus as an unusual presentation of multiple sclerosis. *BMC Neurol* 2015;15:15.
- 25 Kapoor R, Brown P, Thompson PD, et al. Propriospinal myoclonus in multiple sclerosis. *J Neurol Neurosurg Psychiatry* 1992;55:1086–8.
- 26 Capelle HH, Wöhrle JC, Weigel R, et al. Movement disorders after intervertebral disc surgery: coincidence or causal relationship? *Mov Disord* 2004;19:1202–8.
- 27 Daniel DG, Webster DL. Spinal segmental myoclonus. Successful treatment with cervical spinal decompression. *Arch Neurol* 1984;41:898–9.
- 28 Al-Kawi MZ. Focal dystonia in spinal stenosis. *Arch Neurol* 1987;44:692–3.
- 29 Blunt SB, Richards PG, Khalil N. Foot dystonia and lumbar canal stenosis. *Mov Disord* 1996;11:723–5.
- 30 Wright RA, Ahlskog JE. Focal shoulder-elevation dystonia. *Mov Disord* 2000;15:709–13.
- 31 Tan EK, Lo YL, Chan LL, et al. Cervical disc prolapse with cord compression presenting with choreoathetosis and dystonia. *Neurology* 2002;58:661–2.
- 32 Dietz V. Spinal cord pattern generators for locomotion. *Clin Neurophysiol* 2003;114:1379–89.
- 33 Marder E, Calabrese RL. Principles of rhythmic motor pattern generation. *Physiol Rev* 1996;76:687–717.
- 34 Jero J, Salmi T. Palatal myoclonus and clicking tinnitus in a 12-year-old girl—case report. *Acta Otolaryngol Suppl* 2000;543:61–2.
- 35 Calancie B. Spinal myoclonus after spinal cord injury. *J Spinal Cord Med* 2006;29:413–24.
- 36 Bagnato S, Rizzo V, Quartarone A, et al. Segmental myoclonus in a patient affected by syringomyelia. *Neurol Sci* 2001;22:27–9.
- 37 Keswani SC, Kossoff EH, Krauss GL, et al. Amelioration of spinal myoclonus with levetiracetam. *J Neurol Neurosurg Psychiatry* 2002;73:457–8.
- 38 Turtschaninow P. Experimentelle Studien über den Ursprungsort einiger klinisch wichtiger toxischer Krampfformen. *Archiv für Experimentelle Pathologie und Pharmakologie* 1894;34:208–46.
- 39 Luttrell CN, Bang FB, Luxenberg K. Newcastle Disease Encephalomyelitis in Cats. *A.M.A. Archives of Neurology & Psychiatry* 1959;81:285–91.
- 40 Kao LI, Crill WE. Penicillin-induced segmental myoclonus. I. Motor responses and intracellular recording from motoneurons. *Arch Neurol* 1972;26:156–61.
- 41 Tsao JW, Cooper EC. Reflex-sensitive spinal segmental myoclonus associated with vitamin B12 deficiency. *Neurology* 2003;61:867–8.
- 42 Davis SM, Murray NM, Diengdoh JV, et al. Stimulus-sensitive spinal myoclonus. *J Neurol Neurosurg Psychiatry* 1981;44:884–8.
- 43 Howell DA, Lees AJ, Toghiani PJ. Spinal internuncial neurones in progressive encephalomyelitis with rigidity. *J Neurol Neurosurg Psychiatry* 1979;42:773–85.
- 44 Devetag Chalaupka F, Bernardi M. A case of segmental myoclonus in amputation stump: evidence for spinal generator and physiopathogenetic hypothesis. *Ital J Neurol Sci* 1999;20:327–31.
- 45 Campos CR, Limongi JC, Machado FC, et al. A case of primary spinal myoclonus: clinical presentation and possible mechanisms involved. *Arq Neuropsiquiatr* 2003;61:112–4.
- 46 Ogata K, Yamada T, Yoshimura T, et al. [A case of spinal myoclonus associated with epidural block for lumbago]. *Rinsho Shinkeigaku* 1999;39:658–60.
- 47 Hopkins AP, Michael WF. Spinal myoclonus. *J Neurol Neurosurg Psychiatry* 1974;37:1112–5.
- 48 Kono I, Ueda Y, Araki K, et al. Spinal myoclonus resembling belly dance. *Mov Disord* 1994;9:325–9.
- 49 Rothwell JC. Pathophysiology of spinal myoclonus. *Myoclonus and Paroxysmal Dyskinesias. Advances in Neurology. Lippincott Williams & Wilkins, Philadelphia, pp* 2002:37–44.
- 50 Estraneo A, Saltalamacchia AM, Loreto V. Spinal myoclonus following herpes zoster radiculitis. *Neurology* 2007;68:E4.
- 51 Fox EJ, Villanueva R, Schutta HS. Myoclonus following spinal anesthesia. *Neurology* 1979;29:379–80.
- 52 Moorthy SS, Dierdorf SF. Restless legs during recovery from spinal anesthesia. *Anesth Analg* 1990;70:337.
- 53 Capelle HH, Wöhrle JC, Weigel R, et al. Propriospinal myoclonus due to cervical disc herniation. Case report. *J Neurosurg Spine* 2005;2:608–11.

Copyright 2018 BMJ Publishing Group. All rights reserved. For permission to reuse any of this content visit <http://group.bmj.com/group/rights-licensing/permissions>.
BMJ Case Report Fellows may re-use this article for personal use and teaching without any further permission.

Become a Fellow of BMJ Case Reports today and you can:

- ▶ Submit as many cases as you like
- ▶ Enjoy fast sympathetic peer review and rapid publication of accepted articles
- ▶ Access all the published articles
- ▶ Re-use any of the published material for personal use and teaching without further permission

For information on Institutional Fellowships contact consortiasales@bmjgroup.com

Visit casereports.bmj.com for more articles like this and to become a Fellow