

Accepted Manuscript

Extending endovascular embolization to type A spinal perimedullary arteriovenous fistula : technical nuances, challenges and initial results

Virender Malik, MD, DNB, Santhosh Kumar Kannath, MD, PDCC, Jayadevan Enakshy Rajan, MD, DM, Jospaul Lukas, MD



PII: S1878-8750(18)31802-3

DOI: [10.1016/j.wneu.2018.08.021](https://doi.org/10.1016/j.wneu.2018.08.021)

Reference: WNEU 8878

To appear in: *World Neurosurgery*

Received Date: 12 May 2018

Revised Date: 1 August 2018

Accepted Date: 2 August 2018

Please cite this article as: Malik V, Kannath SK, Rajan JE, Lukas J, Extending endovascular embolization to type A spinal perimedullary arteriovenous fistula : technical nuances, challenges and initial results, *World Neurosurgery* (2018), doi: 10.1016/j.wneu.2018.08.021.

This is a PDF file of an unedited manuscript that has been accepted for publication. As a service to our customers we are providing this early version of the manuscript. The manuscript will undergo copyediting, typesetting, and review of the resulting proof before it is published in its final form. Please note that during the production process errors may be discovered which could affect the content, and all legal disclaimers that apply to the journal pertain.

Title: Extending endovascular embolization to type A spinal perimedullary arteriovenous fistula : technical nuances, challenges and initial results

Running Title: Embolization of type A spinal perimedullary fistula with liquid embolic device

Authors:

First Author

Virender Malik, MD, DNB

Senior Resident, Department of Imaging Sciences and Interventional Radiology, Sree Chitra Tirunal Institute of Medical Sciences and Technology, Trivandrum, Kerala, India. Pin no:695011

Phone no:+91-4712524117

Email: virender2323@gmail.com

Santhosh Kumar Kannath, MD,PDCC

Associate Professor, Neurointervention Center, Department of Imaging Sciences and Interventional Radiology, Sree Chitra Tirunal Institute of Medical Sciences and Technology, Trivandrum, Kerala, India. Pin no:695011

Phone no:+91-4712524117

Email: drsanthoshkannath@gmail.com

Jayadevan Enakshy Rajan, MD,DM

Associate Professor, Neurointervention Center, Department of Imaging Sciences and Interventional Radiology, Sree Chitra Tirunal Institute of Medical Sciences and Technology, Trivandrum, Kerala, India. Pin no:695011

Phone no:+91-4712524117

Email: drjayadevan@gmail.com

Jospaul Lukas, MD

Senior Resident, Department of Imaging Sciences and Interventional Radiology, Sree Chitra Tirunal Institute of Medical Sciences and Technology, Trivandrum, Kerala, India. Pin no:695011

Phone no:+91-4712524117

Email: jospaul_lukas@sctimst.ac.in

Correspondence author :

Santhosh Kumar Kannath, MD,PDCC

Associate Professor, Neurointervention Center, Department of Imaging Sciences and Interventional Radiology, Sree Chitra Tirunal Institute of Medical Sciences and Technology, Trivandrum, Kerala, India. Pin no:695011

Phone no:+91-4712524117

Email: drsanthoshkannath@gmail.com

Affiliations: Sree Chitra Tirunal Institute for medical Sciences and technology, Thiruvanthapuram

Key Words: Type A PMAVF Embolization, liquid embolic device

Abstract word count: 236

Text word count: 2473

Number of references: 22

Number of tables and/or figures: 03 figures and 01 table

Number of videos: Nil

No portion of the paper has been presented or published previously.

“Conflict of interest : None”

“Disclosure of funding : None”

ACCEPTED MANUSCRIPT

Title: Extending endovascular embolization to type A spinal perimedullary arteriovenous fistula using liquid embolic agent: technical nuances, challenges and initial outcome

Running Title: Embolization of type A spinal perimedullary fistula with liquid embolic device

INTRODUCTION

Perimedullary arteriovenous fistulas (PMAVFs) are characterized by its location on or immediately subjacent to the spinal piamater and the presence of arteriovenous fistula with no intervening nidus.¹ PMAVFs constitute 8-19% of all spinal vascular malformations. The entity was first described by Djindjian et al, and was subsequently classified as type IV spinal vascular malformations by Heros et al.^{2,3} Based on the increasing degree of shunt flow and vascular enlargement, Anson and Spetzler further sub-classified these type IV spinal vascular malformations into type IVa, IVb and Type IVc.⁴ Rodesch et al. classified PMAVFs into macro-AVF and micro-AVF with the latter accounting for approximately 75%. Micro AVFs are characterized by mildly enlarged arteries draining into non ectatic veins. The macro-AVFs which account for rest of PMAVF are more common in children and are characterized by one or more enlarged spinal cord arteries draining into ectatic veins.¹ The precise etiology of PMAVFs remain unclear, though congenital nature of this entity is more favored over an acquired cause. The occasional occurrence of simultaneous multiple PMAVFs, simultaneous intramedullary arteriovenous malformations and PMAVFs, association with subcutaneous vascular nevi, Klippel-Trenaunay syndrome and Parkes-Weber syndrome support the former, while reports highlighting development of PMAVF following epidural anesthesia, spinal canal surgery or trauma point the etiology to the latter.^{5,6}

PMAVFs show preponderance for thoracolumbar region and are mostly symptomatic. The definitive treatment of PMAVFs is warranted in view of the progressive neurological decline noted with conservative mode of management.^{7,8} The various treatment options include microsurgical excision, endovascular embolization or a multimodal approach. The better understanding of the disease process and its angiomorphology, advances in hardware and techniques have resulted in the adaptation of endovascular embolization as an effective first line of treatment in PMAVF. Due to the relatively larger size of the feeding arteries in type B and C

PMAVFs, endovascular approach is usually considered the initial treatment of choice in these subtypes. Multiple embolizing agents are described in the endovascular treatment of type C and type B PMAVFs, among which, n-butyl-2-cyanoacrylate (nBCA)(B Braun, Melsungen, Germany) is considered to be more effective.⁹ A few isolated reports of successful embolization using EVOH based liquid embolics such as onyx (Covidien/Medtronic, Irvine, California, United States) in subtype B is also reported recently.¹⁰ The characteristically small size of the feeding arteries in subtype A lesion merits meticulous preprocedure planning, higher level of expertise and appropriately chosen hardware for successful endovascular embolization. Recently, n-BCA has been successfully used for endovascular embolization of a few of subtype A lesion.⁹ However successful use of onyx or squid (Emboflu, Switzerland) in subtype A PMAVF is not previously documented. In the present report, we describe three cases of successful embolization of type A PMAVFs using EVOH based liquid embolization agent, squid. We also discuss the technical nuances associated with the use of this liquid embolics specific to these vascular lesions.

CASE SERIES

Case 1

A 53-year-old male presented with gradually progressive weakness and paresthesia involving both lower limbs for one year, followed by constipation for 6 months and urge incontinence for last 2 months. The clinical examination revealed bilateral symmetric paraparesis, absent knee and ankle reflexes, 50% loss of pain and temperature sensation till D12 level and impaired vibration sensation up to L1 level. Magnetic resonance imaging (MRI) showed conspicuous intramedullary hyperintensity extending from the T7 to conus level, with few associated flow voids along the dorsal surface of the cord (Fig1A). The patient underwent spinal angiography under general anesthesia (GA), which revealed a ventrally located PMAVF at L2 level with arterial feeder from minimally enlarged left T9 level radiculomedullary artery and venous drainage into perimedullary veins that finally egressed out through radicular veins into vertebral venous plexus (Fig1B and IC) .

A 6F renal guide catheter (RGC, Medtronic, Minneapolis, USA) was placed in the abdominal aorta and the left D9 posterior intercostal artery was selectively catheterized using a 4F Judkins left coronary catheter (Cordis, Warren, New Jersey, United States). Prior to catheterization of

ASA, the intercostal artery was primed with 1 mg of Nimodipine bolus. Subsequently, the radiculomedullary artery was cannulated using a Marathon microcatheter and Mirage microguidewire (Covidien/Medtronic, Irvine, California, United States) and navigated under roadmap guidance close to the fistulous site. After confirming the optimal position of microcatheter, the fistulous embolization was performed using squid 12, achieving good antegrade percolation and complete cessation of the shunt (Fig 1D). On second postoperative day, deterioration in motor power of both lower limb was noted and he was managed conservatively with intravenous heparinization, which was later switched over to oral anticoagulation (Acitrom) to maintain INR of 2 -2.5 and continued for a month. Preprocedure modified Aminoff Logue score (Gait grade 4, Micturition grade 2) improved to Gait grade 2 and Micturition grade 1 at three and six month clinical follow-up post embolization. The follow-up imaging at 6 months confirmed persistence of the occlusion.

Case 2

A 65-year-old male presented with moderate intensity lower backache for last 2 years. He complained of gradually progressive weakness of both lower limbs for last one year and paresthesia involving both legs for last 7 months. His bowel and bladder habits were normal. The clinical examination revealed bilateral symmetric paraparesis, absent deep tendon reflexes in both lower limbs, absent abdominal superficial reflexes, graded sensory loss for pain and temperature up to right mid-thigh and left calf level and impairment of vibration sensation of the right lower limb up to the hip level. MRI showed conspicuous intramedullary hyperintensity extending from D6 to the level of conus with associated flow voids on the dorsal surface of the cord (Fig 2A). The patient underwent spinal angiography under GA, which revealed a ventrally located perimedullary fistula at L5 level with arterial feeder from radiculomedullary branch of left L2 lumbar artery and venous drainage into perimedullary veins that extended cranially up to D11 level (Fig 2B and 2C).

A 6F renal guide catheter (RGC, Medtronic, Minneapolis, USA) was placed in the abdominal aorta and the left L2 lumbar artery selectively catheterized using a 4F Judkins left coronary catheter (Cordis, Warren, New Jersey, United States). After priming with 1 mg of Nimodipine bolus, the radiculomedullary artery was cannulated using a Marathon microcatheter and Mirage microguidewire (Covidien/Medtronic, Irvine, California, United States) and navigated under roadmap guidance to the fistulous site. After confirming the optimal position of microcatheter,

fistula was gradually embolized using squid 12 and the progression of embolization monitored under roadmap guidance and temporary apnea. Good antegrade percolation into the nidus and the proximal draining vein was noted with final angiogram revealing complete cessation of the shunt (Fig 2D). The patient showed significant improvement in his lower limb power (hip & knee 5/5, ankle 4+/5) and improvement in the sensory symptoms in the immediate post procedure period. Preprocedure modified Aminoff Logue score (Gait grade 3) improved to Gait grade 2 at three and six month clinical follow-up following embolization. The follow-up imaging at 6 months confirmed persistence of the occlusion.

Case 3

A 30-year-old male presented with insidious onset and gradually progressive weakness involving both lower limbs (left > right) for 10 months, followed by urinary hesitancy, one episode of urinary retention and constipation for 6 months. The clinical examination revealed asymmetric paraparesis (left > right), absent left sided knee and ankle reflexes, 70% loss of pain and temperature sensation (till D10 level) and impaired vibration sensation up to L1 level on left side. MRI showed conspicuous intramedullary hyperintensity extending from the T8 to conus level, with few associated flow voids along the surface of the cord (Fig 3A). The patient underwent spinal angiography under general anesthesia (GA), which revealed a ventrally located PMAVF at L5 (filum terminale) level with arterial feeder from a left T10 level radiculomedullary artery and venous drainage into perimedullary veins that finally egressed out through radicular veins into vertebral venous plexus (Fig 3B and 3C). Fistulous embolization was performed using squid 12 using the similar hardware and procedural techniques described for earlier cases and complete obliteration was achieved. His neurological status improved from modified Aminoff Logue score of gait grade 3, micturition grade 2 to gait grade 2 and Micturition grade 1 at three month follow-up post embolization. The follow-up MRA imaging at three months confirmed persistence of the occlusion.

DISCUSSION

The definitive treatment of PMAVFs is warranted in view of the progressive neurological decline. The spontaneous remission of PMAVF is documented, but it is extremely rare. The plausible explanation for spontaneous remission is selective catheterization of feeding artery, thrombogenic effect of contrast media administered during angiography or spontaneous thrombosis of draining veins.⁸ The presence of venous hypertension with congestive myelopathy,

mass effect due to large venous sacs, vascular steal, and hemorrhage are among the important factors considered responsible for patient symptoms, with the former being most common.^{11,12} The nonspecific nature of symptoms & non-consideration of this disease in the initial diagnostic differentials by most physicians, leads to misdiagnosis and a relatively longer incubation period to precise diagnosis. The bleeding manifestations are more common in high flow PMAVF, while progressive neurological deterioration is commonly seen in adults.^{1,11} Surgery, endovascular embolization or a combination of the two are the definite modes of treatment undertaken for most PMAVFs patients. Irrespective of the treatment modality used complete occlusion of the fistula and the proximal aspect of the draining vein is pivotal to achieve durable clinical outcome.¹³ Although surgical treatment has been the cornerstone of treatment in PMAVF, the modality is invasive and no less challenging, considering the difficulty in locating fistula intraoperatively due to congested veins and therefore the frequent need for intraoperative monitoring examinations such as near-infrared indocyanine green videoangiography, ultrasound or intraoperative DSA.^{13,14} Conventionally, the surgery is the preferred treatment modality and yield better results for type A and some of the type B PMAVF.⁹ Dorsally located fistula can be tackled easily by simple laminectomy, while PMAVFs in ventral location needs cord mobilization and can be technically challenging.^{15,16}

Due to the relatively larger size of the feeding arteries in type C and some type B PMAVFs, endovascular approach is usually considered the first-line treatment and various embolic materials such as n-BCA and coils are described to achieve fistula obliteration.^{9,17-19} A few isolated reports of successful embolization using EVOH based liquid embolic agent in subtype B and C PMAVF are also available recently.¹⁰ The near normal sized arterial feeder in type A PMAVF might preclude navigation of microcatheter and successful cannulation of the fistula, especially if the fistula is distally located.⁹ Embolization using n-BCA has been successfully reported in a few of the subtype A lesions. however, the effectiveness of EVOH based liquid embolic in these lesions is not documented (table 1). In a series of 9 patients, Phadke et al achieved technical success and complete obliteration in 55% of the patients using n-BCA, however inadvertent complications such as excess venous penetration or retrograde n-BCA reflux occurred in two of these patients, with latter complication resulting in disastrous consequences in one patient.⁹ N-BCA can present several challenges when it is used for

embolization of type IV a PMAVF. First, choosing the appropriate concentration that allows optimal percolation can be challenging and demands considerable operator experience in n-BCA usage. Second, n-BCA percolation is highly unpredictable; excessive venous penetration before fistula occlusion or low percolation with significant retrograde reflux into ASA, sulco-commisural arteries or dorsal perforators could potentially occur. Former may result in persistent venous congestion after embolization, while latter might cause cord infarction, leading to permanent neurological deficit. Third, due to small caliber of the artery, there is a potential concern of catheter entrapment if injection time is prolonged, and applying excess force to retrieve the catheter in such instances might result in avulsion of perforators or ASA with disastrous consequences. Due to the fear of catheter entrapment operator may terminate the procedure prematurely, thus resulting in incomplete occlusion.

Specific to type IV a lesion, we believe that liquid embolic agent such as onyx or squid is particularly advantageous in minimizing the complications associated with embolization and achieving fistulous occlusion. EVOH based liquid embolics is nonadhesive, and could be injected over a longer duration to achieve percolation into multiple afferent networks and the draining vein.²⁰ Controlled injections with intermittent pauses redirect the onyx into residual fistulous network and thus it could achieve complete obliteration of the fistula. There are however some important caveats that need to be considered to, prior or during embolization using liquid embolics. Artifacts due to bowel gas could severely hamper the visualization of progress of embolization, and this could be minimized by prior adequate bowel preparation and administration of hyoscine butylbromide. Also, breathing artifacts could pose challenge in monitoring the onyx percolation. The later was overcome in our cases by injections during temporary apnea. In order to minimize the reflux around the catheter tip, wedging of the microcatheter was attempted, so as to encourage forward percolation. Though reflux around the tip is generally encouraged in onyx embolization, it was specifically avoided in order to reduce difficulties during catheter retrieval. Also, in order to facilitate antegrade percolation, we used low viscous liquid embolic agent (squid 12) in all the cases. If there is no significant reflux, the catheter could be gradually withdrawn and thereby minimizing the trauma to the spinal arteries. Since the arterial feeder in type A PMAVF are usually near normal sized, catheterization of the artery could lead to spasm of the artery or stagnant flow and thrombosis. These complications

could be avoided by priming the feeder with Nimodipine bolus and rigorous systemic heparinization throughout the procedure.

We observed complete obliteration of the fistula with no morbidity or mortality in our small series of type IVa fistula using EVOH based liquid embolic agent. Being less invasive, endovascular option can be employed as the first line of treatment of these lesions where appropriate technical expertise is available. Despite the benefits, proximal reflux compromising spinal cord blood supply, catheter irretrievability, DMSO angiotoxicity and chances of vascular rupture during catheterization are still potential concerns during liquid EVOH embolization.^{21, 22} Due diligence to the endovascular technique and close monitoring of embolic material percolation is vital to avoid these complications. Surgery still plays an important role in the setting of unfavorable angiomorphology such as extreme tortuosity or very small caliber feeder, failed endovascular treatment or for dorsally located PMAVF, where shunt point could be accessed easily and safely by simple laminectomy.^{9,15,16} The present study is limited by small number and limited follow up. Long term follow-up and further large studies are needed to confirm these preliminary observations.

CONCLUSION

We report three cases of type A PMAVF successfully embolized using EVOH based liquid embolic agent. The occlusion remained durable and patients showed steady neurological improvement in the follow up period. These encouraging results support the extension of endovascular embolization using onyx or squid to subtype A PMAVF and obviates the concerns associated with embolization using n-BCA.

REFERENCES

1. Rodesch G, Hurth M, Alvarez H, Tadie M, Lasjaunias P: Spinal cord intradural arteriovenous fistulae: anatomic, clinical, and therapeutic considerations in a series of 32 consecutive patients seen between 1981 and 2000 with emphasis on endovascular therapy. *J Neurosurg* 2005; 57: 973-81

2. Djindjian M, Djindjian R, Rey A, Hurth M, Houdart R. Intradural extramedullary spinal arteriovenous malformations fed by the anterior spinal artery. *Surg Neurol* 1977; 8 (2): 85-93
3. Heros RC, Debrun GM, Ojemann RG, Lasjaunias PL, Naessens PJ : Direct spinal arteriovenous fistula: a new type of spinal AVM. *J Neurosurg* 1986 ; 64 (1): 134-9
4. Anson JA, Spetzler RF: Classification of spinal arteriovenous malformations and implications for treatment. *BNI Quarterly* 1992; 8:2-8.
5. Baltasvias G, Argyrakis N, Matis GK, Mpata-Tshibemba S: Spinal Arteriovenous Fistula with Progressive Paraplegia after Spinal Anaesthesia. *J Korean Neurosurg* 2014; Soc 55 :106-9.
6. Meng X, Zhang H, Chen Y and Ling F: Traumatic spinal perimedullary arteriovenous fistula: A case report. *Acta Neurochir (Wien)* 2010; 152: 1407-10.
7. Gross BA and Du R: Spinal pial (type IV) arteriovenous fistulae: A systematic pooled analysis of demographics, hemorrhage risk, and treatment results. *J Neurosurg* 2013; 73: 141-51.
8. Takai K and Usui M: Spontaneous thrombosis of a spinal conus perimedullary arteriovenous fistula. Case report. *Neurol Med Chir (Tokyo)* 2012 ; 52: 103-6.
9. Phadke RV, Bhattacharyya A , Handique A, Jain K, Kumar A, Singh V : Endovascular Treatment in Spinal Perimedullary Arteriovenous Fistula. *Interventional Neuroradiology* 2012 ; 20: 357-67.
10. Honarmand AR, Ansari SA, Soltanolkotabi M, Tomita T, Alden TD, Hurley MC, et al: Use of Onyx for endovascular embolization of pediatric spinal perimedullary (type IV) fistula: Case report. *Clin Neurol Neurosurg* 2013; 115: 2260-3.
11. Ricolfi F, Gobin PY, Aymard A, Brunelle F, Gaston A, Merland JJ : Giant perimedullary arteriovenous fistulas of the spine: clinical and radiologic features and endovascular treatment. *Am J Neuroradiol* 1997; 18 (4): 677-87.
12. Rodesch G, Hurth M, Alvarez H, Ducot B, Tadie M, Lasjaunias P : Angio-architecture of spinal cord arteriovenous shunts at presentation. Clinical correlations in adults and children. The Bicêtre experience on 155 consecutive patients seen between 1981-1999. *Acta Neurochir (Wien)* 2004 ; 146 (3): 217-27.

13. Mourier KL, Gobin YP, George B, Lot G, Merland IT : Intradural perimedullary arteriovenous fistulae: results of surgical and endovascular treatment in a series of 35 cases. *J Neurosurg* 1993; 32 (6): 885-91.
14. Horie N, So G, Debata A, Hayashi K, Morikawa M, Suyama K, et al : Intra-arterial indocyanine green angiography in the management of spinal arteriovenous fistulae: Technical case reports. *Spine* 2012; 37: E264-67.
15. Gekka M, Seki T, Hida K, Osanai T and Houkin K: Surgical management of combined intramedullary arteriovenous malformation and perimedullary arteriovenous fistula within the hybrid operating room after five years of performing focus fractionated radiotherapy: Case report. *Neurol Med Chir (Tokyo)* 2014; 54: 936-40.
16. Hida K, Iwasaki Y, Ushikoshi S, Fujimoto S, Seki T and Miyasaka K: Corpectomy: A direct approach to perimedullary arteriovenous fistulas of the anterior cervical spinal cord. *J Neurosurg* 2002; 96: 157-61.
17. Lv X, Li Y, Yang X, Jiang C, Wu Z: Endovascular embolization for symptomatic perimedullary AVF and intramedullary AVM: A series and a literature review. *Neuroradiol* 2012; 54: 349-59.
18. Oran I, Parildar M, Derbent A : Treatment of slow-flow (type I) perimedullary spinal arteriovenous fistulas with special reference to embolization. *Am J Neuroradiol* 2005 ; 26 (10) : 2582-6.
19. Pasqualetto L, Papa R, Isalberti M, Nuzzi NP, Branca V: The endovascular treatment of a spinal perimedullary arteriovenous fistula with coils: A case report. *J Neurointerv Surg* 2011; 3: 88-91.
20. Gore P, Theodore N, Brasiliense L, Kim LJ, Garrett M, Nakaji P, et al : The utility of onyx for preoperative embolization of cranial and spinal tumors. *J Neurosurg* 2008; 62(6):1204-11.
21. Antonietti L, Sheth SA, Halbach VV, Higashida RT, Dowd CF, Lawton MT, et al : Long-term outcome in the repair of spinal cord perimedullary arteriovenous fistulas. *Am J Neuroradiol* 2010; 31: 1824-30.
22. Ashour R, Aziz-Sultan MA, Soltanolkotabi M, Schoeneman SE, Alden TD, Hurley MC, et al : Safety and efficacy of onyx embolization for pediatric cranial and spinal vascular lesions and tumors. *J Neurosurg* 2012; 71:773–84.

LEGENDS

Fig. 1. Pre-embolization sagittal T2 weighted MR image shows conspicuous intramedullary hyperintensity extending from T7 to conus level. Spinal angiography (B,C) reveals a perimedullary fistula with arterial feeder from radiculomedullary branch of left T9 intercostal artery (*) and the fistula at L2 vertebral body level (arrow in C). Draining vein is more conspicuous (double arrow) on microcather injection (C). The post embolization angiogram shows complete obliteration of the fistula (D).

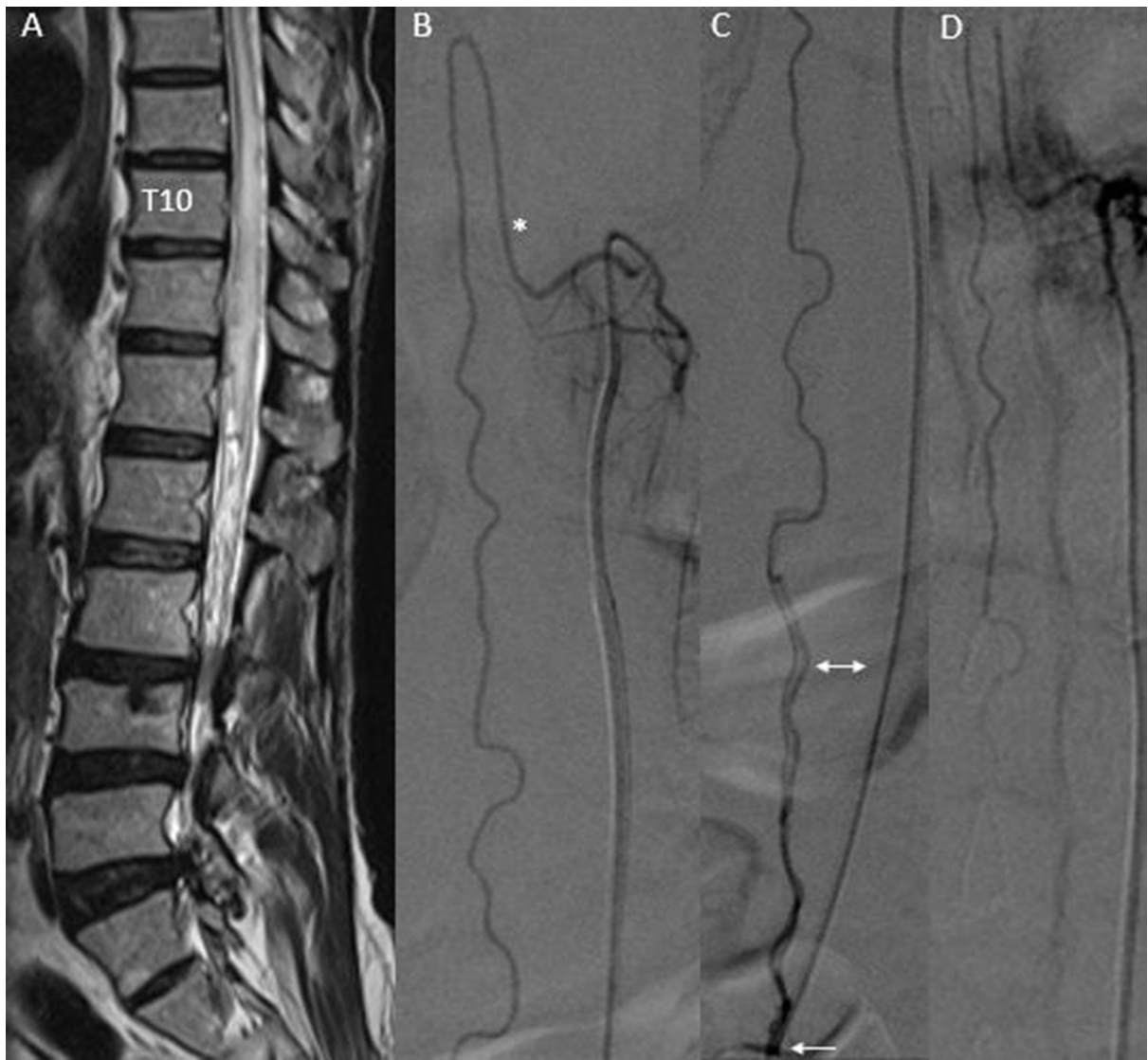Fig. 2. Pre-embolization sagittal T2 weighted MR image (A) shows intramedullary hyperintensity extending from T6 to conus level with associated flow voids on the dorsal surface of cord. Spinal angiography (B) reveals a perimedullary fistula at L5 vertebral body level (arrow) with arterial feeder noted from radiculomedullary branch of left L2 lumbar artery (*) and drainage into perimedullary vein (double arrow, C). The post-embolization angiogram shows exclusion of the fistula (D).

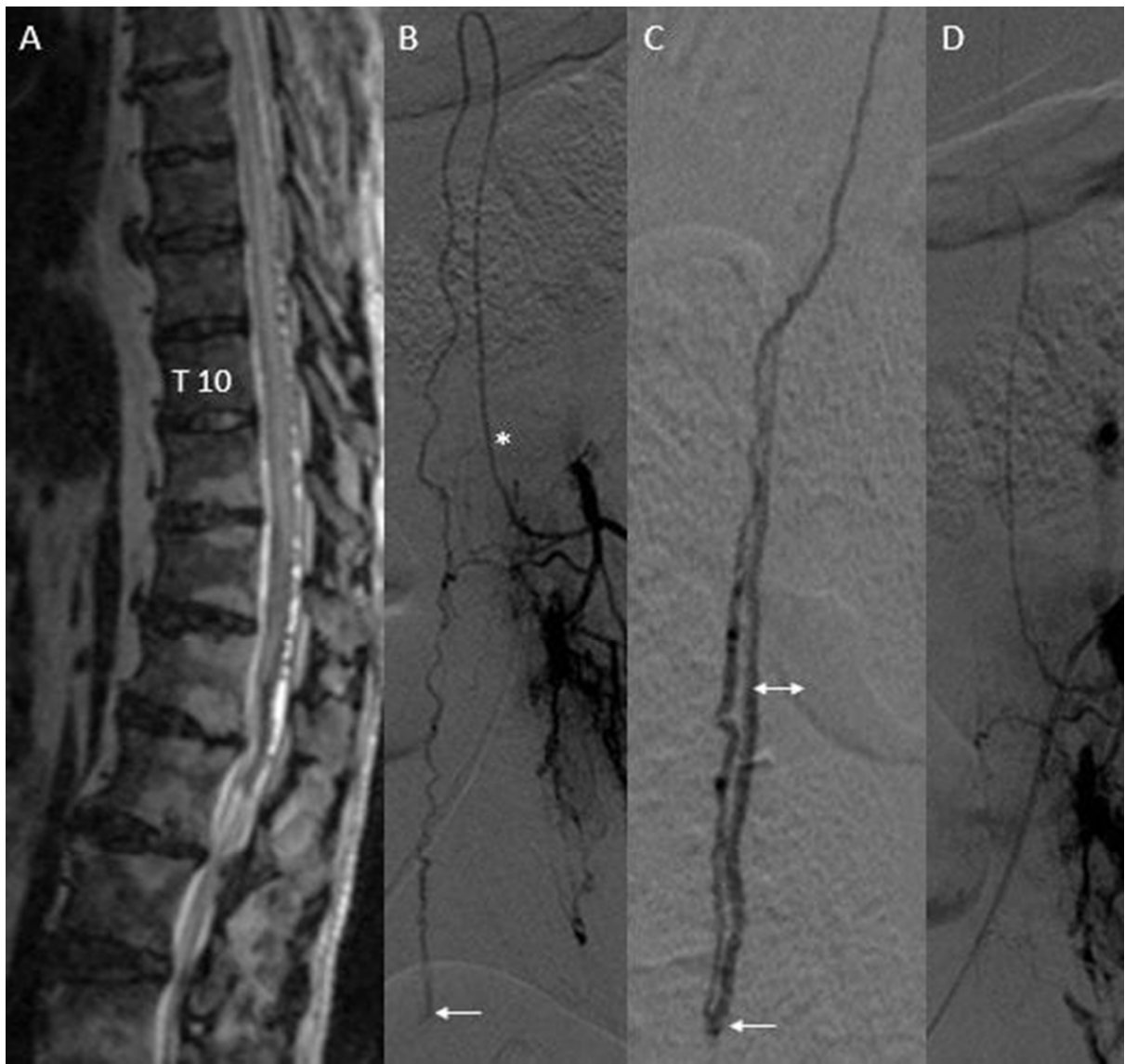Fig. 3. Pre-embolization sagittal T2 weighted MR image (A) shows conspicuous intramedullary hyperintensity extending from T8 to conus level with associated flow voids in the ventral and dorsal spinal subarachnoid spaces. Spinal angiography (B, C) shows a tortuous small caliber arterial feeder from radiculomedullary branch of left T10 artery (arrow in B). Microcatheter angiogram (C) depicts the fistula location at L5 vertebral body level (double arrow), draining into two perimedullary veins (*). Check angiogram shows complete obliteration of the fistula (D).

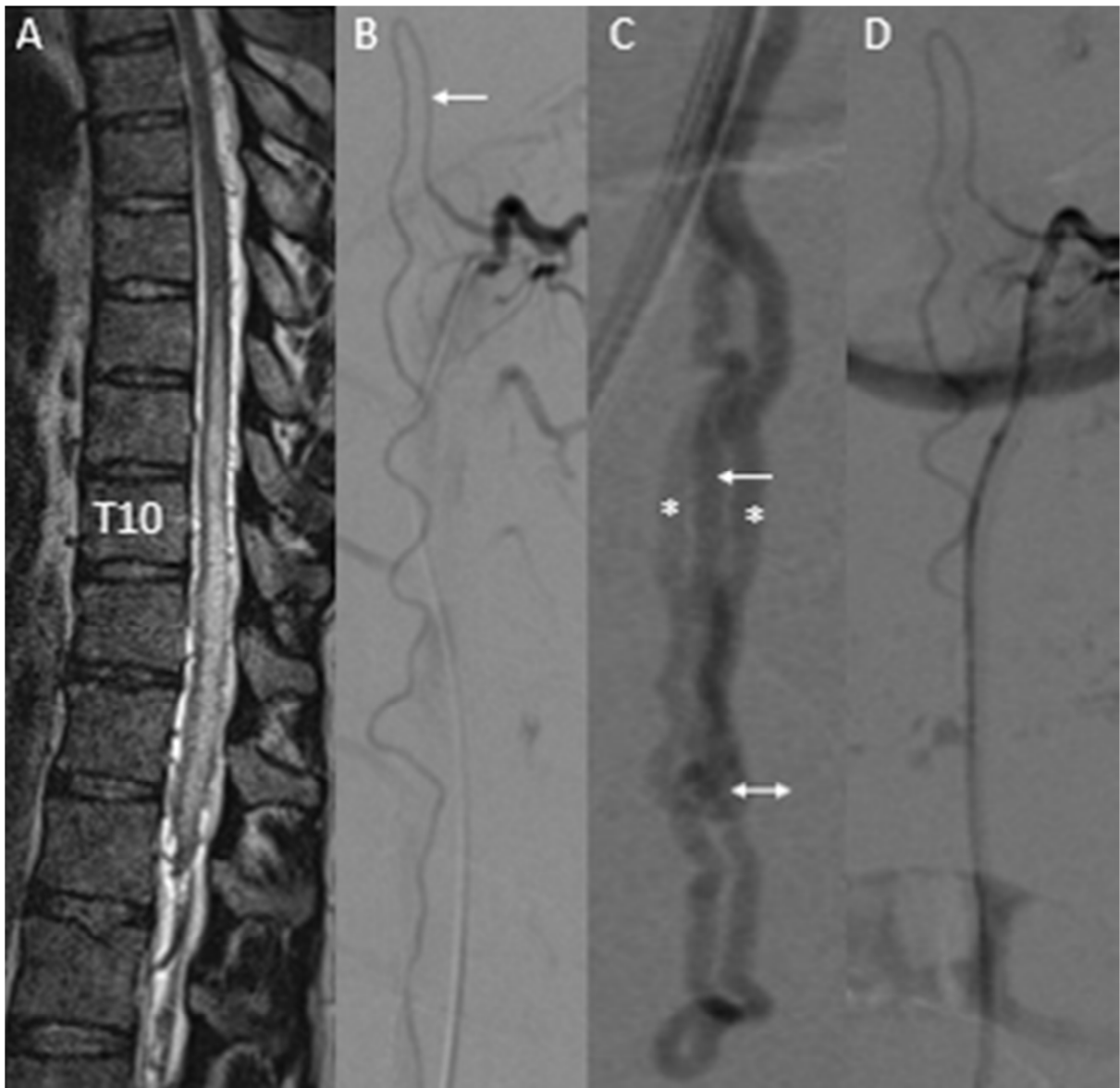
TABLES

Study	Number	Embolic agent	Complete Obliteration	Complications	Remarks
Phadke et al ⁹	9	nBCA (glue)	55.5%	Neurological deterioration in 1 due to glue reflux into ASA Excess perimedullary venous migration in 1 (No neurological deterioration)	Surgical referral anticipating difficult microcatheterization (n=2) and following unsuccessful microcatheterization (n=2)
Oran et al ¹⁸	5	nBCA (glue)	80%	Nil	Surgical referral anticipating difficult microcatheterization (n=1)
Present study)	3	EVOH (squid)	100%	Nil	Technical success in all patients with no complications

Table-1: Prior studies pertaining to endovascular management of spinal type A perimedullary fistula.







ACCEPTED

Highlights:

- Near normal sized arterial feeder in spinal perimedullary fistulas (PMAVFs) can pose technical challenge to endovascular treatment
- Safe, atraumatic catheterisation of the feeder and access to the nidus is possible with modern hardware and liquid embolic agent such as onyx or squid can effectively obliterate the fistula.
- Low viscous liquid embolics permit forward percolation, while minimizing catheter reflux and hence might be ideally suited in type A PMAVF.
- Respiratory and bowel movement artefacts can impair visualization of embolization and adequate preparation is vital to avoid inadvertent complications.
- Encouraging results from our small series support the extension of endovascular embolization using onyx or squid to subtype A PMAVF and obviates the concerns associated with embolization using n-BCA.

Abbreviations list :

PMAVFs: Perimedullary arteriovenous fistulas

nBCA : n-butyl-2-cyanoacrylate

DSA : Digital Subtraction angiography

ASA : Anterior spinal artery

EVOH: ethylene vinyl alcohol copolymer

DMSO : dimethyl-sulfoxide