



## Delayed onset dancing hand syndrome following thalamic hemorrhage

Sanjeev Kumar Bhoi<sup>1</sup> · Suprava Naik<sup>2</sup> · Menka Jha<sup>1</sup> · Lorika Sahu<sup>1</sup>

Received: 11 June 2018 / Accepted: 21 August 2018  
© Springer-Verlag Italia S.r.l., part of Springer Nature 2018

Dear Editor,

Unilateral chorea or hemichorea is a form of hyperkinetic movement disorder. It is usually associated with vascular causes, such as cerebral infarctions, arteriovenous malformations, and subdural hematomas [1]. These movements usually occur within the first week of strategic stroke when the patient starts recovering from the acute stroke. Delayed onset occurrence of hemichorea has not been described. In this communication, we report a case of hemichorea which developed after 7 months of thalamic hemorrhage and its management.

A 53-year-old female presented to our department with history of involuntary movement of right upper limb of 1-month duration. The movement was sudden in onset, non progressive, low amplitude, coarse in nature, typically involving distal part of right upper limb. It was persisting throughout the day, more prominent during activity and disappeared during sleep. There was associated twitching movement of right angle of jaw. She is a known hypertensive from 8 months; hypertension was detected when she developed acute onset right hemiplegia, medical research scale (MRC) grade 2/5. Non-contrast CT scan at that time demonstrated acute left thalamic hemorrhage with intraventricular extension (Fig. 1). Her motor power improved to MRC grade 4/5 in the next 2 months and was independent on activity of daily living with residual mild spasticity and post stroke pain, visual analogue scale 5/10. She had history of right Bell's palsy 20 years before without residual deficit. Family history was not significant.

On examination, blood pressure was 130/90 mm Hg, vitals were normal, she was conscious and oriented, and speech was spastic. Motor examination revealed hypertonia and hyperreflexia of right limbs. Right hand grip was 80% of normal; power was MRC grade 4/5 on right side with no new motor deficit. Gait and sensory examination was normal. There was an irregular, coarse, continuous, nonsuppressible, quasi-purposive involuntary movement that was more prominent on action involving the right hand and forearm which were suggestive of right hemichorea (HC) (video 1).

In view of new-onset hyperkinetic movement (HC) on right half without new focal motor deficit in a patient of 8 months old left thalamic hemorrhage possibility of post stroke seizure or new-onset lacunar stroke was considered. Video EEG did not reveal any seizure activity corresponding to site of HC. Magnetic resonance imaging of brain (Fig. 1) showed an irregular T2 hyperintense lesion in the left thalamus with a hypointense rim likely to be due to hemosiderin deposition. The lesion was showing blooming in susceptibility-weighted image suggesting the presence of blood degradation products. The same area shows hypoperfusion in perfusion map. No new lesion was seen on diffusion-weighted MRI to suggest acute infarct. The lesion was hypointense on T1WI without obvious post contrast enhancement. No evidence of mass effect noted on adjacent brain parenchyma. MR angiogram was normal. Routine hemogram; liver, renal, and thyroid function tests; and lipid profile were normal. Fasting and postprandial blood glucose were normal, serum sodium was 134 meq/L, glycosylated hemoglobin was 6.5. ECG, and 2D echocardiography was normal. Serological testing for HIV, HBsAg, HCV, and VDRL was negative. ESR was normal; serum antinuclear antibodies were negative. She was started on tetrabenazine (25 mg) twice daily and her antihypertensive medication was continued. There was improvement in his involuntary movements and was discharged on day 5 (video 2). On 1-month follow-up, her hemichorea subsided.

Our patient demonstrated late-onset occurrence of hemichorea after 7 months of thalamic hemorrhage. Unilateral choreiform movements are called hemichorea, which accounts for

---

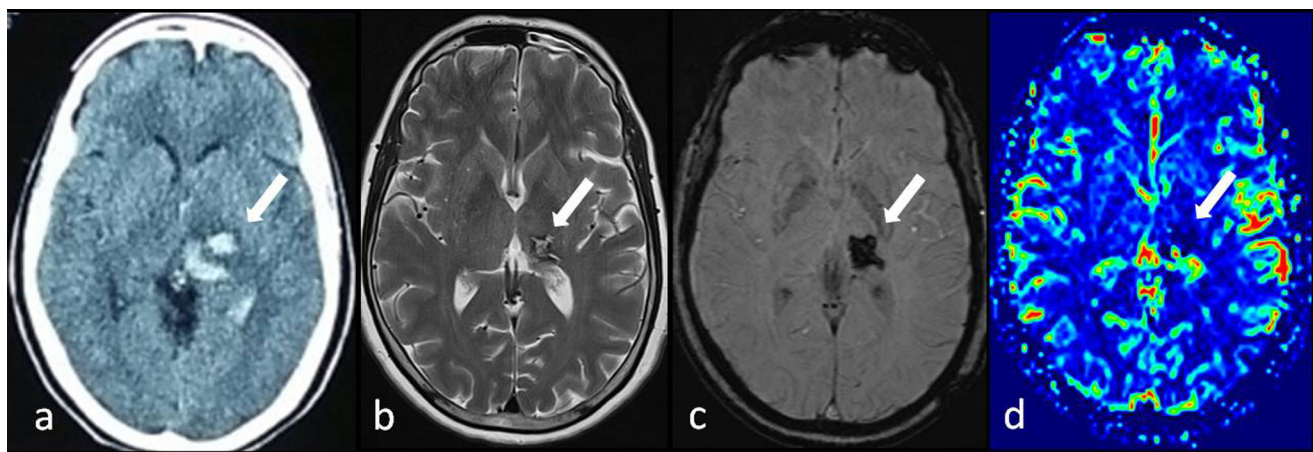
**Electronic supplementary material** The online version of this article (<https://doi.org/10.1007/s10072-018-3549-1>) contains supplementary material, which is available to authorized users.

---

✉ Sanjeev Kumar Bhoi  
sanjeev\_bhoi@rediffmail.com

<sup>1</sup> Department of Neurology, All India Institute of Medical Sciences, Bhubaneswar, Odisha 751019, India

<sup>2</sup> Department of Radiodiagnosis, All India Institute of Medical Sciences, Bhubaneswar, Odisha 751019, India



**Fig. 1** Axial section of cranial CT scan (a) shows acute left thalamic hemorrhage with intraventricular extension. Axial T2W MRI (b) of brain shows irregular T2 hyperintense lesion with a hypointense rim in

the left thalamus. Blooming noted in the lesion on susceptibility-weighted image (SWI) (c). Perfusion-weighted image (d) shows hypoperfusion in the lesion compared to rest of the brain parenchyma

approximately 0.7% of all movement disorders [1]. These are the most common cause of sporadic chorea in the hospital population and present in older patients; average age is 74.5 years [2, 3]. They are usually associated with a structural pathology such as contralateral vascular lesion, tumor, or tuberculoma or sometimes with metabolic derangements like hyperosmolar non-ketotic state and diabetic ketoacidosis. Hemichorea-hemiballismus (HC-HB) usually develops in acute period of stroke. HC-HB develops early, mean 4.3 days post-stroke, and Parkinsonism develops later mean 117.5 days post stroke [3]. In a study of 1500 patients of stroke, 56 developed involuntary abnormal movements and 20 (35.7%) patients developed chorea which was the commonest hyperkinetic disorder. Only 3 patients had hemorrhagic lesion, 2 in basal ganglia thalamic lesion and 1 patient in bilateral thalami lesion [3]. The delay between the stroke and the onset of the abnormal movement may reflect time required for the partial recovery of motor function and development of pathological circuitry [4]. Our patient developed HC after 7 months of thalamic hemorrhage when her motor power improved and associated post stroke pain on hemiparetic side.

Although the precise pathophysiology process in post stroke HC is not yet fully elucidated, disruptions in the crosstalk between the inhibitory and excitatory circuits resulting from vascular insult are proposed to be the underlying cause. Thalamic lesion and subthalamic lesion disrupt the various thalamic connecting fibers from the subthalamic nucleus (STN), globus pallidus, posterior limb of internal capsule, and cerebellum, leading to the crucial derangement in the basal ganglia cortical circuit [4, 5]. Single-photon emission computed tomography study revealed contralateral thalamic hypoperfusion and striatal hyperperfusion. Striatal hyperperfusion suggested increase in the striatal neuronal inhibitory activity on globus pallidus internus (GPI), thus causing

disinhibition of the thalamic neurons [5]. In our patient, there is hypoperfusion of corresponding thalamus in MR perfusion. Dopamine receptor blockers are the main stay of treatment in disabling HC-HB. Majority of these patients responds to dopamine receptor blocker. Patients with cortical lesions have better functional outcome than those with subthalamic lesion because hemichorea in cortical lesions may be caused by transient hypoperfusion or functional disconnection rather than actual destruction of the basal ganglia-thalamocortical circuitry [2].

The present case reports the relatively rare occurrence of hemichorea which developed as a delayed complication of thalamic hemorrhage. Understanding the pathophysiological mechanism responsible for the late occurrence HC-HB following thalamic hemorrhage needs further research.

**Acknowledgements** We thank Mr. Divendu Deewan for neurophysiological studies and secretarial help.

### Compliance with ethical standards

**Informed consent** Informed consent was obtained from the patient included in the study. “Additional informed consent was obtained from the patient for whom identifying information is included in this article.”

**Conflict of interest** The authors declare that they have no conflict of interest.

**Research involving human participants and or animals** For this type of study (case report), formal consent is not required.

### References

- Suchowersky O, Muthipeedika J (2005) A case of late-onset chorea. *Nat Clin Pract Neurol* 1(2):113–116

2. Chung SJ, Im JH, Lee MC, Kim JS (2004) Hemichorea after stroke: clinical-radiological correlation. *J Neurol* 251(6):725–729
3. Alarcon F, Zijlmans JC, Duenas G, Cevallos N (2004) Post-stroke movement disorders: report of 56 patients. *J Neurol Neurosurg Psychiatry* 75(11):1568–1574
4. Kim JS (2001) Delayed onset mixed involuntary movements after thalamic stroke. Clinical, radiological and pathophysiological findings. *Brain* 124(Pt 2):299–309
5. Kim JS, Lee KS, Lee KH, Kim YI, Kim BS, Chung YA, Chung SK (2002) Evidence of thalamic disinhibition in patients with hemichorea: semiquantitative analysis using SPECT. *J Neurol Neurosurg Psychiatry* 72(3):329–333