


Accepted Manuscript

Isolated Oculomotor and Abducens Nerves Palsies as Initial Presentation of Cavernous Sinus Tuberculoma: Case Report and Literature Review

Hesam Abdolhoseinpour, Soheila Abolghasemi, Ehsan Jangholi, Khadijeh Haji Naghi Tehrani



PII: S1878-8750(18)31419-0

DOI: [10.1016/j.wneu.2018.06.203](https://doi.org/10.1016/j.wneu.2018.06.203)

Reference: WNEU 8516

To appear in: *World Neurosurgery*

Received Date: 5 May 2018

Revised Date: 22 June 2018

Accepted Date: 23 June 2018

Please cite this article as: Abdolhoseinpour H, Abolghasemi S, Jangholi E, Naghi Tehrani KH, Isolated Oculomotor and Abducens Nerves Palsies as Initial Presentation of Cavernous Sinus Tuberculoma: Case Report and Literature Review, *World Neurosurgery* (2018), doi: 10.1016/j.wneu.2018.06.203.

This is a PDF file of an unedited manuscript that has been accepted for publication. As a service to our customers we are providing this early version of the manuscript. The manuscript will undergo copyediting, typesetting, and review of the resulting proof before it is published in its final form. Please note that during the production process errors may be discovered which could affect the content, and all legal disclaimers that apply to the journal pertain.

Isolated Oculomotor and Abducens Nerves Palsies as Initial Presentation of Cavernous Sinus Tuberculoma: Case Report and Literature Review

Hesam Abdolhoseinpour¹, Soheila Abolghasemi², Ehsan Jangholi^{3,4}, Khadijeh Haji Naghi Tehrani^{5*}

1. Department of Neurosurgery, Bou Ali Hospital, Tehran Medical Sciences Branch, Islamic Azad University, Tehran, Iran

2. Department of Infectious Diseases, Tehran Medical Sciences Branch, Islamic Azad University, Tehran, Iran

3. Young Researchers and Elite Club, Tehran Medical Sciences Branch, Islamic Azad University, Tehran, Iran

4. Clinical Research Development Center, Amir-almomenin Hospital, Tehran Medical Sciences Branch, Islamic Azad University, Tehran, Iran

5. Department of Neurology, Tehran Medical Sciences Branch, Islamic Azad University, Tehran, Iran

Corresponding Author: Khadijeh Haji Naghi Tehrani

Mailing address: Medical Research Center, Azad University, Tehran Medical Branch, Attarimoqaddam Ave, Haqani Ave, Dr. Shariati St, Tehran, Iran, P. O. BOX: 19395-1495, Tehran, Iran

Tel: +9821-22006660

Fax: +9821-22846593

Email: dr_tehrani10@yahoo.com

Isolated Oculomotor and Abducens Nerves Palsies as Initial Presentation of Cavernous Sinus Tuberculoma: Case Report and Literature Review

Abstract

Introduction: Central nervous system (CNS) tuberculoma is the most severe manifestation of extrapulmonary tuberculosis, which caused high mortality. Cavernous sinus tuberculomas (CSTs) is a very rare presentation of CNS that few cases were reported in the literature.

Case Report: We reported a 57- years-old woman who was admitted to our clinic with acute diplopia and headache limited to the right side. There was no any specific medical history expect migraine, depression, and anxiety, which controlled by oral medications. Physical examination revealed ptosis, mydriasis on the right eye that indicated right third and sixth cranial nerves palsies. Pituitary magnetic resonance imaging (MRI) showed right parasellar lesion at cavernous sinus wall and ophthalmic nerve. However, laboratory examinations and brain computed tomography (CT) scan showed negative findings. Initial differential diagnosis includes meningioma, sarcoidosis, tuberculoma, and lymphoma. However, results of more studies include blood and cerebrospinal fluid culture even *Mycobacterium tuberculosis* DNA assay were negative. She underwent biopsy of the cerebral lesion through the subfrontal approach, and the histopathological study confirmed CST. Finally, she treated by standard antituberculous regimen, and after 12 months' follow-up, no any cerebral and clinical findings were seen.

Conclusions: CST was a rare presentation of *M. tuberculosis*, and its diagnosis is a difficult challenge. However, accurate diagnosis and timely treatment of CST in the suspected patients could prove complete cure.

Keywords: Tuberculoma; *Mycobacterium tuberculosis*; Central nervous system; Abducens; Cavernous Sinus

Abbreviations and Acronyms:

TB: Tuberculosis

CST: Cavernous sinus tuberculomas

CT: Computed tomography

MRI: Magnetic resonance imaging

CS: Cavernous sinus

CSF: Cerebrospinal fluid

CNS: Central nervous system

Introduction

Tuberculosis (TB) is a multi-systemic infectious disease that caused by various species of mycobacteria, typically *Mycobacterium tuberculosis* in humans.¹ An unusual incidence of TB in different parts of the body is called tuberculomas. Although TB of the nervous system may be involved both central and peripheral nerves, tuberculomas are most often located in the cerebral hemispheres.^{2,3} Indeed, cavernous sinus tuberculomas (CSTs) are an extremely rare presentation. To the best of our knowledge, only 17 cases of CST have previously been reported in the literature.¹⁻¹⁷ Hence, in this report, we present the first Iranian case of CST that presented with isolated third and sixth cranial nerves palsies.

Case Presentation

A 57- years-old woman was admitted to our neurology clinic (Bou-Ali Hospital, Tehran) with the complaints of acute diplopia and headache limited to the right side of the head. Her medical history was included migraine, depression, anxiety for two years ago, and bilateral cataract surgery (for about four years). Hence, her medications that started 24 months prior were sodium valproate (500 mg daily), aspirin (80 mg daily), perphenazine (2 mg daily), alprazolam (0.5 mg daily) and nortriptyline (25 mg BID). There was no any specific pathological history including TB, and there was no history of exposure to TB. Neurological examinations showed ptosis, mydriasis and 10/10 visual acuity on the right eye that indicated right third and sixth nerves palsies. Also, bilateral eyes fundoscopy revealed normal optic disc without any vessels deficit. There were no additional findings on physical and laboratory examinations of the patient.

The brain computed tomography (CT) scan showed no abnormality (Figure-1). Pituitary magnetic resonance imaging (MRI) revealed a right parasellar lesion which occupied right cavernous sinus (CS) wall and the mild enlargement of the pituitary gland; the lesion was isointense on both T1- and T2-weighted sequences (Figure-2A and B). It enhanced homogeneously after intravenous (IV) gadolinium administration (Figure-2C). She underwent carotid Doppler ultrasonography that no any abnormal findings were reported. Brain MRA demonstrated normal sagittal sinus, strio-thalamic vein, internal cerebral veins, and vein of Galen that rolled out the CS thrombosis.

Regarding the differential diagnosis, i.e., meningioma, sarcoidosis, tuberculoma, and lymphoma, further studies (include blood and cerebrospinal fluid [CSF] culture, PPD skin test, chest x-ray, polymerase chain reaction [PCR], and *M. tuberculosis* DNA assay) were performed, and their results were negative. Consequently, she underwent craniotomy and a biopsy of the CS wall and dura lesion through subfrontal approach. In the macroscopy view, a small, round shape, and yellowish mass was removed. Subsequently, pathological examination following the surgery confirmed CST (Figure-3)

Anti-TB treatment was begun immediately with a four-drug regimen (rifampin, isoniazid, ethambutol, and pyrazinamide) for two months followed by a two-drug regimen (rifampin and isoniazid) for ten months, and dexamethasone for the first eight weeks.

The postoperative course was uneventful with no surgical morbidity and clinical improvement in the weeks after that. The 1-year postoperative follow-up MRI showed complete regression of the lesion (Figure-4) and complete resolution of the symptoms.

Discussion

TB is still a leading cause of death among the infectious diseases. Central nervous system (CNS) tuberculoma is the fifth most frequent and severe manifestation of extrapulmonary TB diseases.³ CST, as the rare presentation of TB, accounts for between 10-30% of cases of CNS disease, though the reported frequency was varied.^{9,13} Despite the propensity to affect the hemispheres, unusual locations of CNS tuberculoma continue to be reported; including the cerebellopontine angle, the sellar and suprasellar regions, concurrent multiple intracranial and intramedullary conus tuberculoma, and as in our case, the CS.^{14,15} Intracranial tuberculomas can be solitary or multiple. Solitary lesions pose a diagnostic challenge as they can be indistinguishable from abscess or tumor.⁴

Symptoms include headaches, seizures, ocular nerve palsy, hydrocephalus, cerebral arterial involvement, and focal ischemia.⁹ However, headache and ocular involvement are the most initial presentations of CST that are consistent with our case.²⁻¹⁵

MRI have a highly sensitive but low specificity for the diagnosis of CST. T1-weighted images show an area of hypo- or iso-intensity that revealing dural thickening and pachymeningeal contrast enhancement involving the CS, and T2-weighted images show a hypo- or iso-intense tumor with perilesional edema.^{7,9,10} Also, CT scans of a tuberculoma provide an iso – to – hyperdense lesion with varying contrast enhancement pattern.⁹

The diagnosis of CST could be difficult due to various clinical manifestations, no history of TB, nonspecific laboratory, and chest radiographic findings. Even tuberculous bacilli are not always present in the CSF. Molecular techniques, e.g., PCR may also have an important role in diagnosis;^{9,10} however; this test was not diagnostic in our case. For a definitive diagnosis, take a tissue specimen is mandatory for bacteriologic and histopathologic evaluations.

However, according to the literature, bacteriological examinations are positive in only 25% of CSF samples and 35% of tuberculoma tissue specimens, and results may take from 10 days to eight weeks. Consequently, negative bacteriological findings do not ruled out a diagnosis of tuberculomas.^{1,13,14} To the best of our knowledge, our patient was the first case of CST that tuberculous bacilli were absent, and cultures from the excised lesion were negative. Indeed, in contrast with the previous reports, there was no any evidence of extrapulmonary involvement. Also, results of culture for *M. tuberculosis* even in the CSF and the brain lesion were negative. The summary of previously published reports of CST are presented in Table1.

Hence, in a majority of cases of CNS tuberculomas, the diagnosis was reached only after surgical biopsy of the lesion, often due to suspicion of meningioma.^{1,10-13} Indeed, when the diagnosis is not conclusive, a tissue biopsy is recommended to rule out other differential diagnoses (most often include meningiomas, lymphomas, metastases, and inflammatory diseases, for CS location). According to reported cases, timely treatment can prevent not only the progression of the disease but also a complete remission of the symptoms of the patient was expected.

Conclusion

Our report indicated that CSTs is a very rare presentation of brain TB; however, regarding the ability of tuberculoma to mimic a brain neoplasm, makes tuberculomas an always suspected in the differential diagnosis. While diagnosis is difficult and often delayed, a careful search for extracranial sites of disease can lead to earlier and safer histopathological confirmation. Anti-TB therapy is effective in these cases, and adjunctive steroids are frequently included, but long-term clinical and radiological follow-up examinations are essential to securing a good outcome.

Conflict of interest statement

The authors declare that the article content was composed in the absence of any commercial or financial relationships that could be construed as a potential conflict of interest.

References

1. Morris JT, Joyce MP. Central nervous system tuberculoma presenting as a cavernous sinus tumor. *Clin Infect Dis*. 1992;15:181–182.
<https://doi.org/10.1093/clinids/15.1.181>
2. Phookan G, Towns GM. Tuberculoma of the cavernous sinus – a case report. *Br J Neurosurg*. 1995;9:205–207.
<https://doi.org/10.1080/02688699550041566>
3. Bafna S, Lee AG. Presumed tuberculosis presenting as a cavernous sinus syndrome. *J Neuroophthalmol*. 1997;17:207–208.
<https://doi.org/10.1097/00041327-199709000-00014>

PMid:9304538

4. Grayeli AB, Redondo A, Salama J, Rey A. Tuberculoma of the cavernous sinus: case report. *Neurosurgery*. 1998;42:179–181.

<https://doi.org/10.1097/00006123-199801000-00040>

PMid:9442521

5. Goel A, Nadkarni T, Desai A.P. Tuberculoma in the Meckel's cave: a case report. *Neurol India*. 1999;47(3):238–240.

PMid:10514587

6. Al Soub H, Al Alousi FS, Al-Khal AL. Tuberculoma of the cavernous sinus. *Scan J Infec Dis*. 2001;33:868–870.

<https://doi.org/10.1080/00365540110027268>

7. Rebai R, Boudawara MZ, Bahloul K, Chabchoub I, Chaari S, Boudawara T. Cavernous sinus tuberculoma: diagnostic difficulties in a personal case. *Surg Neurol*. 2001;55:372–375.

[https://doi.org/10.1016/S0090-3019\(01\)00474-8](https://doi.org/10.1016/S0090-3019(01)00474-8)

8. Hui AC, Wong WS, Wong KS. Cavernous sinus syndrome secondary to tuberculous meningitis. *Eur Neurol*. 2002;47:125–126.

<https://doi.org/10.1159/000047966>

PMid:11844904

9. Yanardag H, Uygun S, Yumuk V, Caner M, Canbaz B. Cerebral tuberculosis mimicking intracranial tumour. *Singapore Med J*. 2005;46:731–733.

PMid:16308650

10. Kesavadas C, Somasundaram S, Rao RM, Radhakrishnan VV. Meckel's cave tuberculoma with unusual infratemporal extension. *J Neuroimaging*. 2007;17:264–268.

<https://doi.org/10.1111/j.1552-6569.2007.00095.x>

PMid:17608916

11. Boutarbouch M, Arkha Y, Gana R, El Maquili MR, Bellakhdar F. Tuberculoma of the cavernous sinus mimicking a meningioma: case report and review of the literature. *J Neurol Sci.* 2009;278:123–126.

<https://doi.org/10.1016/j.jns.2008.11.022>

PMid:19126443

12. Jaimovich SG, Thea VC, Guevara M, Gardella JL. Cavernous sinus tuberculoma mimicking a neoplasm: case report, literature review, and diagnostic and treatment suggestions for tuberculomas in rare locations. *Surg Neurol Int.* 2013;4:158.

<https://doi.org/10.4103/2152-7806.123203>

PMid:24381801 PMCID:PMC3872644

13. Kumar VR, Madhugiri VS, Verma SK, Barathi SD, Yadav AK, Bidkar P. Tuberculoma of the Cavernous Sinus and Meckel's Cave in a Child. *Pediatr Neurosurg.* 2013;49(6):369-73.

PMid:25428440

14. Haque MR, Chowdhury FH, Islam MS, Kawsar KA, Haque AM. Tuberculomas in the cavernous sinus, temporal lobe and basal subarachnoid spaces. *Journal of Medicine.* 2012;13(1):75-6.

<https://doi.org/10.3329/jom.v13i1.10056>

15. Kapadia S, Patrawalla A. Extrapulmonary tuberculosis presenting as a cavernous sinus syndrome: Case report with review of existing literature. *IDCases.* 2014;1(4):97-100.

<https://doi.org/10.1016/j.idcr.2014.10.010>

PMid:26839786 PMCID:PMC4735080

16. Intusoma U, Anuntaseree W, Pruekprasert P, Janjindamai S, Vasiknanonte P. First case report of cavernous sinus tuberculoma in a child. *Journal of Pediatric Neurology.* 2007;5(2):157-60.

17. Konar MC, Ghosh T. Tuberculoma of Cavernous Sinus-An Atypical Presentation of Neurotuberculosis with Review of Existing Literature. *Med Sci*. 2016;5(11):85-8.

18. Gasparetto EL, Tazoniero P, Carvalho Neto Ad. Disseminated tuberculosis in a pregnant woman presenting with numerous brain tuberculomas: case report. *Arquivos de neuro-psiquiatria*. 2003;61(3B):855-8.

<https://doi.org/10.1590/S0004-282X2003000500028>

PMid:14595496

19. Ogunrin A, Adeyekun A. Multiple intracranial tuberculomas in an HIV-negative 28 year old male-a case report. *Nigerian journal of clinical practice*. 2007;10(3):262-5.

PMid:18072459

20. Sakuma R, Jin K, Nagai M, Kinpara T, Shiga Y, Fujihara K, et al. A case of multiple intracranial tuberculoma diagnosed by open brain biopsy. *Rinsho shinkeigaku= Clinical neurology*. 1997;37(10):895-9.

Table 1: Summary of previous CST reports in existing literature

Author (s)	Age, y	Gender	Initial presentations	Pulmonary involvement	Extrapulmonary involvement	Diagnostic approaches	AFB Smear	Blood culture	Treatment protocol	Outcome
Morris et al. [1]	42	F	Orbital pain, ptosis, facial numbness, vision blurred	Neg	Neg	Operative removal revealing granulomas	Pos	Neg	HRZ+ Pyridoxine	Complete resolution of eye deficits, continued CN VII palsy
Phookan et al. [2]	33	M	Headache, orbital pain, diplopia, facial pain, ptosis, ophthalmoplegia	Neg	Neg	Operative removal revealing granulomas	Pos	not mentioned	HRZE + Pyridoxine	Improved eye deficit at 2yrs but not resolved
Bafna et al. [3]	65	F	Periorbital pain, ptosis, ophthalmoplegia on right	Neg	Pos (cervical LN)	Cervical LN biopsy	Pos	Pos	HRZE + Methylprednisolone	Partial improvement of ptosis and motility at 6 wks, imaging improvement
Grayeli et al. [4]	48	M	Headache, orbital pain, left eye ptosis, left upward and medial gaze deficit. hemifacial hypesthesia	Pos	Pos (apical macronodular hypodensities)	Operative removal revealing granuloma, CXR with sequelae of old TB	Pos	Pos	HRE	Complete resolution with improved imaging
Goel et al. [5]	35	F	Headache, left facial paresthesia, left gaze diplopia, wasting of temporalis & masseter on the left, left CN V & VI deficit	Neg	Neg	Operative removal revealing tuberculoma	Pos	not mentioned	ATD for 18 mos	Complete resolution with improved imaging
Al Soub et al. [6]	44	M	Headache, periorbital pain, ptosis, ophthalmoplegia	Pos	Pos (lung infiltrate on CXR)	Sputum culture	Pos	Pos	HRZ+ Pyridoxine for 2 mos, then HR for 10 mos, Prednisolone for 1mo	Complete resolution with improved imaging
Rebai et al. [7]	44	F	Headache, right ptosis, horizontal diplopia,	Pos	Pos (en-capsulated	Biopsy of lesion	not mention	not mentioned	HRE	Complete resolution with

			right CN III & V & VI deficits		pleurisy)	performed revealing tuberculoma	ed			improved imaging
Hui [8]	48	M	Headache, double vision, right eye abduction deficit, absent right corneal reflex, right eye ptosis, right CN III & IV & V, & VI deficits	Neg	Neg	Operative removal revealing granuloma	Pos	Pos	ATD for 12 mos	Residual right abducens nerve palsy
Yanardag et al. [9]	36	M	Headache, ptosis, diplopia, medial upward and lateral left gaze deficits, hemifacial hypoaesthesia in CN VI area	Neg	Neg	Operative removal revealing tuberculoma	Pos	Pos	HRE	MR improved at 2 months; symptoms improved at 4 months
Kesavadas et al. [10]	29	M	Left-side facial numbness, decreased taste, right upper & lower extremity hypotonia weakness, left CN V sensory deficit, left temporalis & masseter wasting	Neg	Neg	CSF lymphocytosis, operative removal revealing granuloma	Pos	Pos	ATD for 4 mos	Complete resolution with improved imaging
Boutarbouch et al. [11]	45	M	Headache, periorbital pain, left hemifacial neuralgia, diplopia, ptosis, lateral gaze palsy	Neg	Neg	CSF lymphocytosis, operative removal revealing granuloma	Pos	Pos	HRE for 3 mos then HR for 9 mos	Complete resolution with improved imaging
Jaimovich et al. [12]	45	F	Headache, right ptosis, right hemifacial hypoesthesia, right ophthalmoplegia	Neg	Neg	Operative removal revealing granuloma	not mentioned	Pos	HRZE for 2 mos then HR for 4 mos + Dexamethasone for 8 wks	Complete resolution with improved imaging
Kumar et al. [13]	11	F	Right hemicranial headache, diplopia, numbness of the right side of her face,	Neg	Pos (mastoid air cells)	Operative removal revealing granuloma	not mentioned	not mentioned	HRZE for 18 mos	Complete resolution with improved imaging

			right ear purulent discharge and hearing loss							
Haque et al. [14]	35	M	Headache, right-sided ptosis, CN III palsy of right side	Neg	Neg	Operative removal revealing granuloma	not mentioned	not mentioned	ATD+anti convulsions for 18 mos	Ocular symptoms improved within 4 wks with improved imaging at 18 mos
Kapadia et al. [15]	48	F	Diplopia, headache, photophobia, ptosis, lateral gaze palsy, diminished medial & downward gaze, facial hypoesthesia	Neg	Pos (subcarinal LN involvement)	Quantiferon 1-GOLD test positive, biopsy of the subcarinal LN revealed granulomas & Pos for culture	not mentioned	Pos	HRZE + L for 3 mos, HR + L for 1 mo+ HR for 8 mos + Prednisolone	Ocular symptoms improved rapidly with near complete resolution on MRI at 1 mo
Intusoma et al. [16]	3	F	Ptosis, medial gaze palsy of right eye, mild proptosis, 4 mm non-reactive pupil	Pos	Pos (lung infiltrate on CXR)	Presumed diagnosis, abnormal CXR, Pos culture	Pos	Pos	ATD for 12 mos	Complete resolution with improved imaging
Konar et al. [17]	4	M	Sudden onset of high-grade fever, severe headache along with periorbital edema, bilateral proptosis, ptosis of both eyes, retro-orbital pain, two episodes of generalized tonic-clonic convulsions	Neg	Pos (cervical LN)	Biopsy of cervical LN revealed granulomas & Pos for culture	Pos	Pos	ATD for 12 mos+ Dexamethasone for 7 days+ prednisolone for 7 wks	Gradual reduction of periorbital edema with regression of proptosis within five days, the signs of CN affection resolved within two wks, the left-sided weakness persisted but was gradually improving

F: Female; **M:** Male; **Pos:** Positive; **Neg:** Negative; **CN:** Cranial nerve; **LN:** Lymph node; **HRZE:** [H =Isoniazid, R =Rifampicin, Z=Pyrazinamide, E =Ethambutol]; **L:** Levofloxacin ; **ATD:** Antitubercular drugs ; **AFB:** Acid Fast Bacilli; **mo(s):** Month(s) ; **yrs:** Years ; **wks:** Weeks

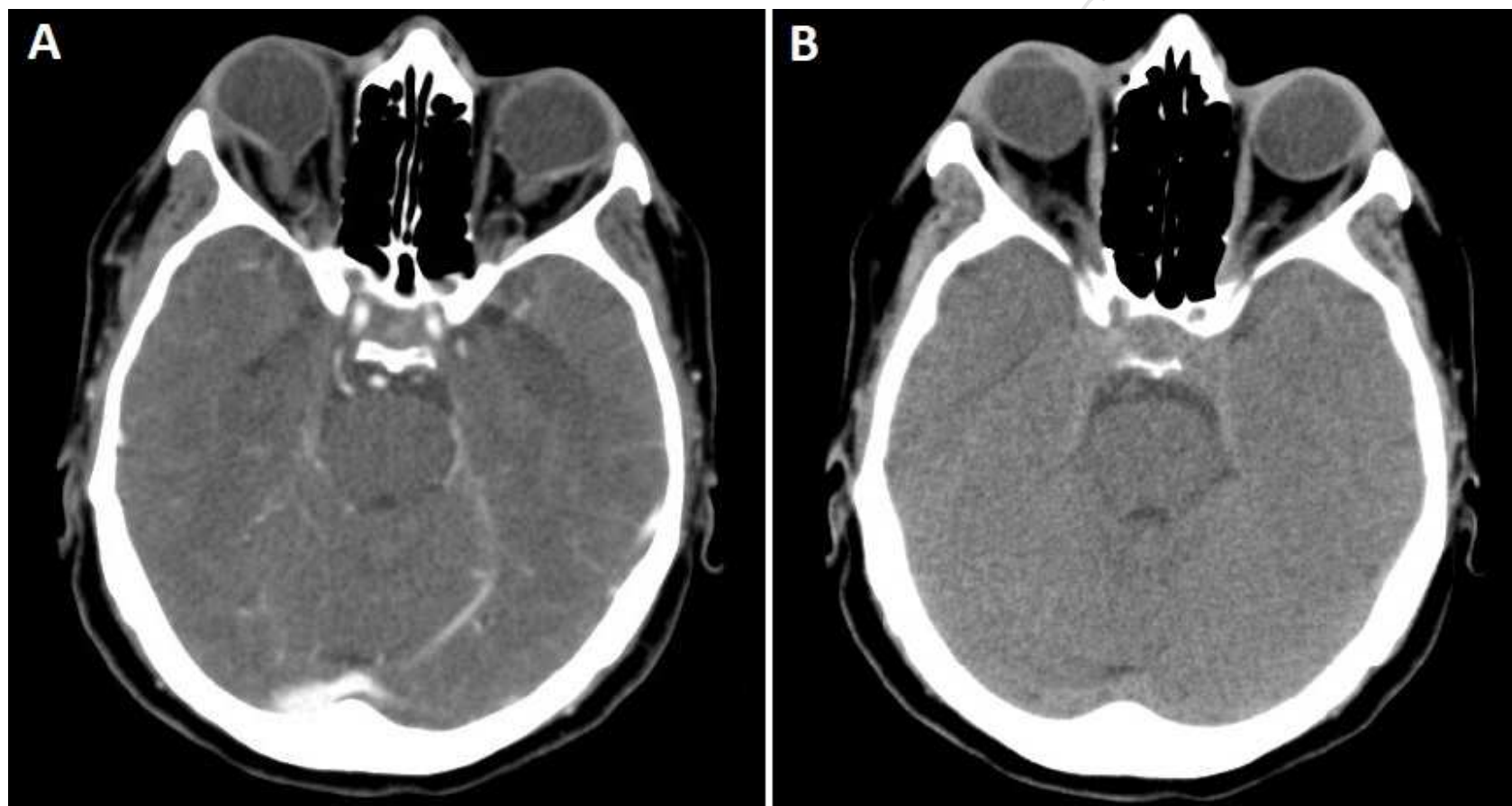


Figure-1. Brain CT with (A) and without contrast (B) demonstrated negative findings.

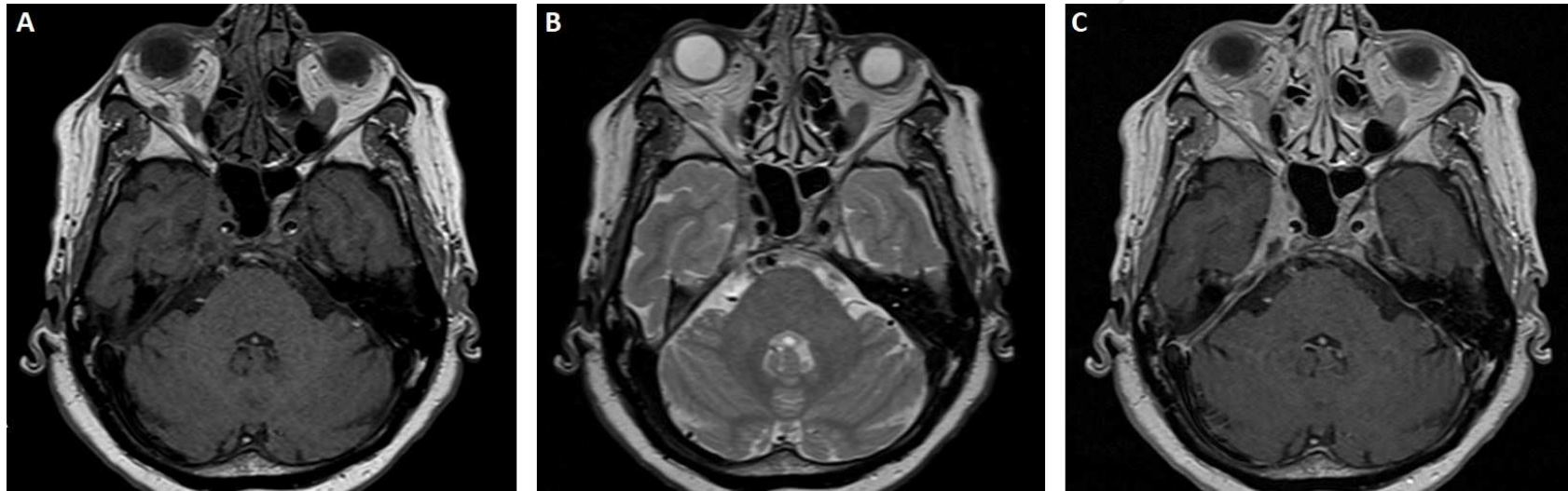

Figure-2. MRI of the patient. Axial view of sella showed a lesion in the right parasellar which occupied right cavernous sinus on T1-weighted (**A**) and T2-weighted (**B**) images. Intravenous gadolinium administration demonstrated a lesion with homogeneous enhancement on the T1-weighted image (**C**).

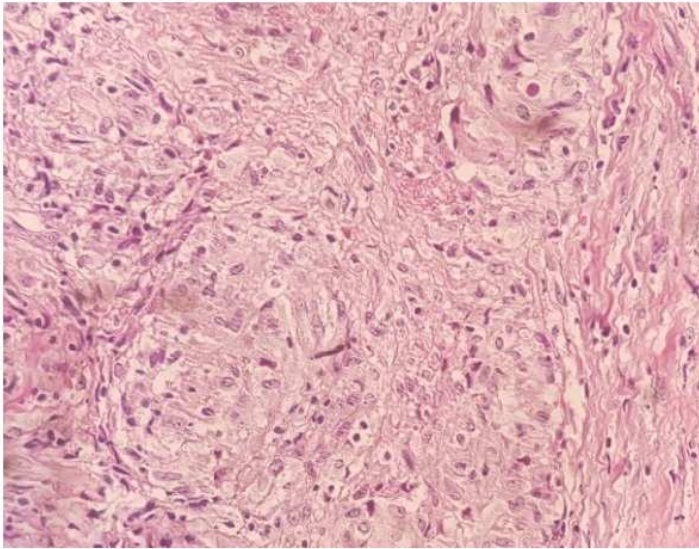
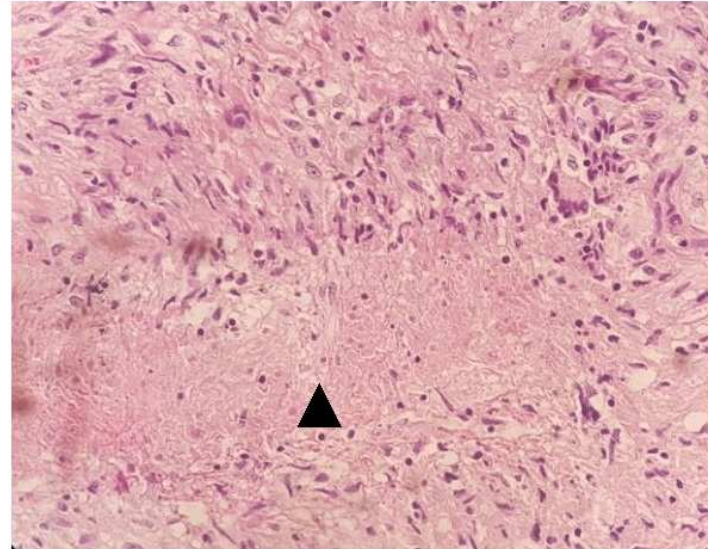
A**B**

Figure-3. Photomicrographs of the removed tissue specimen showed granulomatous inflammation with (A) and without (B) caseous necrosis (arrowhead), hematoxylin and eosin staining (original magnification 40x)

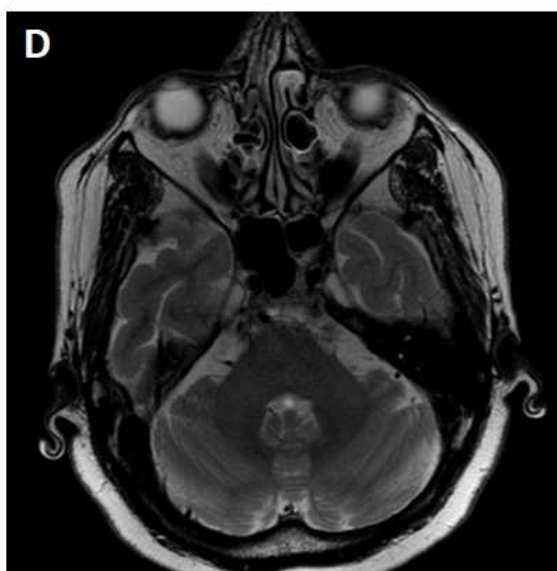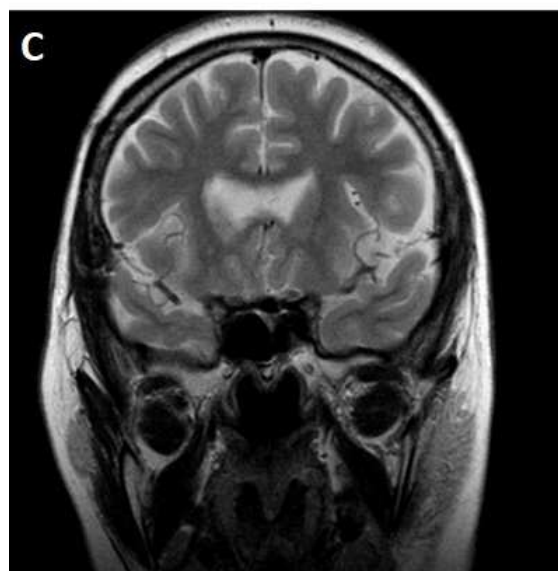
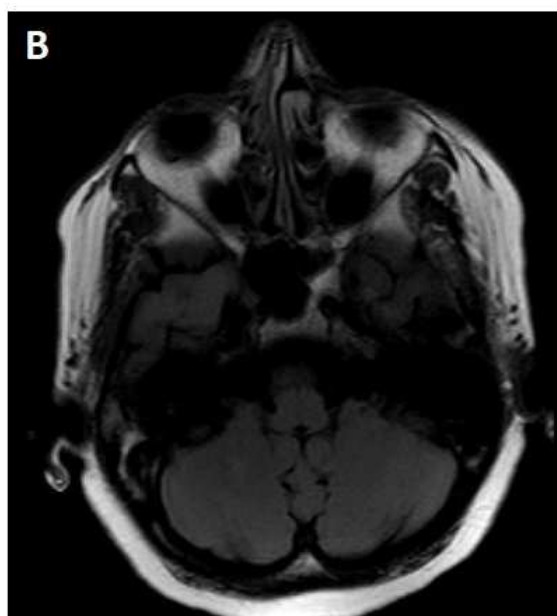
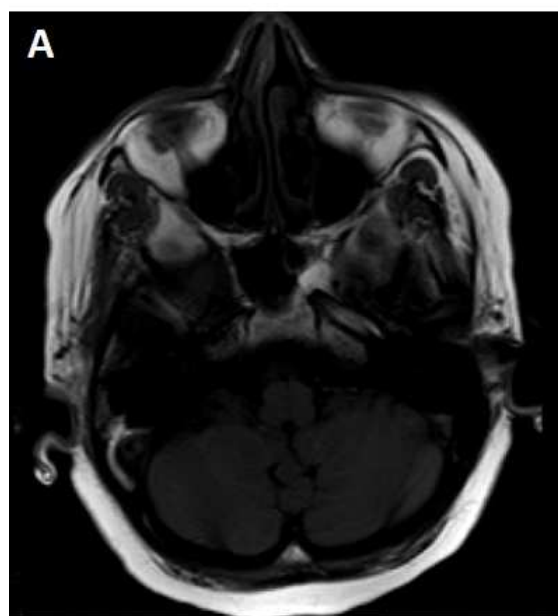


Figure-4. Brain MRI of the patient revealed no any lesions after 1-year follow-up. **A:** T1-weighted without contrast; **B:** T1-weighted with intravenous contrast; **C:** T2-weighted; **D:** T2-weighted FLAIR sequence

- Tuberculosis as the global concern could affect any part of the nervous system; however, cavernous sinus tuberculomas (CSTs) is a rare condition.
- Both imaging and bacteriological studies provide diagnosis of CST. While in some cases, bacteriologic samples may be negative for *Mycobacterium tuberculosis*.
- We describe the first case of CST that tuberculous bacilli were absent, and cultures from cerebrospinal fluid and the excised mass, even *M. tuberculosis* DNA assay were negative.