



# Probable pathogenesis, diagnosis, and management of untreated arteriovenous malformation with cyst formation: case report and literature review

Yu-Tse Liu<sup>1</sup> · Tao-Chieh Yang<sup>3</sup> · Shih-Ming Jung<sup>2</sup> · Cheng-Chi Lee<sup>1</sup> 

Received: 17 April 2018 / Accepted: 30 August 2018  
© Belgian Neurological Society 2018

## Abstract

Arteriovenous malformations (AVMs) usually manifest as headaches, seizures, focal neurological signs, and spontaneous intracerebral or subarachnoid hemorrhages. An untreated AVM with associated cyst formation is extremely rare, and the probable pathogenesis is unclear. We propose and discuss the possible pathogenesis of this condition and its diagnosis and management. A 26-year-old male presented with a generalized tonic–clonic seizure. Computed tomography showed a cystic lesion in the left frontal lobe and magnetic resonance imaging revealed a complex composition within the lesion, without a flow-voiding signal. Therefore, the initial diagnosis was oligodendroglioma and surgical treatment was performed. However, intraoperatively, engorged reddish nodule-like vessels with a cystic capsule and intra-cyst brown and sticky fluid were found. The nodule-like vessels and cystic capsule were resected completely. The patient's postoperative course was uneventful, with an excellent neurological outcome and no further seizures. Pathological examination of the surgical specimen revealed the typical microscopic appearance of an AVM, with numerous thin-walled vascular channels and deposits of hemosiderin in fibrous tissue. In conclusion, an untreated AVM with associated cyst formation is extremely rare, and the mechanism of formation is unclear. We propose a probable pathogenesis. Preoperative diagnosis, intraoperative management, and postoperative follow-up are equally crucial in dealing with this extremely rare condition. Cystic tumors associated with arteriovenous malformations (AVMs) are uncommon and are usually a complication of stereotactic radiosurgery (Ilyas et al. in *J Neurosurg.* <https://doi.org/10.3171/2016.12.JNS162478>, 2017) or form after a hemorrhage (Daniels et al. in *Radiology* 133:393–394, 1979). Untreated AVMs with large cysts or cystic tumors are rare, with only five cases reported in the literature (Table 1). Here, we present a case of an untreated AVM associated with cystic formation, or a cystic tumor, in the left frontal lobe.

**Keywords** Arteriovenous malformation · Pathogenesis · Management

## Introduction

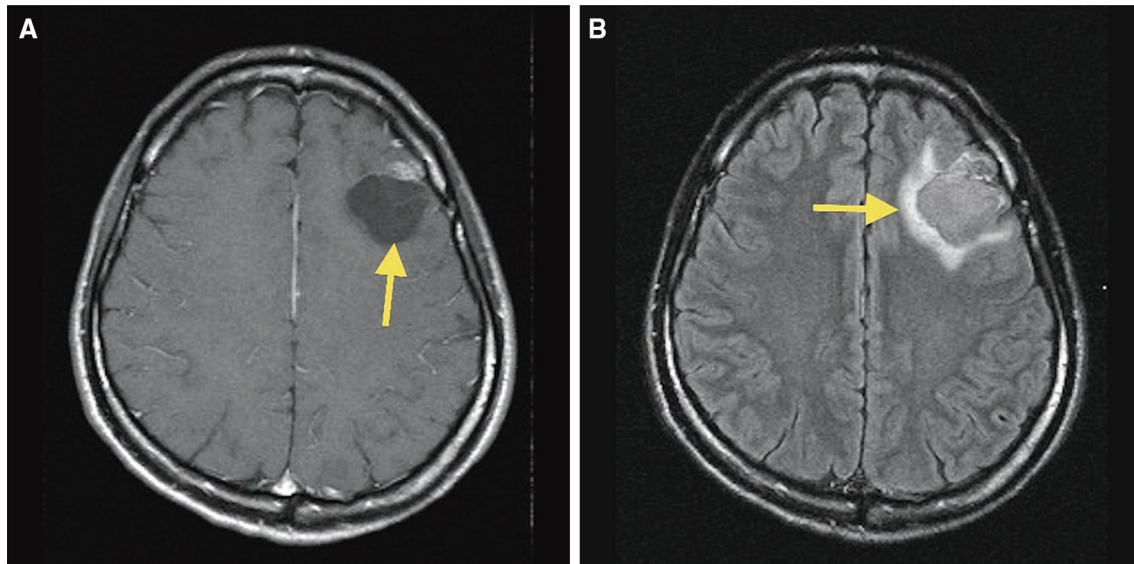
A 26-year-old male was admitted following a generalized tonic–clonic seizure. He had no history indicating acute bleeding (Fig. 1). Brain CT revealed a cystic lesion in the

left frontal lobe with calcification and an enhancing portion approximately 3.1 cm in diameter. The cystic formation was of low density and homogenous with mild perifocal edema. MRI revealed a lesion with a complex composition. No flow-voiding signal was detected. On T2-weighted images the lesion was hyperintense, and on FLAIR was completely inverted. T1-weighted images with contrast showed a hyperintense nodule near the mass surface (Fig. 1). A tumor (e.g., oligodendroglioma) was the initial diagnosis.

Left frontal craniotomy was performed. An engorged, reddish nodule-like vessel on the cortical surface was noted. A thick, firm cyst capsule was found; sticky, brown fluid was expelled upon cutting the cystic formation. The nodule-like lesion and part of the capsule were excised. Intraoperative frozen section of the capsule revealed fibrous tissue containing hemosiderin. Final pathology showed abnormal arterial

✉ Cheng-Chi Lee  
yumex86@hotmail.com

<sup>1</sup> Department of Neurosurgery, Chang Gung Memorial Hospital, Chang Gung University, No. 5 Fu-Shin Street, Gui-Shan Dist., Taoyuan 33305, Taiwan, Republic of China  
<sup>2</sup> Department of Pathology, Chang Gung Memorial Hospital, Linkou, Taoyuan, Taiwan, Republic of China  
<sup>3</sup> Department of Neurosurgery, Asia University Hospital, Taichung, Taiwan, Republic of China



**Fig. 1** Preoperative brain MRI. **a** MRI with enhancement revealed an intra-axial mass lesion located in the anterior aspect of the left middle frontal lobe with a complex composition, including calcification, gli-

osis, and a cystic component (arrow). The maximal dimension of this lesion measured approximately 33.4 mm. **b** FLAIR images revealed perilesional edema surrounding the lesion (arrow)

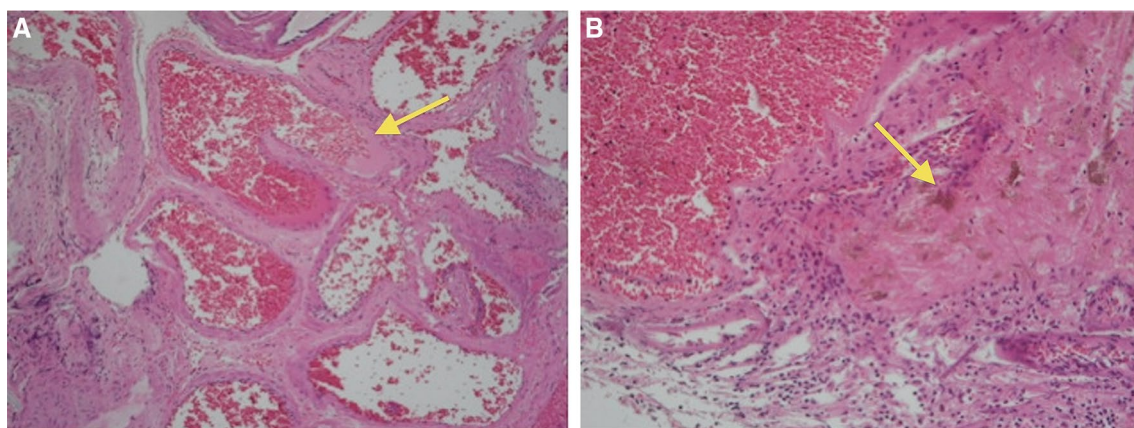
and venous channels; hemosiderin was in the fibrous tissue (Fig. 2). The postoperative course was uneventful. Brain MRI approximately 6 months later indicated no residual or recurrent AVM.

## Discussion

Two theories exist regarding cystic formations and their contents. One suggests repeated bleeding from the neovascular system on the cyst wall with old hemorrhage inside, and the other proposes gradual exudation of fluid from the nidus causing its expansion, without xanthochromia or hemorrhage inside the cystic tumor. Three different types of fluid

are found within the cysts: clear CSF-like fluid, xanthochromic fluid, and degraded brown blood [3–7]. We propose that cases with neovascularization have repeated bleeding episodes while absorption of previous bleeds is occurring; therefore, multiple thin-walled neovascular channels and brown fluid result. In cases without evidence of neovascularization and only clear CSF-like fluid inside the cystic formation, there may be limited bleeding and the blood will be absorbed completely resulting in only CSF-like contents without neovascular channels.

The cystic formation in our case was suggestive of long-term repeated bleeding episodes producing marked neovascularization on the cyst wall and cyst expansion. These bleeding episodes contributed to chronic inflammation and



**Fig. 2** Histological examination of the nidus. **a** Section of the AVM nodule. Abnormal arterial and venous channels were noted (arrow). **b** Excision from the wall near the AVM with cystic tumor in the lower left. Hemosiderin was found in the fibrous tissue (arrow)

**Table 1** Review of literature

Author	Sex	Age (years)	Presentation	Location
Yamaguchi et al. [3]	F	14	Headache	Left parietal
Sabnarwal et al. [4]	M	8	Seizure	Left parietal
Boyd et al. [5]	M	18	Seizure	Right temporal
Itakura et al. [6]	F	33	Seizure	Right temporal
Hatashita et al. [7]	M	37	Quadrantanopia, seizure	Right temporal

perifocal edema demonstrated on FLAIR. This formation mechanism is somewhat similar to the cause of intimal formation of chronic subdural hemorrhage. Because this type of patient is not common and the AVM is not likely to form a classic cyst, the initial imaging diagnosis and clinical characteristics were highly suspected of oligodendroglioma, which requires surgical treatment. If this type of cystic formation is considered to be a tumor, radiation therapy may be given and would not achieve the desired effect. Otherwise, if operative treatment is carried out, dissection of the nodule may cause postoperative bleeding or other complications. Therefore, in such cases, preoperative MRA or CTA may be necessary to analyze the status of the intracranial vasculature.

For the diagnosis of cystic AVMs, detailed MRI studies are crucial. When an AVM is encountered incidentally intraoperatively, we suggest performing an indocyanine green (ICG) study [8]. MRI and angiography should be performed 6 months postoperatively, and annually thereafter for several years (Table 1).

**Acknowledgements** This work was supported by the Department of Neurosurgery, the Department of Pathology of Chang Gung Memorial Hospital, and Chang Gung University, Taoyuan, Taiwan, R.O.C.

**Funding** None.

### Compliance with ethical standards

**Conflict of interest** The authors declare that there are no conflicts of interest.

**Ethics approval and consent to participate** This study was approved by the Chang Gung Medical Foundation Institutional Review Board.

**Informed consent** For this type of study, formal consent is not required.

### References

- Ilyas A, Chen CJ, Ding D, Mastorakos P, Taylor DG, Pomeranec II, Lee CC, Sheehan J (2017) Cyst formation after stereotactic radiosurgery for brain arteriovenous malformations: a systematic review. *J Neurosurg.* <https://doi.org/10.3171/2016.12.JNS162478> (**pub ahead of print**)
- Daniels DL, Houghton VM, Williams AL, Strother CM (1979) Arteriovenous malformation simulating a cyst on computed tomography. *Radiology* 133:393–394
- Yamaguchi T, Shinoda S, Masuzawa T, Abe T (1993) A case of arteriovenous malformation with cyst formation. *No Shinkei Geka* 21:453–457
- Sabharwal P, Maiti T, Konar S, Pandey P (2013) Arteriovenous malformation associated with cyst in a child: case report and review of literature. *J Pediatr Neurosci* 8:126–128
- Boyd MC, Steinbok P, Paty DW (1985) Familial arteriovenous malformations: report of four cases in one family. *J Neurosurg* 62:597–599
- Itakura T, Takifuji K, Ozaki K, Itatani K, Nishiguchi T, Hayashi S, Komai N (1989) Cystic arteriovenous malformation. A case report. *Acta Neurochir (Wien)* 96:154–158
- Hatashita S, Tajima A, Takeuchi K, Ueno H (1995) Arteriovenous malformation associated with a large cyst—case report. *Neurol Med Chir (Tokyo)* 35:377–379
- Zaidi HA, Ablal AA, Nakaji P, Chowdhry SA, Albuquerque FC, Spetzler RF (2014) Indocyanine green angiography in the surgical management of cerebral arteriovenous malformations: lessons learned in 130 consecutive cases. *Neurosurgery* 10:246–251