

## Surgical Treatment for Primary Brainstem Hemorrhage to Improve Postoperative Functional Outcomes

Shinya Ichimura<sup>1,4</sup>, Helmut Bertalanffy<sup>4</sup>, Masato Nakaya<sup>1</sup>, Yoichi Mochizuki<sup>1</sup>, Goroku Moriwaki<sup>2</sup>, Ryuichi Sakamoto<sup>3</sup>, Masahito Fukuchi<sup>1</sup>, Koji Fujii<sup>1</sup>

■ **BACKGROUND:** It remains controversial whether primary brainstem hemorrhage (PBH) should be managed conservatively or treated promptly by surgical evacuation of the hematoma. In the present study, we discuss 5 cases of PBH that were treated surgically and the ability of surgical management to improve postoperative functional outcomes.

■ **METHODS:** The 4 patients with pontine and medullary hemorrhage underwent surgery via the lateral or midline suboccipital and trans-rhomboid fossa approach in the half-sitting position. The patient with a midbrain hemorrhage underwent surgery via the subtemporal approach in the supine lateral position. We analyzed the postoperative functional outcomes 1 week after surgery and the modified Rankin scale scores 6 months after discharge.

■ **RESULTS:** Three patients with disturbance of consciousness experienced improvement in their level of consciousness. Four patients with hemiparesis improved in motor function. Oculomotor nerve function improved in 2 of 3 cases. Facial nerve function improved in 2 of 2 cases. Spontaneous respiration improved in 1 patient. The postoperative modified Rankin scale scores improved in all 5 cases.

■ **CONCLUSIONS:** Because of the good results with these 5 patients with PBH, this surgical strategy could be encouraged with exclusion criteria for early initiation of

rehabilitation strategies. We hope to increase our number of patients to accumulate further evidence.

### INTRODUCTION

Primary brainstem hemorrhage (PBH) is a catastrophic event associated with a poor prognosis.<sup>1-7</sup> Among eastern Asian populations, PBH accounts for ~10% of the cases of intracerebral hemorrhage and has an incidence of 2%–4% per 100,000 of the population annually.<sup>7-10</sup> It appears that PBHs are mostly hypertensive.<sup>3,11</sup> The clinical features, which can be lethal, are generally very precocious, manifesting within a few minutes or hours after the hemorrhage even if the hemorrhage is small.<sup>3</sup>

In previous studies, the prognosis was found to be very poor, with overall mortality rate of 30%–90%.<sup>8,12-17</sup> The favorable outcome rate for PBH with conservative treatment was 15.3%–78%.<sup>5,17-19</sup> PBH frequently causes severe disturbances of consciousness, papillary abnormalities, and respiratory and motor disturbances.<sup>16</sup> However, it remains controversial whether PBH should be managed conservatively or treated promptly via surgical evacuation of the hematoma.<sup>6</sup> Although several investigators have advocated for conservative management,<sup>2,4,6</sup> others have reported the efficacy of surgical treatment in patients with PBH.<sup>3,6,20,21</sup>

Conservative treatment of PBH mainly has consisted of continuous intravenous antihypertensive therapy. Recent advancements such as microsurgical and neuroimaging techniques, intraoperative

#### Key words

- Half-sitting position
- Primary brainstem hemorrhage
- Postoperative functional outcome
- Surgical treatment

#### Abbreviations and Acronyms

- CT: Computed tomography
- GCS: Glasgow coma scale
- H-B: House-Brackmann (grading system)
- MMT: Manual motor testing
- MRI: Magnetic resonance imaging
- mRS: Modified Rankin scale
- Nerve III: Oculomotor nerve

Nerve VI: Abducens nerve

PBH: Primary brainstem hemorrhage

From the Departments of <sup>1</sup>Neurosurgery, <sup>2</sup>Anesthesiology, and <sup>3</sup>Rehabilitation, Shizuoka City Shimizu Hospital, Shizuoka, Japan; and <sup>4</sup>Department of Neurosurgery, International Neuroscience Institute, Hannover, Germany

To whom correspondence should be addressed: Shinya Ichimura, M.D.  
[E-mail: [shinya3917@gmail.com](mailto:shinya3917@gmail.com)]

Citation: *World Neurosurg.* (2018).

<https://doi.org/10.1016/j.wneu.2018.09.055>

Journal homepage: [www.WORLDNEUROSURGERY.org](http://www.WORLDNEUROSURGERY.org)

Available online: [www.sciencedirect.com](http://www.sciencedirect.com)

1878-8750/\$ - see front matter © 2018 Elsevier Inc. All rights reserved.

**Table 1.** Patient Characteristics

Patient	Age (Years)	Sex	Location	Extension	Volume (mL)	Medical History	Medication	Perihematomal Edema	Repeat Bleeding
1	62	Female	Pons	Massive	4.4	HT	Anti-HT agent	No	No
2	71	Male	Pons	Dorsal	1.5	No	No	No	No
3	82	Female	Midbrain	Dorsal	1.9	HT	No	Yes	No
4	70	Female	Medulla	Massive	0.8	No	No	No	No
5	45	Male	Pons	Dorsal	1.0	No	No	No	No

HT, hypertension.

neurophysiologic monitoring, and neuronavigation might allow for improvements in the prognosis for patients with PBH undergoing surgery. Nonetheless, the efficacy of surgical management remains debatable.<sup>6</sup>

In the present study, we discuss 5 cases in which patients with PBH were treated surgically and the ability of surgical management to improve postoperative functional outcomes for the early initiation of rehabilitation strategies.

## METHODS

We reviewed the data from 5 consecutive patients with PBH who had been treated by surgical evacuation from May 2017 to May 2018 at Shizuoka City Shimizu Hospital (Shizuoka, Japan). The patient characteristics are listed in **Table 1**. Our exclusion criteria for surgery for PBH are poor initial consciousness (coma or semicomma) and bilateral pupil dilation. However, in the present study, we did not exclude any patients with PBH because they had met our exclusion criteria.

Of the 5 patients, 3 were women and 2 were men, with an age range of 45–82 years (mean, 66). The location of the hemorrhage was in the midbrain in 1, pontine in 3, and medullary in 1 patient. Using the extension of the hemorrhage, all 5 cases were classified into 3 subtypes as described by Wessels et al.<sup>7</sup>: dorsal, ventral, or massive. The dorsal type is defined as hemorrhage in a tegmental location. The ventral type consists of hemorrhage in a ventral location and the junction between the bilateral tegmentum. Massive hemorrhage describes hemorrhage in both dorsal and ventral locations within entire brainstem. Of our 5 patients, 3 had dorsal and 2 had massive hemorrhage.

The hemorrhage volume was calculated from the initial computed tomography (CT) scan using the ABC/2 formula, where A and B are the perpendicular maximal diameters of the lesion and C is the total length in the vertical plane.<sup>22</sup> The volume of the PBH ranged from 0.8 to 4.4 mL (mean, 1.92). One patient had perihematomal edema found on the preoperative T2-weighted magnetic resonance imaging (MRI) studies. Two patients had a history of hypertension. One patient was given antihypertensive therapy but no patient received antiplatelet or anticoagulant agents. No episodes of repeat bleeding were found on the preoperative CT or MRI scans.

## Surgery for PBH

The interval to surgery ranged from 4 to 21 days (mean, 8.2) because our protocol required certain observation period for PBH (**Table 2**).

The 4 patients with pontine and medullary hemorrhage underwent surgery via the lateral or midline suboccipital and trans-rhomboid fossa approaches in the half-sitting position. The patient with midbrain hemorrhage underwent surgery via the subtemporal approach in the supine lateral position. Intraoperative neurophysiologic monitoring for motor evoked potentials, sensory evoked potentials, direct facial nerve stimulation, and auditory brainstem response and neuronavigation were used in all 5 cases.

MRI and intraoperative exploration revealed no causative lesions (e.g., cavernous or arteriovenous malformations) in any case. The level of consciousness was evaluated using the Glasgow coma scale (GCS), and motor function was assessed using manual motor testing (MMT). Eye movement (oculomotor nerve [nerve III], abducens nerve [nerve VI], and facial nerve [nerve VII]) was evaluated using the House-Brackmann (H-B) grading system. The preoperative and 1-week postoperative findings were compared for all 5 patients. We also compared the preoperative modified Rankin scale (mRS) scores with those obtained 6 months after discharge.

## RESULTS

### Functional Outcomes 1 Week After Surgery

The GCS scores improved in 3 patients and motor function improved in 4 patients (**Table 3**). Nerve III palsy improved in patients 1 and 3, but nerve III and VI palsy did not improve in patient 2. Facial nerve (nerve VII) palsy improved in patients 1 and 2. Spontaneous respiration improved in patient 4.

### mRS Scores 6 Months After Surgery

We followed up all 5 patients in our outpatient clinic after surgery and evaluated them face to face. After postoperative rehabilitation,

**Table 2.** Surgery for Primary Brainstem Hemorrhage

Patient	Location	Interval to Surgery (Days)	Position	Approach
1	Pons	21	Half-sitting	Lateral suboccipital
2	Pons	6	Half-sitting	Rhomboid fossa
3	Midbrain	5	Supine lateral	Subtemporal
4	Medulla	4	Half-sitting	Midline suboccipital
5	Pons	5	Half-sitting	Lateral suboccipital

**Table 3.** Postoperative Functional Outcomes 1 Week After Surgery

Patient	Consciousness Level (GCS)	Motor Function (MMT)	Nerve III Palsy	Nerve VI Palsy	Nerve VII Palsy (H-B Grade)	Spontaneous Respiration
1	Improved (13→15)	Improved (3→5)	Improved	NA	Improved (2→0)	NA
2	Improved (13→14)	Improved (3→4)	No change	No change	Improved (2→0)	NA
3	Improved (13→15)	Improved (3→5)	Improved	NA	NA	NA
4	NA	NA	NA	NA	NA	Improved
5	NA	Improved (4→5)	NA	NA	NA	NA

GSC, Glasgow coma scale; MMT, manual motor testing; Nerve III, oculomotor nerve; Nerve VI, abducens nerve; Nerve VII, facial nerve; H-B, House-Brackmann; NA, not applicable.

the mRS scores at 6 months after surgery had improved in all 5 patients (Table 4).

## CASE REPORTS

### Patient 1

A 62-year-old woman with a history of hypertension had been admitted to another hospital owing to a sudden disturbance of consciousness. The CT scan revealed the presence of a primary pontine hemorrhage (Figure 1, first from left). She received conservative treatment for 2 weeks. However, her symptoms did not improve, and she was referred to our hospital. On admission, she exhibited disturbance of consciousness (GCS score, 13), left hemiparesis (MMT score, 3), right nerve III palsy, and left facial nerve (nerve VII) palsy (H-B grade 2). At 21 days from onset, she underwent surgery via the lateral suboccipital approach in the half-sitting position (Figure 2) after her family had provided written informed consent. We confirmed that direct facial nerve stimulation produced no response, after which the hematoma was evacuated from the lateral side of the pons (Figure 3). The patient's level of consciousness, motor function, eye movement, and facial palsy began to improve in the early postoperative period. Postoperative MRI revealed complete removal of the hematoma in the pons. She was alert and discharged with an independent gait after recovery, although she continued to experience difficulty with dexterity and movement in her left hand.

**Table 4.** Modified Rankin Scale Scores Before and 6 Months After Surgery

Patient	mRS Score	
	Preoperatively	Postoperatively
1	5	1
2	5	4
3	5	2
4	5	1
5	4	0

mRS, modified Rankin scale.

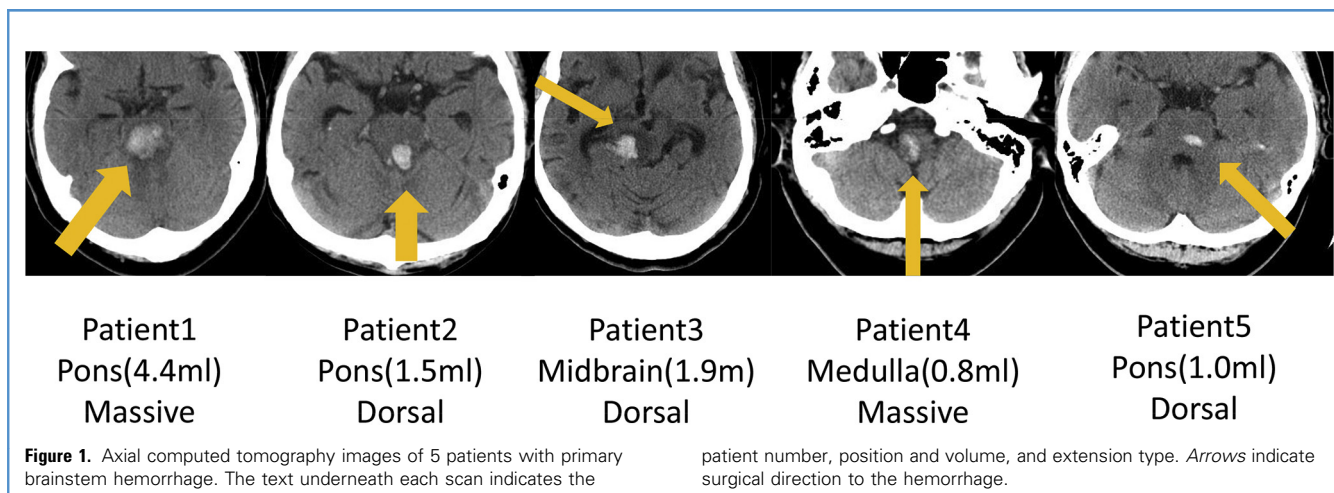
### Patient 2

A 71-year-old man was referred to our hospital owing to a sudden loss of consciousness and dysarthria. On admission, he exhibited disturbance of consciousness (GCS score, 13), right hemiparesis (MMT score, 3), left nerve III and nerve VI palsy, and left VII palsy (H-B grade 2). The CT scan revealed the presence of a primary pontine hemorrhage (Figure 1, second from left). At 6 days from onset, he underwent surgery via the trans-rhomboid fossa approach in the half-sitting position after his family had provided written informed consent. A hematoma was evacuated from the suprafacial triangle via the rhomboid fossa (Figure 4). His level of consciousness, motor function, and facial palsy began to improve in the early postoperative period, although his eye movement remained impaired. Postoperative MRI revealed complete removal of the hematoma in the pons. The patient was discharged after the recovery period. Although he experienced improvement in consciousness and hemiparesis, he remained confined to a wheelchair and required assistance during daily activities.

## DISCUSSION

In the present study, we discuss the cases of 5 patients who underwent surgical treatment for PBH. All 5 patients exhibited improvements in consciousness, motor function, and mRS scores after surgery.

Takeuchi et al.<sup>16</sup> reported that the outcomes of patients with PBH 3 months after onset in natural history included a good recovery in 6.1%, moderate disability in 12.7%, severe disability in 12.7%, a vegetative state in 10.8%, and death in 57.5%.<sup>16</sup> Considering functional recovery for primary pontine hemorrhage with conservative management, Dziewas et al.<sup>10</sup> reported a good recovery rate of 25% among 12 survivors, Rabinstein et al.<sup>5</sup> reported a rate of 77% among 36 patients, Wijdicks and St. Louis<sup>17</sup> reported a rate of 47% among 17 patients, Jung et al.<sup>19</sup> reported a rate of 54.5% among 22 patients, and Masiyama et al.<sup>18</sup> reported a rate of 78% among 14 survivors. The guidelines issued by the American Heart Association and European Stroke Organisation do not include definite specifications for the treatment of patients with spontaneous hypertensive brainstem hemorrhage.<sup>23,24</sup> Although the role of surgery in the management of PBH remains controversial, several case-control studies have demonstrated that surgery can decrease mortality and improve functional outcomes for patients with PBH.<sup>3,6,8,20,25,26</sup>

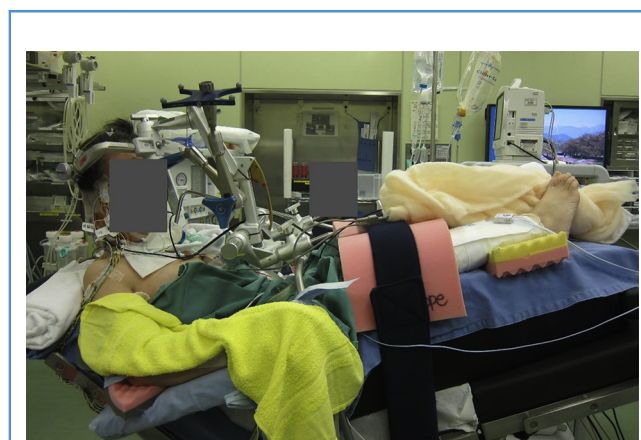


Tao et al.<sup>27</sup> suggested that the surgical outcomes are affected, not only by the hematoma volume and severity of consciousness impairment (both 30-day mortality and 3-month functional outcomes), but also by patient age and type of hemorrhage (30-day mortality) and rostrocaudal extension (3-month functional outcomes).<sup>27</sup> Although large hematomas usually lead to severe impairment in consciousness, the investigators also reported that the GCS score on admission significantly influenced the surgical outcomes, independently of the hematoma volume.<sup>27</sup>

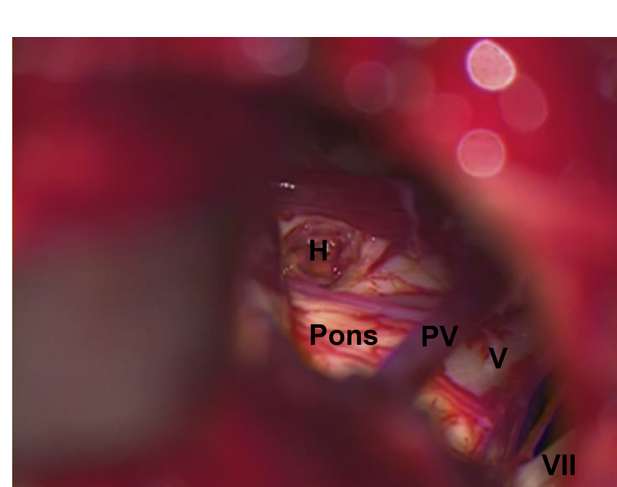
Emergency craniotomy and evacuation of the hematoma could be a feasible option for primary supratentorial hemorrhage with a volume of 20–100 mL.<sup>28,29</sup> Also, spontaneous cerebellar hemorrhage >3 cm in diameter benefited from surgical evacuation.<sup>29,30</sup> Wessels et al.<sup>7</sup> and Ye et al.<sup>31</sup> found a high correlation between poor outcomes and a hematoma volume >4 mL. Perihematomal

edema is the radiological manifestation of secondary injury and has been associated with poor outcomes after intracerebral hemorrhage.<sup>32-34</sup> The space-occupying effect of the hemorrhage, with perihematomal edema often causing secondary brainstem injury, could have led to the slow recovery of neurological function.<sup>6</sup>

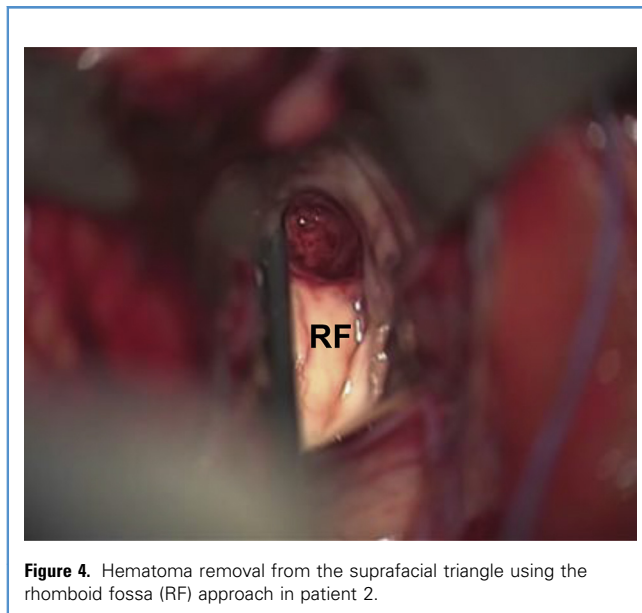
Tao et al.<sup>27</sup> concluded that patients with primary pontine hemorrhage who were younger age, had a smaller hematoma without rostrocaudal extension and/or a unilateral hemorrhage, and had a greater GCS score might benefit from surgery. They also suggested that the GCS score on admission, independently of the hematoma volume, had an effect on the surgical results, although a large hematoma usually leads to a severe unconscious state.<sup>27</sup> Previous studies have documented that both a large hematoma volume and a lower level of consciousness on



**Figure 2.** Patient 1 was treated in the half-sitting position. The hip was flexed to a maximum of 90° and the legs were elevated, with the toes positioned near the top of the head. The upper body was leaned back as far as possible, and the head was flexed anteriorly.



**Figure 3.** Hematoma removal via the lateral suboccipital approach in patient 1. PV, petrosal vein; V, trigeminal nerve; VII, facial nerve.



**Figure 4.** Hematoma removal from the suprafacial triangle using the rhomboid fossa (RF) approach in patient 2.

admission are associated with greater mortality and poorer functional outcomes.<sup>7,25,26</sup>

The location and size of the brainstem hematoma should dictate the surgeon's operative approach for removal. The complex neuroanatomic structure of the brainstem and surrounding vasculature must be considered when planning the most optimal route to the hematoma.<sup>6</sup> Intraoperative neurophysiologic monitoring and neuronavigation are indispensable for preserving neurological function.<sup>6</sup> A brainstem hemorrhage will usually dissect, rather than destroy, adjacent structures and can expand so rapidly as to acutely endanger the patient's life.<sup>1</sup> In conjunction with the surrounding vasogenic edema, this effect can lead to secondary brainstem injury and slow the rate of neurological recovery.<sup>6</sup> For cases accompanied by compression of the pyramidal tract, oculomotor and abducens nerve nuclei, facial nerve nucleus, facial nerve loop, and reticular formation, evacuation of the brainstem hematoma can improve motor function, eye movement, and disturbance of consciousness. Such improvements in the early postoperative period might then allow for early initiation of rehabilitation procedures.

Several previous studies have revealed that the "half-sitting" or "semi-sitting" position is associated with good surgical outcomes in patients with lesions of the posterior fossa.<sup>3,6,35-37</sup> Despite the risk of venous air embolism and tension pneumocephalus, use of the half-sitting rather than the prone or lateral position has several obvious surgical advantages. The former position is preferable because of the lack of venous congestion, easy descent of cerebellum gravity, and the possibility of operating within a bloodless surgical field.<sup>38</sup> These advantages also include improved anatomical orientation and cerebrospinal fluid drainage, which facilitate cerebellar retraction.<sup>35</sup> Sufficient irrigation during hematoma removal will not only help to flush out the residual hematoma but will also improve anatomical exposure.<sup>6</sup> Furthermore, failure to remove excess hemostatic materials can prevent proper closure of the cavity and hinder reconnection of the local circuits in the brainstem.<sup>6</sup> Accumulating evidence has suggested that the half-sitting position is especially useful in patients with brainstem lesions, because the assistance of gravity in blood drainage and irrigation from the surgical field allows for cleaner dissection and reduces the need for bipolar coagulation, which could significantly reduce the risk of injury to healthy tissue in the brainstem.<sup>35</sup> These findings indicate that most approaches for the surgical treatment of brainstem lesions can be performed in the half-sitting position without complications.

The present study had some limitations. The present study was retrospective and performed in single institute and by a single surgeon. The number of patients was limited, and all the patients had been in relatively good condition before surgery. In addition, it was difficult to compare the outcomes with what their functional function would have been if the surgery had not been performed.

Owing to the academic controversy, no strong recommendations can be given regarding the therapeutic approach for these patients. However, it is reasonable to attempt surgical removal of a brainstem hematoma in patients with significant brainstem compression and progressively deteriorating clinical features, followed by postoperative medical management for early initiation of rehabilitation strategies.

## CONCLUSIONS

Because of the good results with these 5 patients with PBH, this surgical strategy can be encouraged with exclusion criteria. We hope to increase the number of our patients to accumulate further evidence.

## REFERENCES

1. Freytag E. Fatal hypertensive intracerebral haematomas: a survey of the pathological anatomy of 393 cases. *J Neurol Neurosurg Psychiatry.* 1968;31: 616-620.
2. Komiyama M, Boo YE, Yagura H, Yasui T, Baba M, Hakuba A, et al. A clinical analysis of 32 brainstem haemorrhages; with special reference to surviving but severely disabled cases. *Acta Neurochir (Wien).* 1989;101:46-51.
3. Mangiardi JR, Epstein FJ. Brainstem haematomas: review of the literature and presentation of five new cases. *J Neurol Neurosurg Psychiatry.* 1988;51: 966-976.
4. Manno EM, Atkinson JL, Fulgham JR, Wijdicks EF. Emerging medical and surgical management strategies in the evaluation and treatment of intracerebral hemorrhage. *Mayo Clin Proc.* 2005;80:420-433.
5. Rabinstein AA, Tisch SH, McClelland RL, Wijdicks EF. Cause is the main predictor of outcome in patients with pontine hemorrhage. *Cerebrovasc Dis.* 2004;17:66-71.
6. Shrestha BK, Ma L, Lan Z, Li H, You C. Surgical management of spontaneous hypertensive brainstem hemorrhage. *Interdiscip Neurosurg.* 2015; 2:145-148.
7. Wessels T, Möller-Hartmann W, Noth J, Klötzsch C. CT findings and clinical features as markers for patient outcome in primary pontine hemorrhage. *Am J Neuroradiol.* 2004;25:257-260.
8. Jang JH, Song YG, Kim YZ. Predictors of 30-day mortality and 90-day functional recovery after primary pontine hemorrhage. *J Korean Med Sci.* 2011;26:100-107.
9. Balci K, Asil T, Kerimoglu M, Celik Y, Utku U. Clinical and neuroradiological predictors of

- mortality in patients with primary pontine hemorrhage. *Clin Neurol Neurosurg.* 2005;108:36-39.
10. Dziewas R, Kremer M, Ludemann P, Nabavi DG, Drager B, Ringelstein B. The prognostic impact of clinical and CT parameters in patients with pontine hemorrhage. *Cerebrovasc Dis.* 2003;16:224-229.
  11. Sahni R, Weinberger J. Management of intracerebral hemorrhage. *Vasc Health Risk Manag.* 2007;3:701-709.
  12. Chung CS, Park CH. Primary pontine hemorrhage: a new CT classification. *Neurology.* 1992;42:830-834.
  13. Jeong JH, Yoon SJ, Kang SJ, Choi KG, Na DL. Hypertensive pontine microhemorrhage. *Stroke.* 2002;33:925-929.
  14. Kushner MJ, Bressman SB. The clinical manifestations of pontine hemorrhage. *Neurology.* 1985;35:637-643.
  15. Murata Y, Yamaguchi S, Kajikawa H, Yamamura K, Sumioka S, Nakamura S. Relationship between the clinical manifestations, computed tomographic findings and the outcome in 80 patients with primary pontine hemorrhage. *J Neurol Sci.* 1999;167:107-111.
  16. Takeuchi S, Suzuki G, Takasato Y, Masaoka H, Hayakawa T, Otani N, et al. Prognostic factors in patients with primary brainstem hemorrhage. *Clin Neurol Neurosurg.* 2013;115:732-735.
  17. Wijdicks EF, St. Louis E. Clinical profiles predictive of outcome in pontine hemorrhage. *Neurology.* 1997;49:1342-1346.
  18. Masiyama S, Niizuma H, Suzuki J. Pontine haemorrhage: a clinical analysis of 26 cases. *J Neurol Neurosurg Psychiatry.* 1985;48:658-662.
  19. Jung DS, Jeon BC, Park YS, Oh HS, Chun TS, Kim NK. The predictors of survival and functional outcome in patients with pontine hemorrhage. *J Korean Neurosurg Soc.* 2007;41:82-87.
  20. Hara T, Nagata K, Kawamoto J, Sashida T, Abe T, Wada A, et al. Functional outcome of primary pontine hemorrhage: conservative treatment or stereotaxic surgery. *No Shinkei Geka.* 2001;29:823-829.
  21. Takahama H, Morii K, Sato M, Sekiguchi K, Sato S. Stereotactic aspiration in hypertensive pontine hemorrhage: comparative study with conservative therapy. *No Shinkei Geka.* 1989;17:733-739.
  22. Kothari RU, Brott T, Broderick JP, Barsan WG, Sauerbeck LR, Zuccarello M, et al. The ABCs of measuring intracerebral hemorrhage volumes. *Stroke.* 1996;27:1304-1305.
  23. Morgenstern LB, Hemphill JC III, Anderson C, Becker K, Broderick JP, Connolly ES Jr, et al. American Heart Association Stroke Council; Council on Cardiovascular Nursing. Guidelines for the management of spontaneous intracerebral hemorrhage: a guideline for healthcare professionals from the American Heart Association/American Stroke Association. *Stroke.* 2010;41:2108-2129.
  24. Steiner T, Al-Shahi Salman R, Beer R, Christensen H, Cordonnier C, Csiba L, et al. European Stroke Organisation. European Stroke Organisation (ESO) guidelines for the management of spontaneous intracerebral hemorrhage. *Int J Stroke.* 2014;9:840-855.
  25. Huang KB, Ji Z, Wu YM, Wang SN, Lin ZZ, Pan SY. The prediction of 30-day mortality in patients with primary pontine hemorrhage: a scoring system comparison. *Eur J Neurol.* 2012;19:1245-1250.
  26. Shitamichi M, Nakamura J, Sasaki T, Suematsu K, Tokuda S. Computed tomography guided stereotactic aspiration of pontine hemorrhages. *Stereotact Funct Neurosurg.* 1990;54-55:453-456.
  27. Tao C, Li H, Wang J, You C. Predictors of surgical results in patients with primary pontine hemorrhage. *Turk Neurosurg.* 2016;26:77-83.
  28. Singh TG, Ghalige HS, K K, S A, Devi SR, Singh M, et al. Primary supratentorial haemorrhage—surgery or no surgery in an Indian setup. *J Clin Diagn Res.* 2014;8:NC01-NC03.
  29. Kanaya H, Kuroda K. Intracerebral hematomas. In: Kaufman HH, ed. *Development in Neurosurgical Approaches to Hypertensive Intracerebral Haemorrhage in Japan.* New York, NY: Raven; 1992:197-209.
  30. Little JR, Tubman DE, Ethier R. Cerebellar hemorrhage in adults: diagnosis by computerized tomography. *J Neurosurg.* 1978;48:575-579.
  31. Ye Z, Huang X, Han Z, Shao B, Cheng J, Wang Z, et al. Three-year prognosis of first-ever primary pontine hemorrhage in a hospital-based registry. *J Clin Neurosci.* 2015;22:1133-1138.
  32. Kirillos RW, Tyagi AK, Ross SA, van Hille PT, Marks PV. Management of spontaneous cerebellar hematomas: a prospective treatment protocol. *Neurosurgery.* 2001;49:1378-1386.
  33. Murthy SB, Moradiya Y, Dawson J, Lees KR, Hanley DF, Ziai WC, VISTA-ICH Collaborators. Perihematomal edema and functional outcomes in intracerebral hemorrhage: influence of hematoma volume and location. *Stroke.* 2015;46:3088-3092.
  34. Urday S, Beslow LA, Goldstein DW, Vashkevich A, Ayres AM, Battey TW, et al. Measurement of perihematomal edema in intracerebral hemorrhage. *Stroke.* 2015;46:1116-1119.
  35. Ammirati M, Lamki TT, Shaw AB, Forde B, Nakano I, Mani M. A streamlined protocol for the use of the semi-sitting position in neurosurgery: a report on 48 consecutive procedures. *J Clin Neurosci.* 2013;20:32-34.
  36. Ichimura S, Bertalanffy H, Nakaya M, Mochizuki Y, Fukaya R, Moriwaki G, et al. Improvement of respiratory depression in a patient with primary medullary hemorrhage following removal of hematoma in the half-sitting position. *J Neurol Surg A Cent Eur Neurosurg.* 2018;79:186-190.
  37. Saladino A, Lamperti M, Mangraviti A, Legnani FG, Prada FU, Casali C, et al. The semi-sitting position: analysis of the risks and surgical outcomes in a contemporary series of 425 adult patients undergoing cranial surgery. *J Neurosurg.* 2017;127:867-876.
  38. Bertalanffy H. Avoidance of postoperative acute cerebellar swelling after pineal tumor surgery. *Acta Neurochir (Wien).* 2016;158:59-62.

*Conflict of interest statement: The authors declare that the article content was composed in the absence of any commercial or financial relationships that could be construed as a potential conflict of interest.*

*Received 25 May 2018; accepted 6 September 2018*

*Citation: World Neurosurg.* (2018).

<https://doi.org/10.1016/j.wneu.2018.09.055>

*Journal homepage: [www.WORLDNEUROSURGERY.org](http://www.WORLDNEUROSURGERY.org)*

*Available online: [www.sciencedirect.com](http://www.sciencedirect.com)*

*1878-8750/\$ - see front matter © 2018 Elsevier Inc. All rights reserved.*