


Fetal intracranial hemorrhage due to maternal subclinical vitamin K deficiency associated with long-term eating disorder

Genichiro Sotodate , Atsushi Matsumoto, Yu Konishi, Yukiko Toya, Mikiya Endo and Kotaro Oyama

Department of Pediatrics, Iwate Medical University School of Medicine, Morioka, Japan

Abstract

Vitamin K deficiency in pregnant women causes intracranial hemorrhage (ICH) in fetuses. Fetal ICH frequently causes life-threatening and persistent neurological damage. However, indicators for preventing fetal ICH are not established. Two pregnant women developed long-term eating disorders caused by psychosis. They were administered intravenous fluid and vitamin supplementation, excluding vitamin K. The intracranial low-hypoechoic area on fetal ultrasound was suggestive of fetal ICH due to vitamin K deficiency. Their neonates showed severe developmental delay. Laboratory analysis revealed a normal prothrombin time, but elevated protein induced by vitamin K absence II. Pregnant women who have eating disorders more than 3 weeks could develop fetal ICH due to maternal subclinical vitamin K deficiency. Illness duration and protein induced by vitamin K absence II of pregnant woman may be indicators for vitamin K administration to prevent fetal intracranial hemorrhage.

Key words: eating disorder, fetus, intracranial hemorrhage, PIVKA-II, vitamin K deficiency.

Introduction

Fetal intracranial hemorrhage (ICH) is caused by thrombocytopenia purpura, coagulation disorder, trauma, drug use and vitamin K deficiency in pregnant women.¹ Placental transfer of vitamin K is poor; thus, vitamin K concentration in the cord blood is about 1/30 of the maternal plasma.^{2,3} Particularly, neonates have a risk of vitamin K deficiency bleeding because they have immature intestinal flora and human milk is a poor vitamin source. This could lead to death or severe developmental delay once ICH occurs; hence, newborns should receive vitamin K prophylaxis.

In Japan, pregnant women taking drugs inhibiting vitamin K metabolism or intestinal absorption are recommended to take vitamin K from 36 gestational weeks until labor onset. Vitamin K deficiency can

develop to fetal ICH before 36 gestational weeks.⁴⁻⁹ Fetal ICH is rare; however, it is life threatening and persistent neurological damage is frequent in survivors.^{1,10} Eating disorders in pregnant women are risk factors for vitamin K deficiency; they are often associated with hyperemesis, but they usually do not develop to fetal ICH. However, indicators for preventing fetal ICH have not been established. Here, we describe two cases of fetal ICH due to maternal subclinical vitamin K deficiency. Informed consent was obtained from the parents for publication of this case report.

Case Report

Case 1

A 27-year-old woman (gravida 5, para 2) was admitted to our hospital with a complaint of eating

Received: May 24 2018.

Accepted: September 3 2018.

Correspondence: Genichiro Sotodate, Department of Pediatrics, Iwate Medical University School of Medicine, 19-1 Uchimaru, Morioka, Iwate 020-8505, Japan. Email: gsotodat@iwate-med.ac.jp

disorders at 10 gestational weeks. Her first pregnancy resulted in a stillborn due to placental abruption at 25 weeks. During her second pregnancy, she gave birth at 37 weeks. Her third pregnancy was a spontaneous abortion. She had artificial abortions during her fourth and fifth pregnancies due to a mental health condition. A psychiatrist diagnosed her with somatoform disorder at age 25. She was administered intravenous fluid, which contained standard commercial combinations of vitamins B₁, B₆, B₁₂ and C from 10 gestational weeks, excluding vitamin K. Her weight was 60 kg at 10 weeks but decreased to 44 kg at 26 weeks. Fetal biparietal diameter (BPD) was 62.6 mm (−0.6 standard deviation [SD]) at 26w 0d, suddenly increased to 73.2 mm (+2.0 SD) and bilateral intracranial low hypoechoic areas were shown in a fetal ultrasound at 26w 5d (Fig. 1). Her mental state worsened, thus an emergency cesarean section was performed at 29 weeks. The following are the characteristics of the female neonate at birth: weight, 766 g (0.4 percentile); length, 32.0 cm (0.5 percentile); head circumference, 25.2 cm (24.8 percentile); and Apgar score, 1 and 6 at 1 and 5 min, respectively. The neonate was immediately intubated and started on mechanical ventilation. Brain ultrasound at birth showed bilateral hypoechoic space, suggestive of subdural hemorrhage (SDH). Laboratory analysis revealed the following: hemoglobin, 7.7 g/dL; hematocrit, 27.5%; platelet count, 391 000/μL; international normalized ratio of prothrombin time (PT-INR), 2.64;

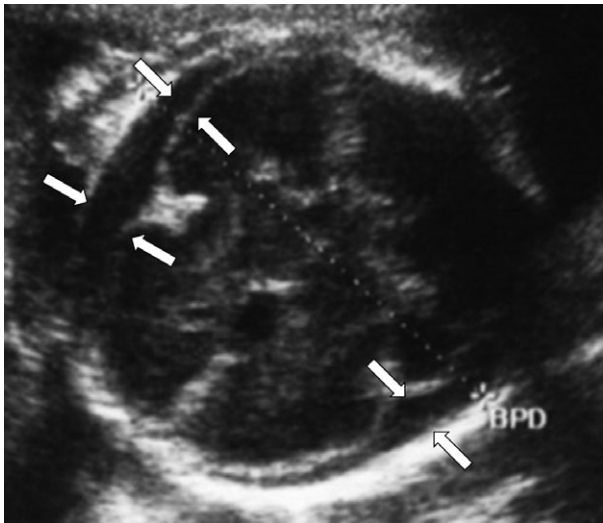


Figure 1 Transverse sonogram showed enlarged biparietal diameter at 26 weeks. Arrows indicate subdural hemorrhage.

activated partial thrombin time, greater than 300 s; fibrinogen, 138 mg/dL; and protein induced by vitamin K absence II (PIVKA-II), 19 267 mAU/L (reference: <40). PIVKA-II was elevated owing to vitamin K deficiency. Since PT-INR improved to 1.45 after vitamin K injection, the neonate was diagnosed as having fetal ICH due to vitamin K deficiency. Red blood cell and fresh frozen plasma (FFP) transfusions were performed. We transfused FFP until day 3 and vitamin K was administered and decreased gradually until day 33. The intracranial hematoma disappeared at day 30. Coagulation test results of the neonate were normal after discontinuation of vitamin K and FFP.

Postoperative coagulation test results of the mother revealed normal PT-INR (0.86) and elevated PIVKA-II (73 mAU/mL). Thrombocytopenia or other abnormal findings were not observed. She had no history of trauma during pregnancy and was not taking drugs that inhibit vitamin K metabolism. Her eating disorder was caused by a somatoform disorder, which improved during the post-partum period.

The neonate survived, but had severe neurological sequel. At age 3, the child's developmental quotient was evaluated using the Kyoto Scale of Psychological Development with a resulting score of 57, which was categorized as severe developmental delay. Head magnetic resonance imaging (MRI) at 4 years showed no abnormality other than mild ventricular enlargement.

Case 2

A 31-year-old woman (2 gravida, 0 para) was diagnosed as having attention deficit hyperactivity disorder and anxiety disorder. She had an artificial abortion on her first pregnancy due to social reasons. Initially, she was admitted to a different hospital due to episodes of vomiting at seven gestational weeks and was administered intravenous fluid containing vitamins B₁ and B₆, excluding vitamin K. She also had an eating disorder; she was 70 kg at seven gestational weeks but weighed 59 kg at 28 weeks. BPD was 64.4 mm (+0.9 SD) at 25w 0d, suddenly increased to 75.2 mm (+2.7 SD) and the fetal ultrasound scans showed bilateral intracranial low hypoechoic lesions, suggestive of ICH, at 26w 5d (Fig. 2). She was then transferred to our hospital at 28w 6d. Laboratory tests revealed that no thrombocytopenia, normal PT-INR (1.08), elevated PIVKA-II (1391 mAU/mL), and decreased vitamin K (<0.05 ng/mL; reference: 0.15–1.25), suggestive of vitamin K deficiency. She had no history of trauma during pregnancy and was

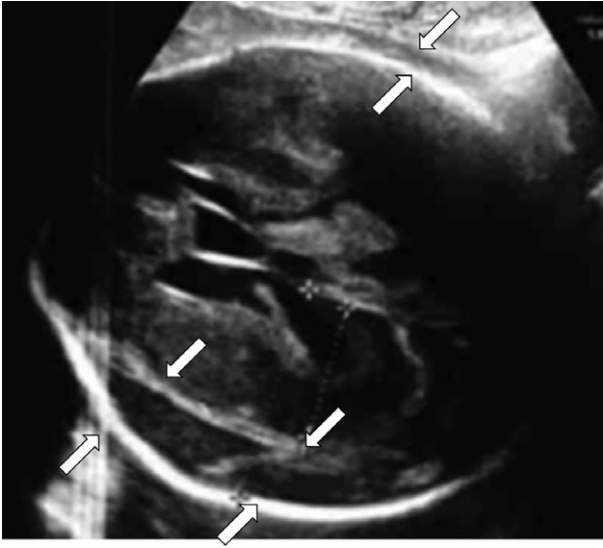


Figure 2 Transverse sonogram showed enlarged biparietal diameter at 26 weeks. Arrows indicate subdural hemorrhage.

not taking drugs that inhibit vitamin K metabolism. She was administered vitamin K, but BPD increased to 93.4 mm (+6.1 SD). Fetal cardiotocography showed a sinusoidal pattern; therefore, emergency cesarean section was performed.

The female neonate had the following characteristics at birth: birth weight, 1346 g (74.2 percentile); height, 38.5 cm (62.1 percentile); head circumference, 31.1 cm (99.9 percentile); and Apgar score, 1 and 5 at 1 and 5 min, respectively. She was immediately intubated and started on mechanical ventilation. Blood analysis of the neonate revealed the following: hemoglobin, 3.3 g/dL; hematocrit, 12.0%; platelet count, 204 000/ μ L; PT-INR, 1.92; activated partial thrombin time, 83.5 s; fibrinogen, 196 mg/dL; and PIVKA-II, 58 924 mAU/L. Brain ultrasound showed bilateral low echoic lesions, suggestive of SDH. She was diagnosed as having fetal ICH due to vitamin K deficiency. As the neonate's anemia was severe with ICH, red blood cell and FFP transfusions were performed. We transfused FFP until day 10; vitamin K was administered and decreased gradually until day 15. The intracranial hematoma disappeared at day 20. Coagulation tests showed normal results after vitamin K and FFP discontinuation. At age 10 months, head computed tomography showed multifocal ischemic brain necrosis, and she had spasticity.

The mother's frequent episodes of vomiting, caused by anxiety disorders during pregnancy, improved post-partum.

Discussion

Our two cases with complications of fetal ICH had no hemorrhagic symptoms; their blood analysis revealed normal PT and elevated PIVKA-II. Pregnant women with long-term eating disorders could develop fetal ICH due to maternal subclinical vitamin K deficiency.

Moreover, six pregnant women with fetal ICH due to maternal vitamin K deficiency have been reported in the literature (Table 1).⁴⁻⁹ The causes of vitamin K deficiency were Crohn disease (one patient) and eating disorders (seven patients; after bariatric surgery in one, hyperemesis gravidarum in two, magnesium sulfate in one, esophageal hiatal hernia in one, anxiety disorders in one, and somatoform disorders in one). Among these eight women, only two of six had prolonged PT; however, five of five patients whose PIVKA-II was measured had elevated PIVKA-II levels. A diagnosis of vitamin K deficiency is considered in patients with prolonged PT in the presence of normal platelet count and normal fibrinogen level. The most useful confirmatory test is the restoration of normal PT by vitamin K administration.³ PT becomes prolonged only when prothrombin concentration drops about 50% less of the normal value; thus PT is insensitive for determining subclinical vitamin K deficiencies.² In contrast, PIVKA-II is a functional marker of vitamin K deficiency,² and is proven to be useful in detecting subclinical vitamin K deficiency in neonates² and fetal ICH due to vitamin K deficiency in pregnant women.

Our two cases lost weight because of their mental health conditions, and received intravenous alimentation and vitamin supplementation, but excluding vitamin K. Pregnant women using drugs that inhibit vitamin K metabolism and intestinal absorption or those on long-term total parenteral nutrition are at high risk for vitamin K deficiency; thus, they should take 90 μ g/day of vitamin K.¹¹ Evaluation of sufficient levels of vitamin K in pregnant women with eating disorders is necessary. In addition, periodic ultrasound examinations are needed for these women to early detect fetal ICH.

Fetal ICH often results in neurologic impairment even if fetal ICH improved before birth⁸; thus, prevention of fetal ICH is necessary. Fetal ICH may be prevented through vitamin K supplementation to pregnant women, but its interval and dosage have not been established. Excessive administration of vitamin K may be detrimental to fetuses.¹¹

Table 1 Detail of pregnant women with fetal intracranial hemorrhage due to maternal vitamin K deficiency

| Author | GW at diagnosis | Maternal complication | Type of hemorrhage | Pregnant woman | | Neonate | | |
|----------|-----------------|--------------------------|--------------------|------------------|------------------|---------------|------------------|------------------|
| | | | | PT (s) or PT-INR | PIVKA-II (mAU/L) | GW at birth | PT (s) or PT-INR | PIVKA-II (mAU/L) |
| Case 1 | 26 | Somatiform disorders | SDH | 0.86 | 73 | 29 | 2.64 | 19 267 |
| Case 2 | 28 | Anxiety disorders | SDH | 1.08 | 1391 | 28 | 1.92 | 58 624 |
| Hirose | 28 | Crohn's disease | SDH | NA | 4380 | 36 | Normal | Normal |
| Sakai | 31 | Esophageal hiatal hernia | SDH | 10.5 (s) | 85 | 31 | 14.7 (s) | 71 232 |
| Minami | 28 | Magnesium sulfate | ICH | 2.11 | 73 700 | 40 | NA | NA |
| Mighem | 31 | After bariatric surgery | ICH + SAH | 12 (s) | NA | 31 | 75 (s) | NA |
| Kawamura | 17 | Hyperemesis gravidarum | ICH + SAH | 28% of normal | NA | 20 (abortion) | NA | NA |
| Friedman | 32 | Hyperemesis gravidarum | ICH + SDH | NA | NA | 32 | 45 (s) | NA |

GW, gestational weeks; ICH, intracerebral hemorrhage; NA not available; PT (s), prothrombin time (second); PT-INR, international normalized ratio of prothrombin time; PIVKA-II, protein induced by vitamin K absence II; SAH, subarachnoidal hemorrhage; SDH, subdural hemorrhage.

Eating disorders and vomiting in pregnant women are commonly associated with hyperemesis, but they usually do not develop to fetal ICH. In previous reports of vitamin K deficiency caused fetal ICH,⁴⁻⁹ maternal eating disorder or reduced intestinal absorption of vitamin K lasted for more than 3 weeks. Pregnant women with eating disorders more than 3 weeks could develop fetal ICH due to maternal subclinical vitamin K deficiency. Illness duration and PIVKA-II may be indicators for vitamin K administration and predictors of fetal ICH.

Fetal ICH due to maternal vitamin K deficiency might have higher proportion of SDH than other causes¹ (Table 1). The reason is uncertain. SDH in the neonatal period is most commonly a traumatic lesion. In maternal vitamin K deficiency, fetal ICH may develop even if tiny trauma occurs.

In pregnant women with long-term eating disorders, fetal ICH may occur due to maternal subclinical vitamin K deficiency. If pregnant women have a high risk of vitamin K deficiency, PIVKA-II and illness duration may be indicators for vitamin K administration to prevent fetal ICH.

Disclosure

None.

References

- Ghi T, Simonazzi G, Perolo A *et al.* Outcome of antenatally diagnosed intracranial hemorrhage: Case series and review of the literature. *Ultrasound Obstet Gynecol* 2003; **22**: 121–130.
- Shearer MJ. Vitamin K deficiency bleeding (VKDB) in early infancy. *Blood Rev* 2009; **23**: 49–59.
- Van Winckel M, De Bruyne R, Van De Velde S, Van Biervliet S. Vitamin K, an update for the paediatrician. *Eur J Pediatr* 2009; **168**: 127–134.
- Sakai M, Yoneda S, Sasaki Y, Saito S. Maternal total parenteral nutrition and fetal subdural hematoma. *Obstet Gynecol* 2003; **101**: 1142–1144.
- Van Mieghem T, Van Schoubroeck D, Depiere M, Debeer A, Hanssens M. Fetal cerebral hemorrhage caused by vitamin K deficiency after complicated bariatric surgery. *Obstet Gynecol* 2008; **112**: 434–436.
- Kawamura Y, Kawamata K, Shinya M, Higashi M, Niuro M, Douchi T. Vitamin K deficiency in hyperemesis gravidarum as a potential cause of fetal intracranial hemorrhage and hydrocephalus. *Prenat Diagn* 2008; **28**: 59–61.
- Eventov-Friedman S, Klinger G, Shinwell ES. Third trimester fetal intracranial hemorrhage owing to vitamin K deficiency

- associated with hyperemesis gravidarum. *J Pediatr Hematol Oncol* 2009; **31**: 985–988.
8. Minami H, Furuhashi M, Minami K, Miyazaki K, Yoshida K, Ishikawa K. Fetal intraventricular bleeding possibly due to maternal vitamin K deficiency. *Fetal Diagn Ther* 2008; **24**: 357–360.
 9. Hirose M, Akiyama M, Takakura K, Noda Y. Active Crohn disease with maternal vitamin K deficiency and fetal subdural hematoma. *Obstet Gynecol* 2001; **98**: 919–921.
 10. Kutuk MS, Yikilmaz A, Ozgun MT *et al*. Prenatal diagnosis and postnatal outcome of fetal intracranial hemorrhage. *Childs Nerv Syst* 2014; **30**: 411–418.
 11. Shearer MJ. Vitamin K in parenteral nutrition. *Gastroenterology* 2009; **137**: S105–S118.