

# Aneurysmal dilation of the vein of Galen and straight sinus with resultant obstructive hydrocephalus

Faiza Jamil,<sup>1</sup> Hajira Farooq Khan,<sup>2</sup> Iftikhar Ahmad,<sup>3</sup> Faiz Anwer<sup>1</sup>

<sup>1</sup>Hematology Oncology, University of Arizona Medical Center, Tucson, Arizona, USA  
<sup>2</sup>Radiology, Khyber Teaching Hospital, Peshawar, Pakistan  
<sup>3</sup>Neuroradiology, IUPUI, Indianapolis, Indiana, USA

## Correspondence to

Dr Faiz Anwer,  
 anwerf@email.arizona.edu

Accepted 7 September 2018

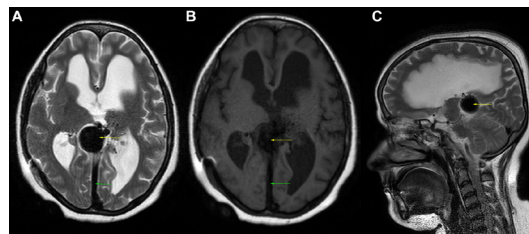
## DESCRIPTION

A 20-year-old woman was admitted to the emergency department on a previous occasion with tonic-clonic seizures. Her medical history was significant for headaches and hypertension. The headaches were associated with nausea and vomiting. She had no history of developmental delay or epilepsy. CT scan of the brain showed signs of obstructive hydrocephalus due to venous hypertension as a result of vein of Galen malformation, and hence a ventriculo-peritoneal shunt was placed. Now on follow-up, her MRI brain demonstrates a round flow void in the suprapineal cisterns with engorged straight sinus, compatible with vein of Galen arteriovenous fistulous communication and shunting (figure 1). The resultant venous hypertension leads to mild to moderate compensated hydrocephalus.

Vein of Galen aneurysm (VGA) is an unusual pathology, typically found in children, accounting for less than 1% of all the intracranial vascular malformations.<sup>1</sup> It originates from persistent arteriovenous shunting from primitive choroidal vessels into the median prosencephalic vein of Markowski, the embryonic precursor of the vein of Galen.<sup>2</sup> It is commonly diagnosed in neonates or children, with signs and symptoms of heart failure, macrocephaly and cranial murmurs.<sup>3</sup>

Common presentation in adults includes headaches, hydrocephalus, seizures, rounded calcified masses in the pineal region and fistulas which change blood flow in the dural sinuses.<sup>3</sup> Blood flow reorganisation to pial veins can lead to subarachnoid and intracerebral haemorrhages. Despite many studies, there is still little known about this disease in adults.

Vascular association between the cerebral venous system and fistula is demonstrated by cerebral angiography, which is the gold standard for the



**Figure 1** (A) Axial T2, (B) axial T1 and (C) sagittal T2 MRI brain. MRI brain demonstrates a round flow void in the suprapineal cisterns with engorged straight sinus (green arrow), compatible with vein of Galen (yellow arrow) arteriovenous fistulous communication and shunting. The resultant venous hypertension leads to mild to moderate compensated hydrocephalus.

## Patient's perspective

The operation has changed things for me. I can now manage to do my daily activities, which I had stopped doing due to the severity of my problems. I no longer spend the major portion of my day in bed. The sleepiness has gone, there is an improvement in my mood. The feeling of fullness in my head and blurring eyesight has shown improvement. I keep visiting my doctor. According to the latest scans, they have seen an improvement in my condition. I was amazed to find out that, I have a vessel malformation which has led to this and has been there my entire life. At least the excessive fluid in my brain led to finding it. Now we know what is causing all the problems.

## Learning points

- ▶ Vein of Galen aneurysm is a rare finding to be diagnosed in adults.
- ▶ Common presentation in adults includes headaches, hydrocephalus, seizures, rounded calcified masses in the pineal region and fistulas which change blood flow in the dural sinuses.
- ▶ Blood flow reorganisation to pial veins can lead to subarachnoid and intracerebral haemorrhages.
- ▶ Cerebral angiography is the gold standard for the diagnosis of vein of Galen malformation.
- ▶ Intravascular embolisation is the treatment of choice in adults, but carries a risk of permanent neurological disability.

diagnosis of VGA. Intravascular embolisation is the treatment of choice in adults, but carries a risk of permanent neurological disability.<sup>2</sup>

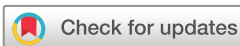**Contributors** FJ contributed as the first author. FJ, HFK, IA and FA planned and designed the study. FJ, HFK and IA searched for the relevant studies. FJ and HFK developed the manuscript. IA helped with the interpretation of the image. FA helped with the final edits. FA is the senior author of this manuscript and serves as the corresponding author.

**Funding** The authors have not declared a specific grant for this research from any funding agency in the public, commercial or not-for-profit sectors.

**Competing interests** None declared.

**Patient consent** Obtained.

**Provenance and peer review** Not commissioned; externally peer reviewed.



© BMJ Publishing Group Limited 2018. No commercial re-use. See rights and permissions. Published by BMJ.

**To cite:** Jamil F, Khan HF, Ahmad I, et al. *BMJ Case Rep* Published Online First: [please include Day Month Year]. doi:10.1136/bcr-2018-226742

## REFERENCES

- 1 Hosmann A, El-Garci A, Gatterbauer B, *et al*. Multimodality management of vein of galen malformations-an institutional experience. *World Neurosurg* 2018;112:e837–47.
- 2 Moizuddin M, Graham B, Owens W. 1126: vein of galen malformation in adult-management dilemma in intensive care unit. *Critical Care Medicine* 2013;41:A285.
- 3 Recinos PF, Rahmathulla G, Pearl M, *et al*. Vein of Galen malformations: epidemiology, clinical presentations, management. *Neurosurg Clin N Am* 2012;23:165–77.

Copyright 2018 BMJ Publishing Group. All rights reserved. For permission to reuse any of this content visit <http://group.bmj.com/group/rights-licensing/permissions>.  
BMJ Case Report Fellows may re-use this article for personal use and teaching without any further permission.

Become a Fellow of BMJ Case Reports today and you can:

- ▶ Submit as many cases as you like
- ▶ Enjoy fast sympathetic peer review and rapid publication of accepted articles
- ▶ Access all the published articles
- ▶ Re-use any of the published material for personal use and teaching without further permission

For information on Institutional Fellowships contact [consortiasales@bmjgroup.com](mailto:consortiasales@bmjgroup.com)

Visit [casereports.bmj.com](http://casereports.bmj.com) for more articles like this and to become a Fellow