

Uneventful Pregnancy and Delivery after Thrombolysis Plus Thrombectomy for Acute Ischemic Stroke: Case Study and Literature Review

Toshiyuki Tony Watanabe, MD,MPH, Masahiko Ichijo, MD,PhD, and Tomoyuki Kamata, MD,PhD

Background: Intravenous thrombolysis with recombinant tissue plasminogen activator and endovascular mechanical thrombectomy are known to be the most effective treatments in the acute phase of ischemic stroke. However, the safety of intravenous systemic thrombolysis with recombinant tissue plasminogen and endovascular mechanical thrombectomy during pregnancy is not well-confirmed. We describe a case of an uneventful pregnancy and delivery after thrombolysis plus endovascular mechanical thrombectomy for acute ischemic stroke. *Materials and Methods:* The patient's medical records were reviewed retrospectively. A comprehensive systemic literature search of the PubMed database was conducted. *Case Presentation:* A 36-year-old woman at 21 weeks gestation presented with a sudden headache, dysarthria, and right hemiparesis. Magnetic resonance angiography revealed occlusion of the left internal carotid artery. Recombinant tissue plasminogen activator was administered intravenously 193 minutes after symptom onset, and endovascular mechanical thrombectomy was started immediately. Recanalization of her left internal carotid artery was achieved. The patient continued to experience mild hemiparesis after the initial treatment and started rehabilitation. The fetus remained in satisfactory condition during the pregnancy and was delivered at 38 weeks without obvious maternal or neonatal complications. No apparent abnormality has been observed in the newborn in the first year of life. *Conclusions:* Intravenous recombinant tissue plasminogen and endovascular mechanical thrombectomy could be considered as treatment for acute ischemic stroke during pregnancy unless high risks of hemorrhage or preterm labor are expected.

Key Words: Ischemic stroke—pregnancy—intravenous thrombolysis—mechanical thrombectomy

© 2018 National Stroke Association. Published by Elsevier Inc. All rights reserved.

Introduction

The incidence of stroke during the antenatal/perinatal period is reported to be 18.3 per 100,000 pregnancies.¹ Currently, intravenous thrombolysis with recombinant tissue plasminogen activator (rt-PA) and endovascular mechanical

thrombectomy (EMT) are known to be the most effective treatments in the acute phase of ischemic stroke. Notably, the current Japanese guideline for intravenous thrombolysis does not list pregnancy as a contraindication to intravenous administration of rt-PA (alteplase).² However, the guideline from the American Heart Association includes pregnancy as a relative exclusion criterion for intravenous rt-PA administration.³ A few articles have reported cases in which pregnant women were treated with EMT^{4,5}; however, there is even less information on the use of EMT devices in pregnancy than for intravenous thrombolysis.

Materials and Methods

The patient's medical records and images were reviewed retrospectively. A systematic literature search in PubMed was then conducted using the following words:

From the Department of Neurology, Japanese Red Cross Musashino Hospital, Musashino, Tokyo, Japan.

Received May 5, 2018; revision received August 21, 2018; accepted September 2, 2018.

Grant support: None.

Address correspondence to Toshiyuki Tony Watanabe, MD, MPH, Department of General Internal Medicine, Asahi General Hospital, 1326 I, Asahi, Chiba 289-2511, Japan. E-mail: tonynuro@tmd.ac.jp

1052-3057/\$ - see front matter

© 2018 National Stroke Association. Published by Elsevier Inc. All rights reserved.

<https://doi.org/10.1016/j.jstrokecerebrovasdis.2018.09.002>

“pregnancy,” “stroke,” “thrombectomy,” and “tissue plasminogen activator.”

Case Presentation

A 36-year-old woman was admitted to our hospital at 21 weeks gestation with a sudden headache and subsequent dysarthria and right hemiparesis. A head computed tomography scan showed no signs of hemorrhagic stroke. Magnetic resonance imaging revealed a high intensity area on diffusion-weighted images at the posterior limb of the left internal capsule, which is in the territory of the left anterior choroidal artery from the left internal carotid artery (ICA; Fig 1 A), but no cerebral microbleeds were observed on T2-star-weighted images. Magnetic resonance angiography (MRA) revealed an occlusion of the left ICA (Fig 1 B). The patient's pregnancy was stable, and there was no risk of hemorrhage or signs of premature labor. As there were no contraindications, rt-PA was administered intravenously 193 minutes after symptom onset. The dose of rt-PA was 0.6 mg/kg body weight, administered over 60 minutes as a 10% bolus and 90% infusion according to the guideline.² EMT with local anesthesia was started immediately. At first, the operators confirmed left C2 segment occlusion (Fig 1 C) and used the Penumbra system (Penumbra, Inc., Alameda, CA) to aspirate the clot. However, the patient's body movement became more restless, and they could not identify the position of the tip of the catheter. They then found that the Penumbra system went into the M1 segment of the left middle cerebral artery, and they could not aspirate any clot. Angiography showed recanalization of her left ICA (thrombolysis in cerebral infarction grade 2B:

complete filling of all expected vascular territories was visualized, but the filling was slower than normal); however, a stenosis in the left middle cerebral artery M1 segment was revealed (Fig 1 D). The stenosis was thought to be iatrogenic dissection or vasospasm by the device or a residual clot. Angiography showed perforators from the M1 stenosis area; thus, the operators thought that the cause for stenosis might be a residual clot. However, the stenosis did not resolve on using the Trevo Xp device (Stryker Corporation, Kalamazoo, MI); therefore, they terminated the procedure. The patient's abdomen was protected by a lead protector during head computed tomography scanning and the endovascular procedure. The patient had a National Institute of Health Stroke Scale score of 13 at admission and 4 after the procedure.

Post-treatment, the patient had slight residual dysarthria and mild hemiparesis and started rehabilitation on day 2. Blood tests indicated no coagulopathy or autoimmune disease. She was initially treated with a continuous heparin infusion based on the provisional diagnosis of paradoxical embolism; however, transthoracic echocardiography showed no septal abnormalities or a right to left shunt, and Holter monitoring recorded no atrial fibrillation. Therefore, administration of 100 mg aspirin was started on day 11. The stenosis of the M1 segment, which remained after EMT (Fig 1 E), was found to be gradually improving on a follow-up magnetic resonance imaging/MRA and was no longer evident on the MRA obtained on day 106 (Fig 1 F).

Aspirin administration was stopped on day 105 and replaced with subcutaneous heparin injection in preparation for the delivery. The heparin injection was stopped before rehospitalization for delivery on day 120. The fetus

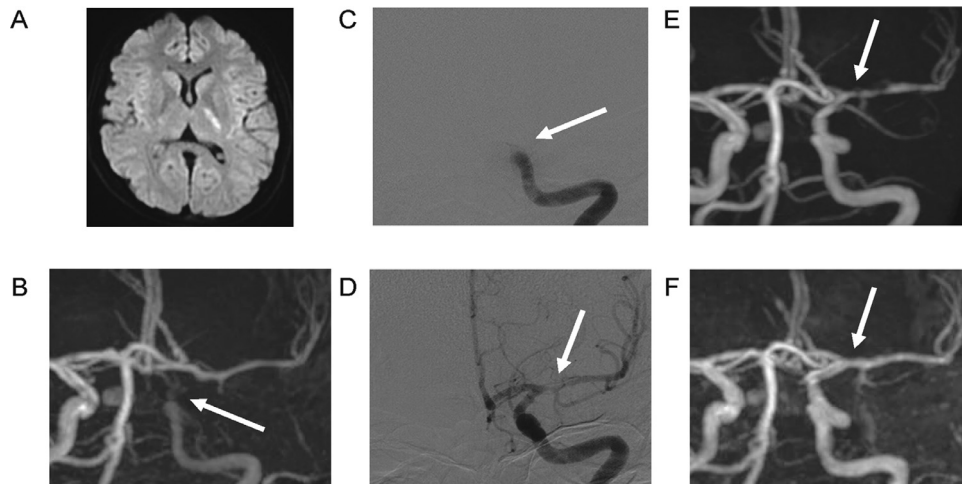


Figure 1. (A) Head diffusion-weighted magnetic resonance imaging at symptom onset showing a high intensity area in the left posterior limb of the internal capsule. (B) MRA before the rt-PA/EMT treatment also showing occlusion of the left ICA. (C) Angiography before EMT shows an occlusion of the left ICA. (D) Angiography after EMT showing recanalization of the left ICA and stenosis of left M1 segment. (E) MRA on day 9 showing the remaining stenosis of the left M1 segment. (F) MRA on day 106 showing that the stenosis had disappeared. Abbreviations: EMT, endovascular mechanical thrombectomy; ICA, internal carotid artery; MRA, magnetic resonance angiogram; rt-PA, recombinant tissue plasminogen activator.

Table 1. Cases of intravenous rt-PA and/or EMT for ischemic stroke during pregnancy.

References	Year	Treatment	Maternal age	Gestational weeks	Infarct location	NIHSS	Time to rt-PA	Hemorrhage	Maternal outcome	Fetal outcome	Stroke etiology
Dapprich et al ⁶	2002	rt-PA	31	12 wk	Left MCA	N/A	170 min	Small left basal ganglia	Recovered almost completely	Healthy	Protein S deficiency
Murugappan et al ⁷	2006	rt-PA	37	12 wk	Right MCA	19	<180 min	Intrauterine hematoma	Recovered well	Medical termination of pregnancy	Mitral valve replacement
Murugappan et al ⁷	2006	rt-PA	31	4 wk	Left MCA	N/A	180 min	None	Recovered well	Medical termination of pregnancy	Protein S deficiency
Murugappan et al ⁷	2006	rt-PA	29	6 wk	Right MCA	13	<180 min	Intracranial	Died	Died due to maternal death	Aortal valve replacement
Wiese et al ⁸	2006	rt-PA	33	13 wk	Left MCA	13	N/A	None	Improved to NIHSS 4 points	Healthy	Mitral valve replacement
Leonhardt et al ⁹	2006	rt-PA	26	23 wk	Left MCA	N/A	N/A	None	Good improvement	Healthy	Antiphospholipid syndrome
Yamaguchi et al ¹⁰	2010	rt-PA	36	18 wk	Left MCA	6	193 min	None	mRS=1 after 15 days	Healthy	Factor VIII elevation
Tassi et al ¹¹	2013	rt-PA	28	16 wk	Left MCA	20	N/A	None	Improved to NIHSS 1 point	Healthy	PFO, Factor V Leiden deficiency
Hori et al ¹²	2013	rt-PA	35	14 wk	Right PCA	N/A	175 min	None	Improved to NIHSS 1 point	Healthy	Protein S deficiency
Mantoan Ritter et al ¹³	2014	rt-PA	32	36 wk	Left MCA	22	<120 min	None	final mRS=2	Healthy	Cryptogenic
Ritchie et al ¹⁴	2015	rt-PA	28	39 wk	Right MCA	11	<120 min	None	Full recovery	Healthy	Cryptogenic
Tversky et al ¹⁵	2016	rt-PA	31	5 wk	Left MCA	5	N/A	None	Full recovery	Pregnancy ongoing	Protein C/S deficiency, PFO
Reining-Festa et al ¹⁶	2017	rt-PA	37	5 wk	Right MCA	8	92 min	None	mRS=1 after 3 months	Healthy	Post-rheumatic aortic valve disease
Aaron S et al ⁴	2016	EMT	24	3rd trimester	Right MCA	20		None	mRS=0 after 6 months	Healthy	Mitral valve replacement
Aaron S et al ⁴	2016	EMT	28	37 wk	Right MCA	21		None	mRS=2 after 6 months	Healthy	Mitral valve replacement

(continued on next page)

Table 1 (Continued)

References	Year	Treatment	Maternal age	Gestational weeks	Infarct location	NIHSS	Time to rt-PA	Hemorrhage	Maternal outcome	Fetal outcome	Stroke etiology
Bhogal et al ⁵	2017	EMT	38	24 wk	Left MCA	15		None	mRS=1 after 8 years	Healthy	Previous drug abuse
Bhogal et al ⁵	2017	rt-PA+EMT	36	25 wk	Basilar artery	N/A	N/A	None	mRS=1 after 1 days	Pregnancy ongoing	Reconstruction of ascending aorta
Our case	2018	rt-PA+EMT	36	21 wk	Left ICA	13	193 min	None	mRS=1 after 6 months	Healthy	Cryptogenic

Abbreviations: EMT, endovascular mechanical thrombectomy; MCA, middle cerebral artery; mRS, modified Rankin scale; N/A, not available; NIHSS, National Institute of Health Stroke Scale; PCA, posterior cerebral artery; PFO, patent foramen ovale; rt-PA, recombinant tissue plasminogen activator.

remained in satisfactory condition during the pregnancy and was delivered at 38 weeks and 4 days (day 121 from symptom onset). The Apgar scale was 9 points at 1 minute and 9 points at 5 minutes after birth. The delivery was without obvious maternal or neonatal complications, and no apparent abnormality has been observed in the baby in the first year of life. The modified Rankin Scale of the mother was 1 after the delivery.

Discussion

To our knowledge, this is the first report of a pregnant patient with acute ischemic stroke (AIS) being treated with both rt-PA and EMT and with successful maternal and fetal outcomes and no intrapartum complications. Two recent studies^{4,5} reported the use of EMT treatment in 4 cases of AIS during pregnancy, with EMT treatment alone being used in 3 of the 4 cases (Table 1). In the fourth case, rt-PA and EMT treatment was used;⁵ however, the maternal and neonatal outcome during and after delivery was not mentioned in the article.

To date, there have been 13 reported cases of thrombolysis with rt-PA.⁶⁻¹⁶ In 3 cases, EMT without rt-PA was used,^{4,5} and in 2 cases (including our case), rt-PA and EMT treatment was used (Table 1).⁵ Among the 13 cases of thrombolysis with rt-PA during pregnancy,⁶⁻¹⁶ clinical improvement was observed in 10,⁷⁻¹⁶ hemorrhagic complications in the brain in 1,⁶ intrauterine hematoma in 1,⁷ and death due to dissection during subsequent angioplasty in 1.⁷ Nine fetuses were healthy,^{6,8-14,16} 2 pregnancies were medically terminated,⁷ 1 fetus died owing to maternal death,⁷ and 1 pregnancy was ongoing.¹⁵ The 3 cases treated with EMT and without rt-PA were reported to have good maternal and neonatal outcomes.^{4,5} Among the 2 cases (including our case) in which both rt-PA and EMT treatment were used during pregnancy, our case showed good maternal and neonatal outcomes, and in the other case, pregnancy was reported as ongoing.⁵

In our case, the most probable etiology for stroke was vasospasm of the left C2 segment because dysarthria and right hemiparesis at symptom onset coincided with a severe headache. She had no significant past medical history (including arteriosclerotic diseases) except migraine, and her laboratory data showed no significant findings related to ischemic stroke. We assumed that vasospasm of the left ICA led to secondary intravascular thrombus formation, which caused occlusion at the site. However, the cause for the C2 vasospasm was undetermined. We are uncertain whether the vasospasm was related to the patient's migraine because the past medical history of migraine was self-reported. M1 stenosis was thought to be due to an iatrogenic dissection or vasospasm caused by the endovascular procedure itself because the initial MRA (Fig 1 B) did not show stenosis, and the stenosis seemed to appear after the procedure. This may be consistent with the fact that M1 stenosis was reversible and

spontaneously improved within several months (Fig 1 D-F).

Currently, intravenous thrombolysis with rt-PA administration and EMT is becoming the standard treatment for the acute phase of ischemic stroke. However, rt-PA is classified under Pregnancy Category C (animal reproduction studies have shown an adverse effect on the fetus, and although there are no adequate and well-controlled studies in humans, potential benefits may warrant use of the drug in pregnant women despite potential risks) by the United States Food and Drug Administration,¹⁷ and the pivotal stroke trials of both the Penumbra and Trevo devices did not recruit pregnant patients.^{18,19} Rt-PA administered intravenously does not cross the placenta,¹⁷ and a teratogenic effect has not been proven.²⁰ Maternal hemorrhagic complications have been reported in 8% of cases with systemic thrombolysis.²¹ If the additional risk due to pregnancy is estimated to be small, systemic thrombolysis with rt-PA and EMT could be performed according to the normal inclusion/exclusion criteria, or an additional score for hemorrhagic risk estimation during pregnancy should be developed.

In addition, a study from Japan²² reviewed the safety of maternal and fetal radiation exposure during endovascular treatment. The authors of the study reported that fetal radiation effects are highly dependent on both the administered dose and developmental stage at the time of exposure. The fetus of our patient was in the midfetal stage (16-25 weeks), and the safe limit is estimated to be 120 mGy in this stage.²³ The study²² also estimated that the absorbed fetal dose is 2.8 mGy in a general endovascular procedure (the radiation exposure durations for the groin and head are 30 seconds and 45 minutes, respectively), which is an order of magnitude lower than the risk thresholds mentioned above. Furthermore, the adverse effects of ionizing radiation should be minimized with optimal protection for the abdomen of the patient using a lead apron.²³ This indicates that the risk of irradiation to the fetus during endovascular treatment could be minimal if operators use optimal protection and follow appropriate procedures.

Conclusions

The results of our case and other cases previously reported in the literature indicate that intravenous rt-PA administration and EMT can be considered as treatment for AIS during pregnancy unless a high risk of hemorrhage or preterm labor is expected. If the risks of complications are estimated appropriately and suitable inclusion/exclusion criteria for administration of rt-PA/EMT to pregnant women with ischemic stroke are developed, the outcome of pregnant women with AIS will improve while maintaining patient safety. Further research is necessary to estimate the risk of complications and the benefit of rt-PA/EMT treatment

based on the etiology of the ischemic stroke and the stage of pregnancy.

References

- Swartz RH, Cayley ML, Foley N, et al. The incidence of pregnancy-related stroke: a systematic review and meta-analysis. *Int J Stroke* 2017;12:687-697.
- Minematsu K, Toyoda K, Hirano T, et al. Guidelines for the intravenous application of recombinant tissue-type plasminogen activator (alteplase), the second edition, October 2012: a guideline from the Japan Stroke Society. *J Stroke Cerebrovasc Dis* 2013;22:571-600.
- Jauch EC, Saver JL, Adams HP, et al. Guidelines for the early management of patients with acute ischemic stroke. *Stroke* 2013;44:870-947.
- Aaron S, Shyamkumar NK, Alexander S, et al. Mechanical thrombectomy for acute ischemic stroke in pregnancy using the penumbra system. *Ann Indian Acad Neurol* 2016;19:261-263.
- Bhogal P, Aguilar M, AlMatter M, et al. Mechanical thrombectomy in pregnancy: report of 2 cases and review of the literature. *Intervent Neurol* 2017;6:49-56.
- Daprich M, Boessenecker W. Fibrinolysis with alteplase in a pregnant woman with stroke. *Cerebrovasc Dis* 2002;13:290.
- Murugappan A, Coplin WM, Al-Sadat AN, et al. Thrombolytic therapy of acute ischemic stroke during pregnancy. *Neurology* 2006;66:768-770.
- Wiese KM, Talkad A, Mathews M, et al. Intravenous recombinant tissue plasminogen activator in a pregnant woman with cardioembolic stroke. *Stroke* 2006;37:2168-2169.
- Leonhardt G, Gaul C, Nietsch HH, et al. Thrombolytic therapy in pregnancy. *J Thromb Thrombolysis* 2006;21:271-276.
- Yamaguchi Y, Kondo T, Ihara M, et al. Intravenous recombinant tissue plasminogen activator in an 18-week pregnant woman with embolic stroke. *Rinsho Shinkeigaku* 2010;50:315-319.
- Tassi R, Acampa M, Marotta G, et al. Systemic thrombolysis for stroke in pregnancy. *Am J Emerg Med* 2013;31:e1-e3.
- Hori H, Yamamoto F, Ito Y, et al. Intravenous recombinant tissue plasminogen activator therapy in a 14-week pregnant woman with embolic stroke due to protein S deficiency. *Rinsho Shinkeigaku* 2013;53:212-216.
- Mantoan Ritter L, Schüller A, Gangopadhyay R, et al. Successful thrombolysis of stroke with intravenous alteplase in the third trimester of pregnancy. *J Neurol* 2014;261:632-634.
- Ritchie J, Lokman M, Panikkar J. Thrombolysis for stroke in pregnancy at 39 weeks gestation with a subsequent normal delivery. *BMJ Case Rep* 2015. pii: bcr2015209563. <https://doi.org/10.1136/bcr-2015-209563>.
- Tversky S, Libman RB, Reppucci ML, et al. Thrombolysis for ischemic stroke during pregnancy: a case report and review of the literature. *J Stroke Cerebrovasc Dis* 2016;25:e167-e170.
- Reining-Festa A, Földy D, Coulibaly-Wimmer M, et al. Intravenous thrombolysis of stroke in early pregnancy: a case report and review of the literature. *J Neurol* 2017;264:397-400.
- Selim MH, Molina CA. The use of tissue plasminogen-activator in pregnancy: a taboo treatment or a time to think out of the box. *Stroke* 2013;44:868-869.
- Penumbra Pivotal Stroke Trial Investigators. The penumbra pivotal stroke trial: safety and effectiveness of a new generation of mechanical devices for clot removal in

- intracranial large vessel occlusive disease. *Stroke* 2009;40:2761-2768.
19. Nogueira RG, Lutsep HL, Gupta R, et al. Trevo versus Merci retrievers for thrombectomy revascularisation of large vessel occlusions in acute ischaemic stroke (TREVO 2): a randomised trial. *Lancet* 2012;380:1231-1240.
 20. Demchuk AM. Yes, intravenous thrombolysis should be administered in pregnancy when other clinical and imaging factors are favorable. *Stroke* 2013;44:864-865.
 21. Cronin CA, Weisman CJ, Llinas RH. Stroke treatment: beyond the three-hour window and in the pregnant patient. *Ann NY Acad Sci* 2008;1142:159-178.
 22. Ishii A, Miyamoto S. Endovascular treatment in pregnancy. *Neurol Med Chir* 2013;53:541-548.
 23. Otake M, Schull WJ, Lee S. Threshold for radiation-related severe mental retardation in prenatally exposed A-bomb survivors: a re-analysis. *Int J Radiat Biol* 1996;70:755-763.