



Left cerebral hemisphere hydrophilic polymer embolism associated with endovascular WEB treatment of a ruptured aneurysm of the anterior cerebral artery

Julius Tikka^{a,b,*}, Maria Gardberg^c, Riitta Rautio^d, Philippe Lunetta^{a,e}

^a Department of Biomedicine, Pathology and Forensic Medicine, University of Turku, Turku, Finland

^b Forensic Medicine Unit, The National Institute for Health and Welfare, Helsinki, Finland

^c Department of Pathology, Turku University Hospital and University of Turku, Turku, Finland

^d Department of Interventional Radiology, Turku University Hospital, Turku, Finland

^e Department of Forensic Medicine, University of Oulu, Oulu, Finland

ARTICLE INFO

Keywords:

Hydrophilic polymer embolism
Endovascular procedure
Complications

ABSTRACT

Hydrophilic polymer embolism (HPE) is a rare, likely under-recognized iatrogenic complication, caused by fragmentation of surface materials used on endovascular medical devices. The organs most often involved in HPE are the brain and lungs, resulting in both local and systemic reactions. We present the case of a cerebral HPE associated with WEB treatment of a ruptured aneurysm of the anterior cerebral artery, and involving diffusely the left cerebral hemisphere. The patient developed pneumonia and status epilepticus, and died 24 days after the endovascular procedure, most likely as a result of the sequelae of the aneurysm rupture. The precise role of HPE in the sequence of events leading to death can remain, as in this case, a matter for speculation. However, the potential role of HPE in the events leading to death following diagnostic and therapeutic procedures should be appropriately assessed, especially when recovery does not progress as expected.

1. Introduction

Hydrophilic polymers are used as a coating material on the surface of endovascular devices, e.g. guidewires, coils and stents, to create a smooth and slippery surface for reducing resistance within vessels [1,2]. During recent years, lung and brain embolisms caused by fragmentation of polymer coatings have been increasingly reported [2–7]. Although often subclinical and under-recognized, polymer coating embolism can cause a range of complications, from mild local inflammation to infarction, and even to death [6,7].

We describe the case of a cerebral coating polymer embolism involving diffusely the left hemisphere and following endovascular coiling of a ruptured aneurysm of the anterior cerebral artery.

2. Case report

2.1. Background

A woman in her 70 s, previously diagnosed only with glaucoma, was

found unconscious lying on the front porch of her house on May, 19th. On arrival to the emergency department (ED) of a local university hospital, she was diagnosed with a subarachnoidal hemorrhage caused by a ruptured aneurysm of the anterior cerebral artery. The same day, the aneurysm was treated by means of a Woven EndoBridge (WEB)-device. The WEB system is a self-expanding, oblate, braided mesh of platinum-cored nitinol wires that placed in the aneurysm sac, modifies the blood flow and induces thrombosis, without the need for a stent or protective balloons as it is the case in endovascular treatment with coils [8,9]. The patient was treated under general anesthesia. The right common femoral artery was punctured. A diagnostic 4F catheter (Cordis) was introduced through an 11 cm long 8F femoral sheath (Cordis) into the left internal carotid artery with the help of a Terumo wire. Digital subtraction angiography revealed a broad-necked $4 \times 5 \times 5$ mm aneurysm, at the pericallosal and callosomarginal bifurcation on the left. The diagnostic catheter was then replaced by an 80 cm long 6F sheath (Penumbra NeuronMax). Thereafter, an intracranial support catheter (Navien 0.058, Covidien) was introduced through the long femoral sheath and placed into the left internal carotid

* Corresponding author at: National Institution of Health and Welfare (THL), University of Turku, Department of Biomedicine, Pathology and Forensic Medicine, Kiinanmyllynkatu 10, 20520 Turku, Finland.

E-mail addresses: julius.tikka@utu.fi (J. Tikka), maria.gardberg@utu.fi (M. Gardberg), riitta.rautio@tyks.fi (R. Rautio), philippe.lunetta@utu.fi (P. Lunetta).

<https://doi.org/10.1016/j.legalmed.2018.09.015>

Received 26 January 2018; Received in revised form 4 September 2018; Accepted 23 September 2018

Available online 24 September 2018

1344-6223/ © 2018 Published by Elsevier B.V.

artery. Lastly, a microcatheter (Via 21, Microvention) was threaded from the support catheter and with the help of a guidewire (Stryker Synchro), into the aneurysm in which a 6 × 3 mm single-layer version of WEB (WEB-SL), was positioned.

The procedure was uneventful, but after aneurysm occlusion, the patient remained unconscious. A CT, performed 6 h after the WEB procedure, showed re-bleeding and ischemic changes in the brain tissue surrounding the aneurysm with compression of the lateral ventricles. A ventriculostomy was performed the next day. On May, 22nd, the patient developed status epilepticus and pneumonia. Anti-epileptic medication and antibiotics were administered. Despite aggressive supportive care, the patient showed no signs of recovery, and death ensued on June 12th, 24 days after admission to the ED.

2.2. Autopsy findings

A medico-legal autopsy was performed 4 days post-mortem. The brain was fixed in formalin 10% for neuropathological examination. Macroscopic and microscopic examination of other organs disclosed only moderate cardiac hypertrophy (450 g) and nephrosclerosis. No foreign bodies or other embolisms were detectable in the lungs. Blood and urine were sampled and stored for toxicology, but were not analyzed.

2.3. Neuropathological examination

Macroscopic examination revealed a 9-mm broad-based aneurysm containing WEB device in the left anterior cerebral artery (ACA) and subarachnoid hemorrhage over the frontotemporal areas, as well as over the occipital lobes and cerebellum. A 1.5-cm diameter intracerebral hemorrhage surrounded the aneurysm, and an acute infarct was detectable in the ACA area.

In addition to the aneurysm, the anterior cerebral arteries, and surrounding cerebral tissue, samples for microscopic examination were also taken bilaterally from the frontal, parietal, temporal, parietal, and occipital lobes, as well as from the corpus callosum, left and right hippocampus, right nucleus lentiformis, left nucleus dentatus, substantia nigra, pons, and medulla. A single sample was taken from each location, except two from the left frontal lobe. From each sample, 3.5- μ m thick sections were prepared and stained with hematoxylin and eosin. Microscopic examination revealed that the hemorrhage surrounding the left ACA consisted mostly of partially lysed red blood cells and abundant hemosiderin- and lipid-laden macrophages; proliferation of blood vessels was detectable. Within the infarct in the ACA area, the necrotic area showed abundant infiltration of lipid-laden macrophages and prominent proliferation of blood vessels. No cystic changes were detectable. These findings are consistent with a 3- to 4-week-old hemorrhage and infarct.

Tissue samples from the left cerebral hemisphere showed, within small arterioles, elongated slender, serpiginated, slightly basophilic and non-polarizable foreign particles. Their size each ranged from approximately 15 to 200 μ m. Intravascularly, these particles were surrounded by multinucleated cells, suggesting a foreign-body reaction (Fig. 1 A and B). These foreign particles were detectable in each lobe of the left cerebral hemisphere, but not in tissue samples from the right cerebral hemisphere, cerebellum, or brain stem (Table 1).

Immunohistochemical staining for endothelial cells with CD34 confirmed the intravascular localization of the foreign bodies and multinucleated cells (Fig. 1 C). The latter were CD68-positive, substantiating their macrophage lineage (Fig. 1 D). These findings were consistent with 3-day- to 2-month-old polymer emboli [1]. The cerebral tissue surrounding these emboli showed no pathological changes.

The cause of death certified was “intracerebral and subarachnoid hemorrhage from ruptured aneurysm of the left anterior cerebral artery.”

3. Discussion

Polymer coatings have several biomedical applications; they serve to enhance the durability, accessibility, and safety of medical devices such as orthopedic materials, antibacterial surfaces, and endovascular devices [10]. Polymer subtypes include hydrophobic and hydrophilic polymers, the latter being used as a surface coating on endovascular devices. As the term “hydrophilic polymer” suggests, this material attracts water and thus makes the surface of the device slippery. This improves maneuverability of the endovascular device inside the vessel, reduces resistance, and prevents tissue damage [1]. Hydrophobic polymers are used for example in drug delivery and on implantable devices, when contact between the surface and biofluids is to be avoided [10].

Hydrophilic polymer coating embolism is a rarely reported, likely under-recognized complication of endovascular procedures, where fragments of the surface coating detaches, possibly via mechanical abrasion, causing embolism in peripheral vessels. However, a retrospective series of 136 consecutive hospital autopsies showed an incidence of polymer coating embolism as high as 13% [3].

Another study, based on myocardial histological samples collected in autopsy from 40 patients who were subjected to percutaneous coronal interventions, showed an incidence of 10% [11].

The usual sites for polymer coating embolism are the brain and lungs, but emboli can also occur in other organs depending on the access point of the endoscopic device and the site(s) of the polymer detachment. Cerebral polymer coating embolism has been linked to a range of intracranial procedures, e.g. angiography, coil embolization and thrombectomy, but polymer fragments can be transferred to intracranial blood vessels from more proximal locations through the circulation [7].

While most polymer coating embolisms are subclinical, complications can, on the other hand, be severe, and fatal outcomes occurs as well. The symptoms and signs resulting from cerebral polymer coating embolism include constitutional ones, sensory and visual deficits, ischemia, and seizures, depending on the location and extension and the type of reaction induced by the embolism. Although the average symptom onset is 1 to 2 months, symptoms have developed as early as one day and as late as 270 days after the procedure [6]. The first fatal case of cerebral polymer coating embolism was described by Metha et al, in 2009 [5]. The same authors have recently reviewed 32 cases of intracranial polymer embolism following endovascular procedures and found a mortality rate of 28% [7]. They also categorized changes induced by such embolism in inflammatory, ischemic, or arterial abnormalities. The most common reaction was vasculitis or vasculopathy (63%), followed by abscess or granuloma (38%), ischemic infarcts (28%), hematomas (28%), white-matter changes (25%), and chemical meningitis (22%) [7].

The emboli spread diffusely to the left cerebral hemisphere, involving every lobe, suggesting that fragmentation of the coating must have taken place in the more proximal vasculature, most likely in the left carotid artery. At the site of the emboli, the vessel wall showed a foreign-body reaction with multinucleated macrophages, which is consistent with the embolism's arising at the time of the aneurysm endovascular treatment, 24 days before the fatal outcome [1]. Cerebral tissue surrounding the emboli showed no pathological changes. Since the patient suffered a subarachnoid hemorrhage without regaining consciousness, the clinical manifestations of the embolism, including epileptic attacks, and its role as a contributing factor to death, are unclear and remain a matter for speculation.

In conclusion, clinicians and pathologists should be aware of the occurrence of this iatrogenic complication, in order to determine precisely its causes and actual incidence and, eventually contribute to assisting manufacturers in developing safer polymer coatings. This case report reiterates the utility of thorough neuropathological investigation in cases with putative iatrogenic complications associated to

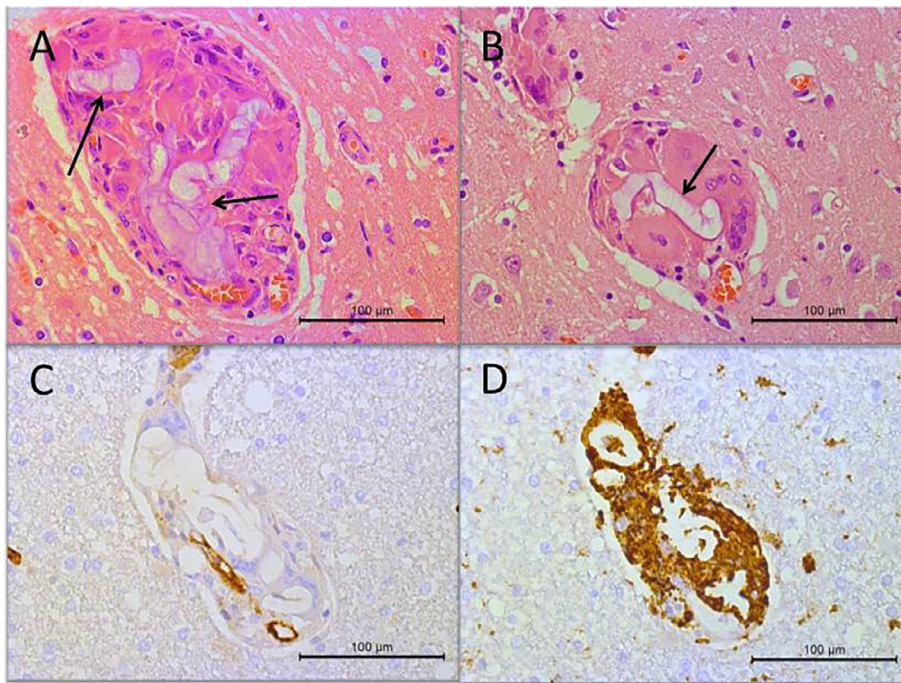


Fig. 1. Histological findings in cerebral arterioles. A, B. Slightly basophilic elongated foreign bodies (arrows) are visible adjacent to small blood vessels. HE-staining. C. Immunohistochemical staining with endothelial cell marker CD34 demonstrates the intravascular location of the foreign bodies next to a narrow recanalized arterial lumen. D. Macrophage marker CD68 labels the intravascular giant cells of the foreign body reaction.

Table 1

Number of arterial emboli found in H&E stained sections from tissue blocks of brain lobes. (one 3.5-µm-thick section for each block). One sample was taken from each lobe, except two from the left frontal lobe. *The same number (18) of emboli appeared in both left frontal lobe samples.

	Right hemisphere	Left hemisphere
Frontal	0	18*
Temporal	0	3
Parietal	0	18
Occipital	0	11

endovascular treatment of cerebral aneurysm. Moreover, the occurrence of a polymer embolism may have significant medico-legal implications. The effects of polymer embolism should thus undergo assessment to disentangle ones arising from the original medical condition from those arising from diagnostic and therapeutic procedures. This is vital especially when assessing their potential role in events leading to death.

4. Funding

This research did not receive any specific grant from funding agencies in the public, commercial, or not-for-profit sectors.

5. Declarations of interest

None.

References

- [1] R.I. Mehta, R.I. Mehta, Hydrophilic polymer embolism: an update for physicians, *Am. J. Med.* 130 (2017) 287–290.
- [2] R.I. Mehta, R.I. Mehta, Hydrophilic polymer embolism: implications for manufacturing, regulation, and postmarket surveillance of coated intravascular medical devices, *J. Patient. Saf.* (2018).
- [3] R.I. Mehta, R.I. Mehta, J.M. Choi, A. Mukherjee, R.J. Castellani, Hydrophilic polymer embolism and associated vasculopathy of the lung: prevalence in a retrospective autopsy study, *Hum. Pathol.* 46 (2015) 191–201.
- [4] A. Rapkiewicz, B. Hood, K. Hutchins, Fatal Case of Hydrophilic Polymer Emboli, *J. Forensic. Sci.* 61 (2016) 268–270.
- [5] R.I. Mehta, R.I. Mehta, M.C. Fishbein, O.E. Solis, R. Jahan, N. Salamon, H.V. Vinters, W.H. Yong, Intravascular polymer material after coil embolization of a giant cerebral aneurysm, *Hum. Pathol.* 40 (2009) 1803–1807.
- [6] A.M. Chopra, M. Mehta, J. Bismuth, M. Shapiro, M.C. Fishbein, A.G. Bridges, et al., Polymer coating embolism from intravascular medical devices - a clinical literature review, *Cardiovasc. Pathol.* 30 (2017) 45–54.
- [7] R.I. Mehta, R.I. Mehta, Polymer-induced central nervous system complications following vascular procedures: spectrum of iatrogenic injuries and review of outcomes, *Hum. Pathol.* 53 (2016) 178–190.
- [8] B. Jiang, M. Paff, G.P. Colby, A.L. Coon, L.M. Lin, Cerebral aneurysm treatment: modern neurovascular techniques, *Stroke Vasc. Neurol.* 1 (2016) 93–100.
- [9] W.J. van Rooij, J.P. Peluso, R.S. Bechan, M. Sluzewski, WEB treatment of ruptured intracranial aneurysms, *AJNR Am. J. Neuroradiol.* 37 (2016) 1679–1683.
- [10] J.T. Smith, D.A. Lamprou, Polymer coatings for biomedical applications: a review, *Trans IMF* 92 (2014) 9–19.
- [11] M.J. Grundeken, X. Li, C.E. Kurpershoek, M.C. Kramer, A. Vink, J.J. Piek, J.G. Tijssen, K.T. Koch, J.J. Wykrzykowska, R.J. de Winter, A.C. van der Wal, Distal embolization of hydrophilic-coating material from coronary guidewires after percutaneous coronary interventions, *Circ Cardiovasc Interv.* 8 (2015) e001816.