

Herpes Zoster Ophthalmicus With Contralateral Hemiplegia

Riccardo Pratesi, MD; Frank R. Freeman, MD; James L. Lowry, MD

• A 48-year-old man developed left hemiparesis nine weeks after herpes zoster skin lesions had appeared over the right forehead. Cerebral angiography showed bilateral changes consistent with cerebral arteritis. The patient's condition worsened after the angiographic procedure. Reports from the literature as well as the present case suggest that arteritis and ischemia best explain contralateral neurological symptoms that occur suddenly following herpes zoster ophthalmicus.

(*Arch Neurol* 34:640-641, 1977)

Hemiplegia occurring a few weeks after and contralateral to herpes zoster ophthalmicus forms a well-described syndrome.¹⁻⁷ Angiography has suggested an arteritic intracranial process,^{8,9} and temporal artery biopsy has shown inflammation in an ipsilateral extracranial vessel.¹⁰

We describe a patient in whom repeated angiography showed a spreading of the process, eventually affecting cerebral vessels bilaterally.

Accepted for publication May 9, 1977.

From the Neurology Service, Nashville (Tenn) Veterans Administration Hospital. Dr Pratesi is now with the Department of Pediatrics, Primeiro Hospital Distrital de Brasilia (Brazil). Dr Lowry is now in private practice in Albuquerque, New Mexico.

Reprint requests to Departamento de Pediatria, Primeiro Hospital Distrital de Brasilia, D.F. 70.000, Brazil (Dr Pratesi).

Substantial worsening followed the second angiographic procedure.

REPORT OF A CASE

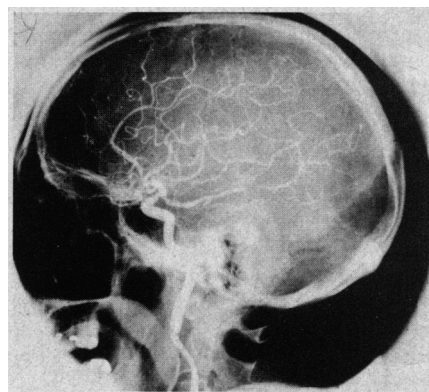
A 48-year-old man in good health developed severe pain around the right eye, followed by a vesicular rash on the right forehead. An ophthalmologist diagnosed herpes zoster and prescribed corticosteroids. During the next four weeks, the pain subsided and the rash faded, but mental changes developed. Examination showed mild right eyelid edema and severe confusion. A radionuclide brain scan, a computerized tomographic scan, and skull roentgenograms were normal. An EEG showed right-sided slow activity. A lumbar puncture disclosed xanthochromic spinal fluid with a protein concentration of 116 mg/100 ml but no cells. Bilateral carotid arteriograms ten weeks after onset of the vesicular rash showed narrowing of the right posterior cerebral artery (Fig 1). The day following the angiogram, left hemiparesis was noted.

The patient improved slightly during the next two weeks and was transferred to the Nashville (Tenn) Veterans Hospital. He was slightly lethargic and the right eyelid was edematous. The patient had decreased memory for recent events, with a short attention span. Impairment of abduction and elevation of the right eye and a fixed and dilated right pupil were found. The remainder of the cranial nerves and the optic fundus were normal. The left side

was severely paretic, with limbs barely moved against gravity. Muscle stretch reflexes were more active on the left with a left Babinski sign. Normal values on admission included blood cell count with differential cell count, urinalysis, latex fixation, antinuclear antibody, six- and 12-factor automated blood chemistry analysis, VDRL, ECG, and chest and skull roentgenograms. Lumbar puncture showed clear, colorless fluid with no cells, a glucose level of 83 mg/100 ml and a protein level of 79 mg/100 ml. Radionuclide scan was normal. An EEG showed continuous slow activity on the right.

Little change occurred in the patient's clinical condition during the next month.

Fig 1.—Initial right carotid arteriogram. Posterior cerebral artery shows irregularity consistent with arteritis. Anteroposterior view (not shown) showed no middle cerebral artery involvement.



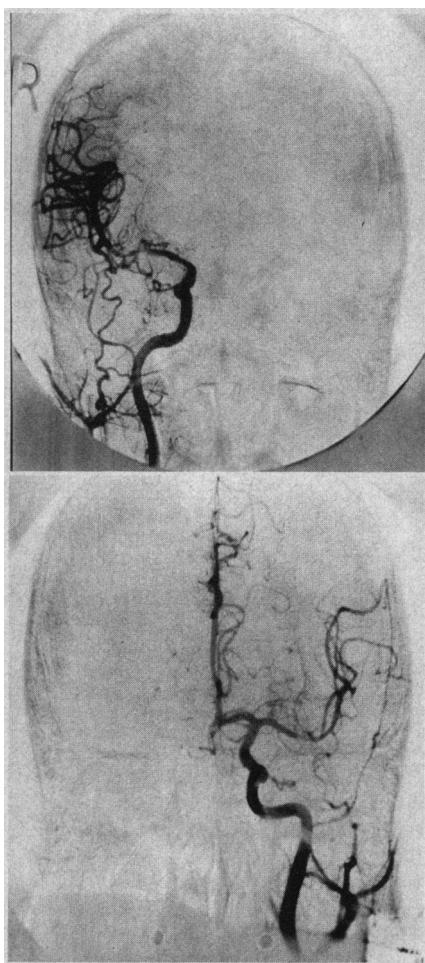


Fig 2.—Second carotid arteriogram. Anteroposterior projections of right (top) and left (bottom) carotid arteriograms demonstrate proximal segmental narrowing of both middle cerebral arteries.

He received prednisone in a dosage varying between 120 mg/day and 50 mg every other day since his first hospitalization, and we suspected that delusional thinking might be due in part to this medication. Bilateral carotid angiograms via femoral approach were performed to determine if vasculitis was still present,

and hence if continued corticosteroid therapy was necessary. Following the initial injection into the right common carotid artery, the patient immediately complained of intense right facial pain with flushing. Concomitantly, the left-sided weakness changed to a dense hemiplegia with the addition of a left homonymous hemianopsia. After an hour the procedure was continued without further difficulty. Narrowing of the proximal right middle cerebral artery, with stasis in one ascending frontoparietal branch, was evident (Fig 2). No filling occurred in the right anterior cerebral and posterior cerebral arteries. Proximal narrowing of the left middle cerebral artery was seen. Bilaterally, the internal carotid arteries were normal.

In the ensuing months, with corticosteroid therapy, the patient showed improvement in mental status and slight improvement in the hemiplegia.

COMMENT

The reported cases of herpes zoster ophthalmicus with contralateral hemiplegia form a characteristic syndrome.¹⁻⁷ Vesicles appeared over half the forehead and sometimes over the ipsilateral nose and cheek; some patients complained of unilateral blurred vision due to corneal ulceration. Contralateral hemiplegia occurred in each patient, usually a few weeks after the eruption. In individuals with a right hemiplegia, aphasia frequently accompanied the motor symptoms. Every patient demonstrated a Babinski sign on the same side as the hemiplegia, and three had bilateral upgoing toes. In three cases there was an associated dysfunction of cranial nerve III ipsilateral to the involved cranial nerve V. Cerebrospinal fluid, though frequently normal, sometimes contained a few mononuclear cells and a slight elevation of

protein concentration. Walker and colleagues⁸ were the first to demonstrate angiographic changes in the cerebral arteries. Their patient showed segmental constriction in the proximal middle cerebral and anterior cerebral arteries with stasis, findings similar to those in our patient. Subsequently, Gilbert⁹ described a patient demonstrating segmental narrowing of the right internal carotid siphon. Our case is distinctive in that bilateral changes along the course of the proximal middle cerebral arteries were demonstrated. Victor and Green¹⁰ found inflammation but no viral particles in a temporal artery biopsy specimen. Granulomatous or giant cell arteritis has been found in many cerebral vessels in two patients following herpes zoster ophthalmicus.^{11,12} Corticosteroids are usually used in treatment, although some patients have developed the hemiparesis while already receiving this medication in high dosages.

In the present case, hemiparesis was first noted the day after a cerebral angiogram, although there is no evidence that these two events were causally related. There was an immediate adverse reaction to the second angiogram, with flushing and severe pain ipsilateral to the injection, on the side of the herpes zoster. This was probably a "vasomotor" rather than an urticarial or anaphylactoid allergic reaction.¹³ Patients with this syndrome may not have an increased risk of adverse angiographic reaction; nevertheless, it seems that the clinical picture of a hemispheric stroke a few weeks following herpes zoster ophthalmicus is well enough established that angiography can be avoided in the future.

References

1. Gordon IRS, Tucker JF: Lesions of the central nervous system in herpes zoster. *J Neurol Neurosurg Psychiatry* 8:40-46, 1945.
2. Hughes WN: Herpes zoster of the right trigeminal nerve with left hemiplegia. *Neurology* 1:167-169, 1951.
3. Cope S, Jones AT: Hemiplegia complicating ophthalmic zoster. *Lancet* 2:898-899, 1954.
4. Anastasopoulos G, Routsoms K, Tersdikou CS: Ophthalmic herpes zoster with contralateral hemiplegia. *J Neurol Neurosurg Psychiatry* 21:210-212, 1958.
5. Laws HW: Herpes zoster ophthalmicus complicated by contralateral hemiplegia. *Arch Ophthalmol* 63:273-280, 1960.
6. Acers TE: Herpes zoster ophthalmicus with contralateral hemiplegia. *Arch Ophthalmol* 71:371-376, 1964.
7. Norris FH, Leonards R, Gelanchini PR, et al: Herpes zoster meningoencephalitis. *J Infect Dis* 122:335-338, 1970.
8. Walker RJ, Gammal TE, Allen MG: Cranial arteritis associated with herpes zoster. *Neuro-radiology* 107:109-110, 1973.
9. Gilbert GJ: Herpes zoster ophthalmicus and delayed contralateral hemiparesis. *JAMA* 229:302-304, 1974.
10. Victor DI, Green WR: Temporal artery biopsy in herpes zoster ophthalmicus with delayed arteritis. *Am J Ophthalmol* 82:628-630, 1976.
11. Kolodny EH, Rebeiz JJ, Caviness VS, et al: Granulomatous angiitis of the central nervous system. *Arch Neurol* 19:510-524, 1968.
12. Rosenblum WI, Hadfield MG: Granulomatous angiitis of the nervous system in case of herpes zoster and lymphosarcoma. *Neurology* 22:348-354, 1972.
13. Zweiman B, Mishkin MM, Hildreth EA: An approach to the performance of contrast studies in contrast material reactive persons. *Ann Intern Med* 83:159-162, 1975.