



Contents lists available at ScienceDirect

Journal of Clinical Neuroscience

journal homepage: www.elsevier.com/locate/jocn

Case report

Deep brain stimulation of the ventralis intermedius nucleus of the thalamus and posterior subthalamic area for Holmes' tremor secondary to brainstem hemorrhage: A case report

Chang Duk Yuk^a, Jun Hyong Ahn^{a,b}, Jae Keun Oh^a, In Bok Chang^a, Joon Ho Song^a, Ji Hee Kim^{a,b,*}^a Department of Neurosurgery, Hallym University Sacred Heart Hospital, Anyang, Republic of Korea^b Kangwon National University College of Medicine, Chuncheon, Republic of Korea

ARTICLE INFO

Article history:

Received 10 August 2018

Accepted 6 October 2018

Available online xxxx

Keywords:

Deep brain stimulation

Holmes' tremor

Posterior subthalamic area

Rubral tremor

Thalamic stimulation

Ventralis intermedius

ABSTRACT

Holmes' tremor is a rare but severely disabling movement disorder characterized by a combination of resting, action, and intention tremor. Because Holmes' tremor is usually resistant to pharmacotherapy, surgical treatment is required for symptom control in most cases. We report the case of a 56-year-old man who was diagnosed with Holmes' tremor and treated with stimulation of the ventralis intermedius nucleus of the thalamus and posterior subthalamic area. Deep brain stimulation alleviated the patient's tremor over a 3-year follow-up period.

© 2018 Elsevier Ltd. All rights reserved.

1. Introduction

Holmes' tremor (HT), first described by Gordon Holmes in 1904, is a rare but severely disabling movement disorder that is characterized by symptomatic low-frequency (<4.5 Hz) resting tremor that is exacerbated by posture and action [1,2]. Also known as rubral tremor or midbrain tremor, HT is generally unilateral and typically involves the proximal limbs [3]. HT arises from underlying structural lesions of the upper brainstem, cerebellum, thalamus, areas adjacent to the red nucleus, substantia nigra, and nigrostriatal tract that are usually caused by cerebral hemorrhage, ischemia, trauma, infection, metabolic disorders, demyelinating disease, neoplasms, or radiation [4,5]. Clinically, HT is defined by the Movement Disorder Society as: (1) the presence of both resting and intention tremor; (2) tremor frequency below 4.5 Hz; and onset with variable delay between lesion occurrence and the first appearance of symptoms [2]. Pharmacological treatments for tremor, including levodopa, have a low success rate in HT [6], thus, in refractory cases, surgical treatment such as stereotactic thalamotomy or thalamic stimulation is recommended.

Here, we describe a rare case of HT secondary to spontaneous intracerebral hemorrhage located at the left midbrain to pons that was successfully improved with simultaneous deep brain stimulation (DBS) of the ventralis intermedius nucleus of the thalamus (VIM) and posterior subthalamic area (PSA).

2. Case report

A 55-year-old man with a 3-month history of resting and action tremor affecting mostly his right hand and head was referred to our institution. He had developed right-sided hemiparesis secondary to a hypertensive brainstem hemorrhage 9 months prior. At that time, brain computed tomography (CT) showed an acute hemorrhage in the left midbrain to pons (Fig. 1). After conservative management and physical therapy, the patient showed gradual improvement but still had significant motor weakness. Nine months after the brainstem hemorrhage, he exhibited severe resting, postural, and kinetic tremor affecting the right upper limb and head as well as focal hand dystonia on neurological examination. At that time, axial T2-weighted magnetic resonance imaging (MRI) demonstrated encephalomalacic changes, cystic degeneration, and hemosiderin around the lesion (Fig. 2). He was treated with several medications including propranolol, levodopa/carbidopa, clonazepam, and baclofen, but his symptoms persisted. He had no history of using neuroleptics or tremor-inducing drugs

* Corresponding author at: Kangwon National University College of Medicine, Hallym University Sacred Heart Hospital, 22, Gwanpyeong-ro170 beon-gil, Dongan-gu, Anyang-si 14068, Republic of Korea.

E-mail address: kimjihee.ns@gmail.com (J.H. Kim).

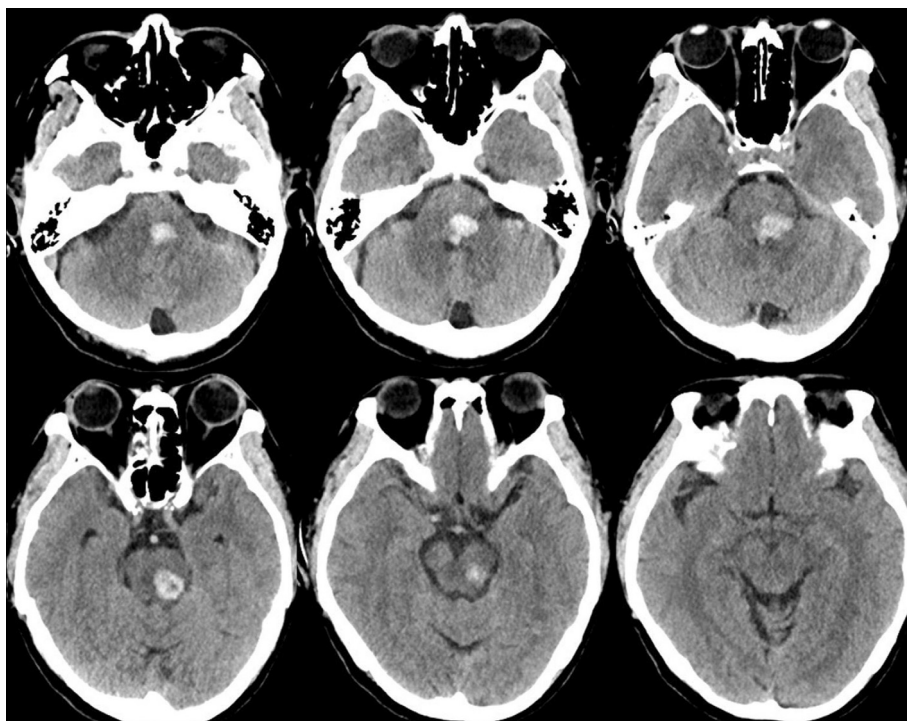


Fig. 1. Preoperative computed tomography imaging showing acute intracerebral hemorrhage in the left midbrain and pontine tegmentum.

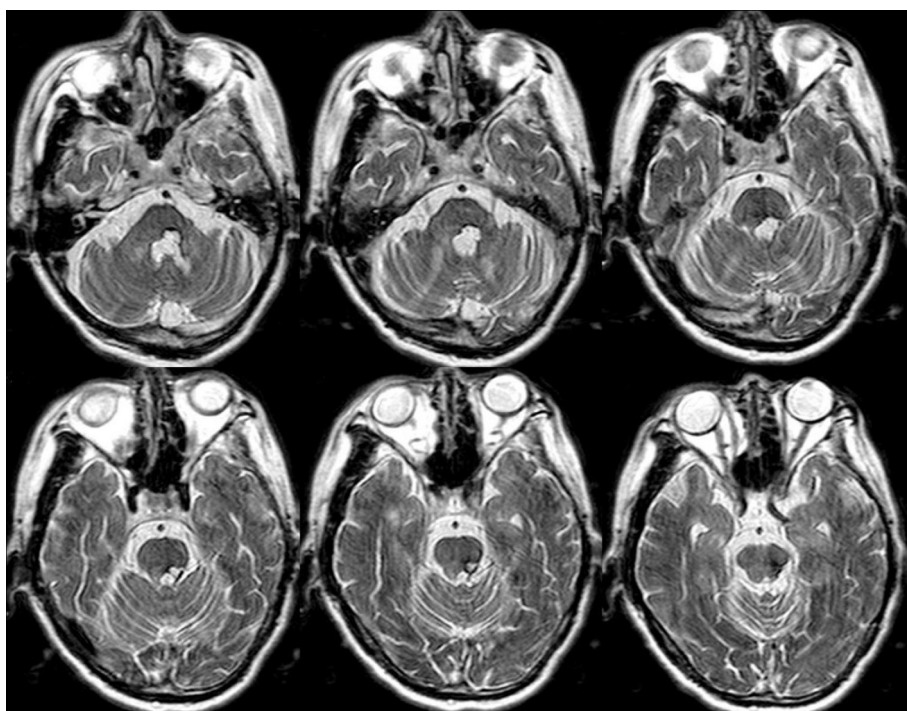


Fig. 2. Preoperative T2-weighted axial magnetic resonance imaging revealing the resolution of acute hemorrhage. Encephalomalacic changes, cystic degeneration, and hemosiderin around the lesion were also observed.

prior to or after the brainstem hemorrhage and no family history of a movement disorder.

2.1. Surgical procedure

Surgery was performed in accordance with established DBS procedures. Briefly, unilateral DBS electrode implantation was per-

formed under local anesthesia using a Leksell stereotactic frame and MRI-guided targeting (Philips, Eindhoven, the Netherlands) with a Stealthstation Framelink system (Medtronic, Inc., Minneapolis, MN, USA). The VIM target was set at 13.5 mm lateral to the midline and 25% anterior to the posterior commissure in the intercommissural plane. PSA localization was verified using MRI and a brain atlas. After localizing the VIM target, the electrode

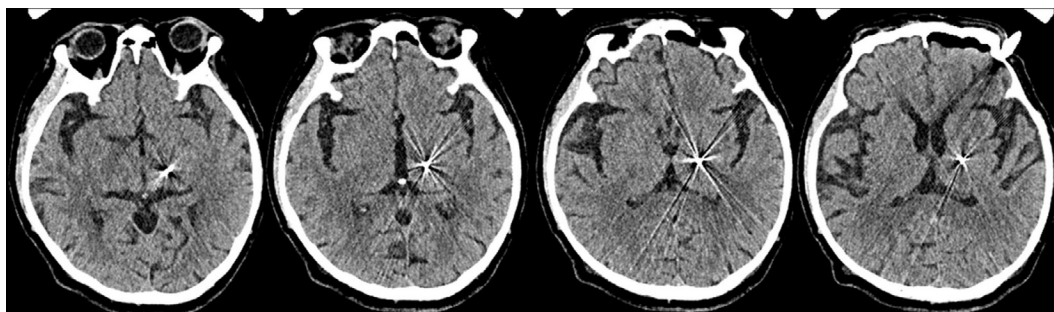


Fig. 3. Position of the deep brain stimulation electrode as visualized by postoperative computed tomography.

was advanced to the PSA while maintaining the determined angle of trajectory using T2-weighted MRI. Single-track microelectrode recording was performed and cell activity was recorded starting from 10 mm above the VIM target. We identified the ventral thalamic border and tremor cells inside the VIM. After precise localization of the target point, a quadripolar DBS electrode (model 3387, Medtronic, Inc.) was placed and intraoperative test stimulation was performed to verify tremor control in the absence of stimulation-induced side effects. After electrode implantation, postoperative CT was performed and merged with preoperative MRI to verify the location of the electrode (Fig. 3). Furthermore, in merging with Atlas, we confirmed that the proximal electrodes (contacts 0 and 1) were positioned at the PSA and the distal electrodes (contacts 2 and 3) at the VIM. The DBS electrode was connected subcutaneously to a pulse generator (IPG, Activa SC, Medtronic, Inc.) that was implanted in the infraclavicular area under general anesthesia.

2.2. Clinical outcome

The patient experienced a remarkable reduction of tremor from the microlesion effect. Stimulation was initiated 3 days after surgery. Parameters were titrated to provide optimal tremor control without side effects. We evaluated the degree of tremor using quantitative analysis with the 3-part clinical rating scale for tremor (CRST), which is a widely used assessment tool for tremor [7]. The CRST was administered before surgery and at 1 month, 3 months, 1 year, 2 years, and 3 years post-surgery (Fig. 4). The initial DBS setting had an amplitude of 1.5 V, a pulse width of 60 ms, and a frequency of 180 Hz with monopolar configuration using contact 0-negative. After initial stimulation, the tremor severity slightly

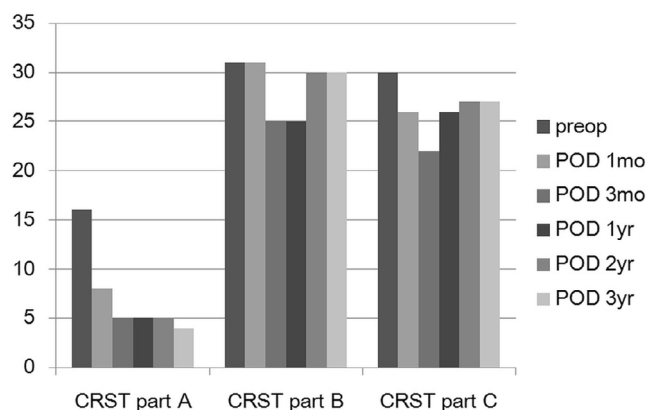


Fig. 4. Clinical rating scale for tremor (CRST) scores for tremor location and severity (part A), specific motor tasks (part B), and functional disabilities (part C) before surgery and 1 month, 3 months, 1 year, 2 years and 3 years post-surgery.

improved. However, since the tremor was still severe, the amplitude was increased to 3.0 V and two additional contacts (1-negative and 2-negative) were selected. The tremor severity gradually improved whenever we added a contact and raised the amplitude. However, the IPG exhaustion rate was too fast if all the contacts were used, so we decided to use only three contacts. After parameter optimization, the patient experienced a remarkable reduction in tremor; however, focal dystonia affecting the right hand was unchanged. He was discharged with the following VIM and PSA stimulator settings: monopolar, contact 0-negative, 1-negative, 2-negative, 3.2 V, 60 ms, 180 Hz. The patient did not exhibit any stimulation-induced side effects at the time of discharge.

At 1 month post-surgery, the patient showed improvement in the CRST part A score (symptom severity) from 16 to 8, CRST part B score (specific motor task function) from 31 to 25, and CRST part C score (functional disabilities) from 30 to 21 compared with his preoperative scores. The alleviation of tremor severity was sustained over the following 3 years as evidenced by decreased CRST part A scores; however, specific motor task function and functional disabilities were slightly worse at 1 year and 2 years post-surgery (Fig. 4). No changes in focal dystonia of the right hand were observed after surgery or during the follow-up period.

3. Discussion

Although simultaneous VIM and PSA stimulation has previously been described as an effective treatment for essential tremor (ET), this is the first report to describe its successful use in HT [8]. The success of thalamotomy and prolonged thalamic stimulation in ET first led to their applications in HT [9,10], and have driven a majority of studies regarding DBS for HT to focus on thalamic areas. Yet, the outcome of VIM DBS alone has been unsatisfactory in patients with HT. Thus, other targets have been proposed as alternatives to achieve better outcomes, including stimulation with multiple leads [11–14]. Although the precise pathophysiology of HT is still unclear, it is believed that both the dopaminergic nigrostriatal and cerebellothalamic systems are involved in the generation of resting and kinetic tremor [15–18]. For this reason, the stimulation of a larger area or the implantation of multiple leads may be necessary in patients with HT.

Several previous reports have described the implantation of dual or multiple leads for the treatment of tremor. Romanelli et al. noted that stimulation of the VIM or subthalamic nucleus (STN) alone failed to resolve mixed tremor, whereas combined VIM-STN stimulation produced relief without side effects [12]. Goto and Yamada reported a patient with pontine hemorrhage in whom a combination of VIM DBS and pallidotomy abolished HT. Moreover, Foote et al. described the successful treatment of patients with tremor rebound after stimulation of the border between the VIM and the ventralis oralis posterior (VOP) with

additional stimulation of the border between the ventralis oralis anterior (VOA) and the VOP [11]. Kobayashi et al. recently showed that dual DBS with one electrode implanted at the VOA or VIM and the other in the subthalamic area (SA) was effective in 4 patients with HT [14], importantly, the authors demonstrated that stimulation with 2 electrodes exerted a greater therapeutic effect than did stimulation with 1 electrode. Recently, Toda et al. reported a patient with HT who showed effective tremor control for six years through coaxial interleaved stimulation of the VO and subthalamic region [19]. In our case, stimulation at multiple contacts, including both the VIM and PSA, similarly produced a better response than did stimulation at 1 electrode contact alone. Taken together, it appears that large stimulation areas are required to achieve sufficient tremor control in patients with HT.

One year after continuous VIM and PSA stimulation, the patient in our case still showed significant improvements in his head and arm tremor, but he showed no improvement in hand dystonia. Accordingly, the patient still experienced significant disability at 1 and 2 years post-surgery. Future studies are necessary to identify approaches for more comprehensive symptom control; to this end, it may be useful to more extensively assess quality of life and activities of daily living in patients with HT in future research.

4. Conclusions

We demonstrated that DBS of the VIM and PSA was safe and produced sufficient tremor control without stimulation-induced side effects in a patient with medically intractable HT. Additional follow-up and case accumulation is needed to elucidate the pathophysiological mechanisms of HT and to identify optimal DBS targets in these patients.

Disclosure

No portion of the paper has been presented or published previously.

Funding

No funding was received for this research.

Conflict of interest

All authors certify that they have no affiliations with or involvement in any organization or entity with any financial interest (such as honoraria; educational grants; participation in speakers' bureaus; membership, employment, consultancies, stock ownership, or other equity interest; and expert testimony or patent-licensing arrangements), or non-financial interest (such as personal or professional relationships, affiliations, knowledge or beliefs) in the subject matter or materials discussed in this manuscript.

Acknowledgements

We would like to thank So Young Park, Byung Min Kim, Jae Min Lee, and Young Nam Kim for data acquisition and assistance with writing this manuscript.

Appendix A. Supplementary data

Supplementary data to this article can be found online at <https://doi.org/10.1016/j.jocn.2018.10.041>.

References

- [1] Holmes G. On certain tremors in organic cerebral lesions. *Brain* 1904;27:327–75.
- [2] Deuschl G, Bain P, Brin M. Consensus statement of the movement disorder society on tremor. *Mov Disord* 1998;13:2–23.
- [3] Mossuto-Agatiello L, Puccetti G, Castellano AE. “Rubral” tremor after thalamic haemorrhage. *J Neurol* 1993;241:27–30.
- [4] Rieder CR, Rebouças RG, Ferreira MP. Holmes tremor in association with bilateral hypertrophic olivary degeneration and palatal tremor: chronological considerations. Case report. *Arquivos de neuro-psiquiatria* 2003;61:473–7.
- [5] Nikkiah G, Prokop T, Hellwig B, Lücking CH, Ostertag CB. Deep brain stimulation of the nucleus ventralis intermedius for Holmes (rubral) tremor and associated dystonia caused by upper brainstem lesions: report of two cases. *J Neurosurg* 2004;100:1079–83.
- [6] Findley L, Gresty M. Suppression of “rubral” tremor with levodopa. *Br Med J* 1980;281:1043.
- [7] Fahn S, Tolosa E, Marin C. Clinical rating scale for tremor. *Parkinson's disease and movement disorders*. Baltimore: Williams and Wilkins; 1993. p. 271–80.
- [8] Chang WS, Chung JC, Kim JP, Chang JW. Simultaneous thalamic and posterior subthalamic electrode insertion with single deep brain stimulation electrode for essential tremor. *Neuromodulation: Technology at the Neural Interface* 2013;16:236–43.
- [9] Schuurman PR, Bosch DA, Bossuyt PM, Bonsel GJ, Van Someren EJ, De Die RM, et al. A comparison of continuous thalamic stimulation and thalamotomy for suppression of severe tremor. *N Engl J Med* 2000;342:461–8.
- [10] Benabid AL, Pollak P, Gao D, Hoffmann D, Limousin P, Gay E, et al. Chronic electrical stimulation of the ventralis intermedius nucleus of the thalamus as a treatment of movement disorders. *J Neurosurg* 1996;84:203–14.
- [11] Foote KD, Okun MS. Ventralis intermedius plus ventralis oralis anterior and posterior deep brain stimulation for posttraumatic Holmes tremor: two leads may be better than one: technical note. *Neurosurgery* 2005;56:E445.
- [12] Romanelli P, Bronté-Stewart H, Courtney T, Heit G. Possible necessity for deep brain stimulation of both the ventralis intermedius and subthalamic nuclei to resolve Holmes tremor: case report. *J Neurosurg* 2003;99:566–71.
- [13] Kilbane C, Ramirez-Zamora A, Ryapolova-Webb E, Qasim S, Glass GA, Starr PA, et al. Pallidal stimulation for Holmes tremor: clinical outcomes and single-unit recordings in 4 cases. *J Neurosurg* 2015;122:1306–14.
- [14] Kobayashi K, Katayama Y, Oshima H, Watanabe M, Sumi K, Obuchi T, et al. Multitarget, dual-electrode deep brain stimulation of the thalamus and subthalamic area for treatment of Holmes' tremor: clinical article. *J Neurosurg* 2014;120:1025–32.
- [15] Seidel S, Kasprian G, Leutmezer F, Prayer D, Auff E. Disruption of nigrostriatal and cerebellothalamic pathways in dopamine responsive Holmes' tremor. *J Neurol Neurosurg Psychiatry* 2009;80:921–3.
- [16] Schreuder F, Hamers R, van Domburg P. Teaching neuroimages: Holmes tremor after midbrain stroke. *Neurology* 2010;75. e10–e.
- [17] Paviour DC, Jäger HR, Wilkinson L, Jahanshahi M, Lees AJ. Holmes tremor: application of modern neuroimaging techniques. *Mov Disord* 2006;21:2260–2.
- [18] Remy P, De Recondo A, Defer G, Loc'h C, Amarenco P, Plante-Bordeneuve V, et al. Peduncular 'rubral' tremor and dopaminergic denervation a PET study. *Neurology*. 1995;45:472–7.
- [19] Toda H, Nishida N, Iwasaki K. Coaxial interleaved stimulation of the thalamus and subthalamus for treatment of Holmes tremor. *Neurosurg Focus* 2017;42: V1.