

Recurrent thrombosis after carotid endarterectomy secondary to activated protein C resistance and essential thrombocytosis

A case report

In Young Huh, MD, Il Sang Han, MD, Hyung Kwan Lee, MD, Yong Joon Shin, MD, Jae Min Lee, MD*

Abstract

Rationale: Thrombosis is a major cause of morbidity in the perioperative period. Although many risk factors are known, activated protein C resistance is a prominent risk for thrombosis. Activated protein C resistance frequently occurs with recurrent thromboembolism.

Patient concerns: A 59-year-old Korean woman patient with hypertension was admitted due to dysarthria and left side motor weakness.

Diagnosis and interventions: Magnetic resonance imaging showed subacute cerebral infarction with right frontoparietal lobe and stenosis at the right internal carotid artery. She underwent right carotid endarterectomy under general anesthesia. However, recurrent thrombosis on postoperative day 1 was noted at patient's right carotid artery, which prompted emergency surgery. Additional preoperative laboratory review revealed findings for activated protein C resistance, low protein S activity, antinuclear antibody (>1:160), anti-cardiolipin IgM antibody (16.6), and thrombocytosis, Janus kinase and factor V Leiden mutations. At the intensive care unit, heparin was continually infused until postoperative day 12 and was then switched to warfarin.

Outcomes: Patient was discharged at postoperative day 21 without any event. Patient had no signs of recurrence within the 3-year follow-up period, and she is still on oral warfarin and clopidogrel.

Lessons: Screening test for hypercoagulability can be used to identify patients at higher risk of postoperative complications. If hypercoagulability state is confirmed by laboratory testing, a suitable anticoagulant treatment plan should be made within the perioperative period.

Abbreviations: APC = activated protein C, APTT = activated partial thromboplastin time, CCA = common carotid artery, CEA = carotid endarterectomy, DVT = deep vein thrombosis, FVL = factor V Leiden, ICU = intensive care unit, JAK2 = Janus kinase, MRI = magnetic resonance imaging, ROTEM = rotational thromboelastometry, VTE = venous thromboembolism.

Keywords: activated protein C resistance, anticoagulants, hypercoagulability, thrombocytosis, thromboembolism

1. Introduction

Venous or arterial thrombosis is a major cause of morbidity in the perioperative period.^[1] Although many risk factors such as pregnancy, surgery, and immobilization are known, many inherited deficiencies and genetic variants have been reported.^[2,3] Resistance to the anticoagulant effect of activated protein C (APC) related to thrombosis is more prevalent with other well-

known risk factors.^[4–6] Essential thrombocytosis is associated with an increased risk of thromboembolic events.^[7] Thrombotic and vascular complications are the chief causes of death in patients with essential thrombocytosis.^[8] In this case, the Korean patient had developed multiple cerebral arterial thrombosis at postoperative day 1 after carotid endarterectomy (CEA). Patient's preoperative laboratory findings showed APC resistance and essential thrombocytosis. These conditions may lead to thrombophilia. APC resistance is very rare in Korean patients. Here, we aimed to report the significance of APC resistance and essential thrombocytosis in the perioperative settings, especially in patients with arterial thrombosis, and its prevention. The informed consent was obtained from the patient for publication of the case details.

2. Case report

A 59-year-old Korean woman (body weight 63.2 kg; height 152 cm) with hypertension (for 8 years), complained of dysarthria and left side motor weakness. She was treated with telmisartan for hypertension. She had transient ischemic attack without sequela 8 years ago and left arm weakness a month ago. Manual muscle tests revealed 2 Medical Research Council (MRC) grade in left shoulder abduction, left elbow flexor, left wrist flexor, left

Editor: N/A.

The authors have no conflicts of interest.

Department of Anesthesiology and Pain Medicine, Ulsan University Hospital, Ulsan University, Republic of Korea.

* Correspondence: Jae Min Lee, Department of Anesthesiology and Pain Medicine, Ulsan University Hospital, 877, Bangeojinsunhwando-ro, Dong-gu, Ulsan 44033, Korea (e-mail: whitedog312@hanmail.net).

Copyright © 2018 the Author(s). Published by Wolters Kluwer Health, Inc. This is an open access article distributed under the terms of the Creative Commons Attribution-Non Commercial-No Derivatives License 4.0 (CCBY-NC-ND), where it is permissible to download and share the work provided it is properly cited. The work cannot be changed in any way or used commercially without permission from the journal.

Medicine (2018) 97:44(e13118)

Received: 16 July 2018 / Accepted: 8 October 2018

<http://dx.doi.org/10.1097/MD.0000000000013118>

finger flexor, and extensor, and 3 MRC grade in left hip flexor, left knee extensor, ankle dorsiflexor. Magnetic resonance imaging (MRI) was performed immediately and showed subacute stage of cerebral infarction in the right frontoparietal lobe and moderate stenosis at the right proximal internal carotid artery (ICA) and mild stenosis at right distal common carotid artery (CCA). Upon admission, the patient was administered oral clopidogrel. An emergency right CEA was performed under general anesthesia. Patient's preoperative laboratory findings were normal, but the platelet count was high (708,000/ μ L, normal range 150,000–400,000/ μ L). No specific finding was noted on echocardiography and pulmonary function test.

Cerebral perfusion and bispectral index were monitored throughout the operation. General anesthesia was induced using propofol, remifentanyl, and rocuronium. After endotracheal intubation, left radial artery catheterization was performed for the monitoring of continuous arterial pressure. Anesthesia was maintained using sevoflurane, remifentanyl, and rocuronium. After administering 5000 U of heparin bolus through injection, the carotid artery was clamped and a temporal shunt was applied. Reperfusion was performed at 54 minutes after carotid clamping, and surgery was conducted without any event. The patient was extubated and transferred to the intensive care unit (ICU). The surgery lasted for 175 minutes, and 1500 mL of balanced crystalloid was administered.

The patient was initially stable, but general malaise and right facial palsy occurred after CEA. An MRI was performed on postoperative day 1. A newly developed lesion with multifocal filling defect and luminal irregularity was noted at the right distal CCA and proximal ICA, suggesting multiple arterial thrombosis. An emergency reoperation was performed for resolution of thrombosis. To determine the cause of patient's excessive thrombotic tendency before CEA, an additional laboratory review was conducted and showed that she had APC resistance, low protein S activity, antinuclear antibody (>1:160), anticardiolipin IgM antibody (16.6), and thrombocytosis (Table 1). Continuous heparin infusion (500 U/h) was started, and emergent reoperation was performed. General anesthesia was induced using propofol, remifentanyl, and rocuronium, and maintained with the same drug. Rotational thromboelastometry (ROTEM) was conducted after anesthesia induction and showed hypercoagulable state, despite heparin treatment (500 U/h) (Fig. 1). The heparin dose was increased to 800 U/h and a repeat ROTEM was performed. Patient's condition did not immediately improve (Fig. 2). Thrombectomy was performed without event, and the carotid artery was clamped for 103 minutes with shunt (Fig. 3A and B). She was extubated and transferred to the ICU. The surgery lasted for 170 minutes, and 1500 mL of balanced crystalloid was administered.

In the ICU, heparin (800 U–1000 U/h) was continuously infused, with the aim of increasing the activated partial thromboplastin time (APTT) to 80 seconds (normal range 25–36 seconds) until postoperative day 12, and was then switched to warfarin. As the patient had persistent thrombocytosis (Table 2), we conducted a genetic testing. Janus kinase (JAK2) and factor V Leiden (FVL) mutations were detected. Finally, the patient was diagnosed with essential thrombocytosis with JAK2 mutation and APC resistance with FVL mutation. She was transferred to the general ward at postoperative day 13 and discharged at postoperative day 21 without any event. The patient had no signs of recurrence within the 3-year follow-up period, and she is still on oral warfarin and clopidogrel.

Table 1**Additional preoperative laboratory review.**

	Patient's results	Normal range
Antithrombin III (%)	108	80.0–120.0
Lupus like anticoagulant	Negative	0.0–0.0
Protein C activity (%)	109	70.0–130.0
APC resistance	Positive	0.0–0.0
Protein C antigen (%)	94.6	72.0–160.0
Protein S activity (%)	21	55.0–123.0
Protein S antigen (%)	76.3	60.0–150.0
Protein S free (%)	56.0	50.0–150.0
Antinuclear antibody (titer)	Positive >1:160	0.0–0.0
ANCA (MPO Ab) (index)	Negative (0.12)	0.0–1.0
ANCA (PR-3 Ab) (index)	Negative (0.41)	0.0–1.0
Anticardiolipin Ab IgM (MPL)	Positive: 16.6	0.0–10.0
Anticardiolipin Ab IgG (GPL)	Negative: 3.6	0.0–10.0
Antiphospholipid Ab IgM (U/mL)	Negative: 3.10	0.0–10.0
Antiphospholipid Ab IgG (U/mL)	Negative: 2.53	0.0–10.0
C3 (mg/dL)	84.9	90.0–180.0
C4 (mg/dL)	40.5	10.0–40.0
Anti beta2-GP1 IgG (G units)	Negative: 9.3	0.0–20.0
Anti beta2-GP1 IgM (M units)	Negative: 3.9	0.0–20.0

Ab=antibody, ANCA=antineutrophil cytoplasmic antibody, APC=activated protein C, C3=complement 3, C4=complement 4, GP1=glycoprotein 1, Ig=immunoglobulin, MPO=myeloperoxidase, PR-3=proteinase 3.

3. Discussion

Thrombosis is a major cause of morbidity in the perioperative period and is reported to be as high as 36%, despite anticoagulant therapy.^[1] Although advanced age, pregnancy, surgery, immobilization, malignancy, and oral contraceptive use are considered to be important clinical risk factors, the causes of many thrombotic events remain unknown.^[2,9] Thus far, many hereditary deficiencies and genetic variants have the tendency to result in venous thromboembolism (VTE) development, which often recurs.^[3,10] APC resistance occurs in 20% to 60% of patients with recurrent VTE.^[5] Other inherited deficiencies in antithrombin, protein C, and protein S are easily identified by routine laboratory testing, but they approximately account for 5% to 10% of patients with VTE.^[10]

In 1993, Dahlbäck et al^[5] reported an inherited disorder with poor response to the anticoagulant effect of APC. Protein C is converted to APC via proteolytic cleavage by thrombin bound to thrombomodulin—an endothelial cell surface membrane protein. APC, together with protein S, has multiple anticoagulant functions, such as proteolytically inactivating procoagulant factors Va and VIIIa at specific binding sites. APC also indirectly increases fibrinolytic activity by down-regulating thrombin generation.^[11] In patients with APC resistance, APC is inactivated 10-fold slower than the normal rate, and thrombin generation increases as a result. An inherited APC resistance is related to the single point mutation in factor V gene (FVL).^[12] One study reported its presence in 5.27% of Caucasians, compared with 1.23% of blacks and 0.45% of Asians.^[13] The Korean study also reported that FVL mutation is rare and APC resistance is less prevalent in patients with deep vein thrombosis (DVT) (0% and 1.6%, respectively). In this case, patient's preoperative laboratory test showed APC resistance, and postoperative genetic study revealed FVL mutation. Acquired APC resistance is caused by pregnancy, inflammation, existence of antiphospholipid antibody, and high body mass index.^[11]

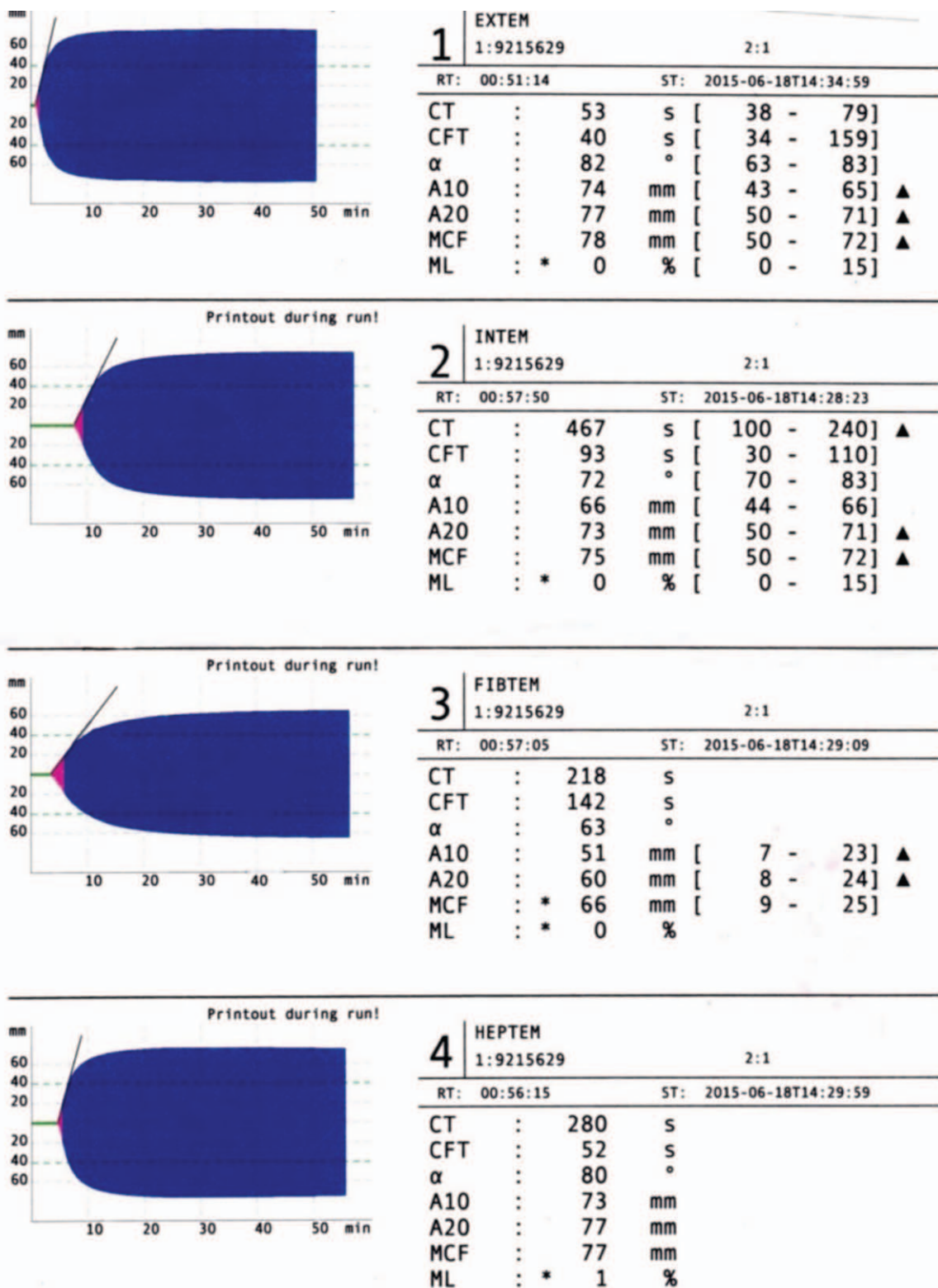


Figure 1. ROTEM was conducted after induction of anesthesia to remove recurrent thrombosis. Despite administration of heparin (500U/h), ROTEM showed hypercoagulable state. In INTEM, A20 and MCF were higher and CT was longer than normal. In FIBTEM, A10, A20, and MCF were relatively high. A10=amplitude 10minutes after CT, A20=amplitude 20minutes after CT, CFT=clot formation time, CT=clotting time, MCF=maximum clot firmness, ROTEM=rotational thromboelastometry.

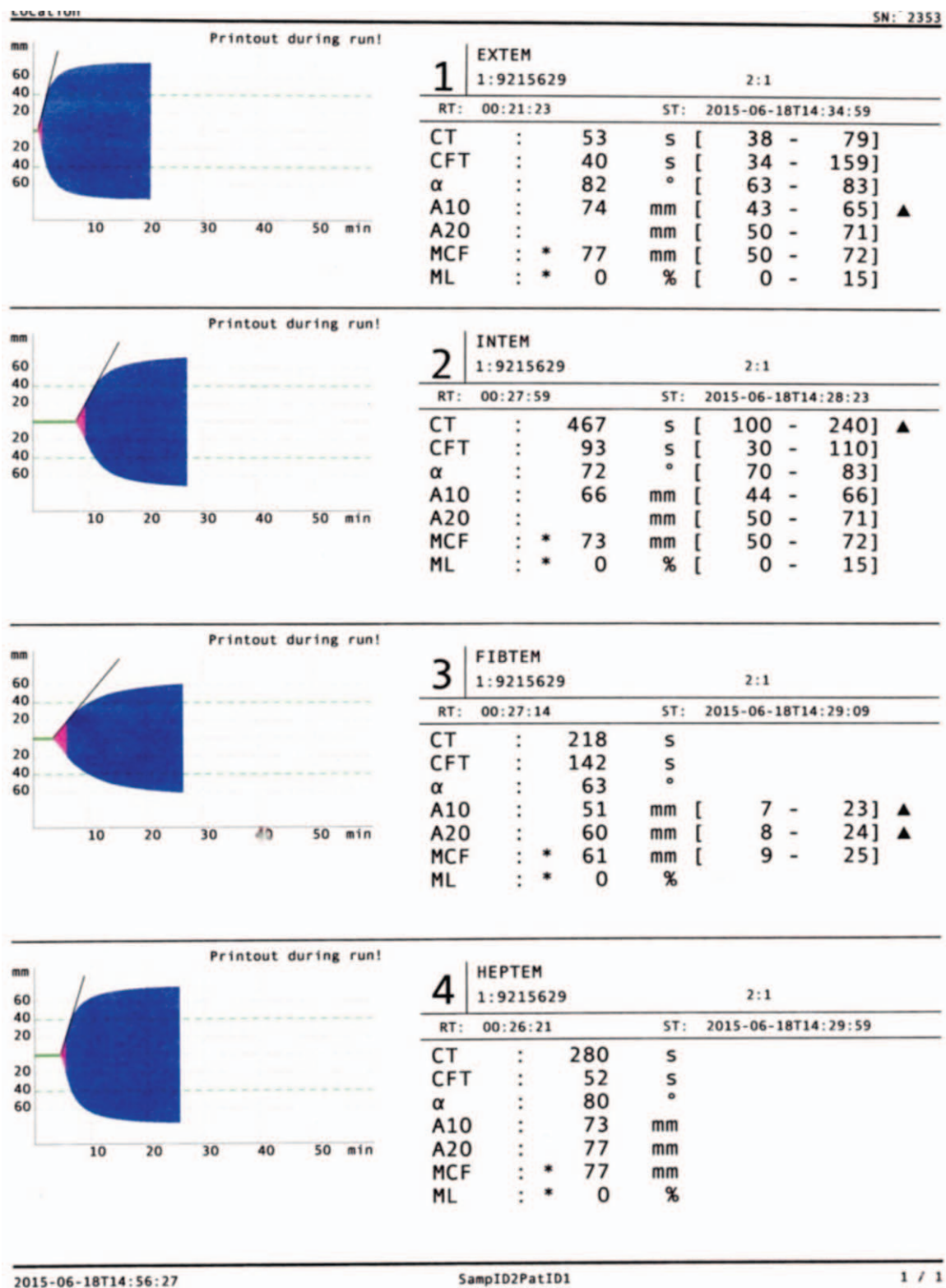


Figure 2. Although the heparin infusion rate was increased to 800U/h, ROTEM showed that hypercoagulable state did not immediately resolved. In INTEM, MCF appeared higher and CT appeared longer than normal. In FIBTEM, A10, A20, and MCF were higher. A10=amplitude 10 minutes after CT, A20=amplitude 20 minutes after CT, CT=clotting time, MCF=maximum clot firmness, ROTEM=rotational thromboelastometry.

The most common clinical manifestation of APC resistance is DVT of the lower limbs with or without pulmonary thromboembolism, and less frequent manifestations include superficial thrombophlebitis and unusual site for thrombosis. Moreover,

APC resistance may be associated with arterial thrombotic event at a relatively young age.^[14] Approximately 60% of APC-resistant patients experience their first thrombotic event due to pregnancy, use of oral contraceptive, trauma, surgery, and

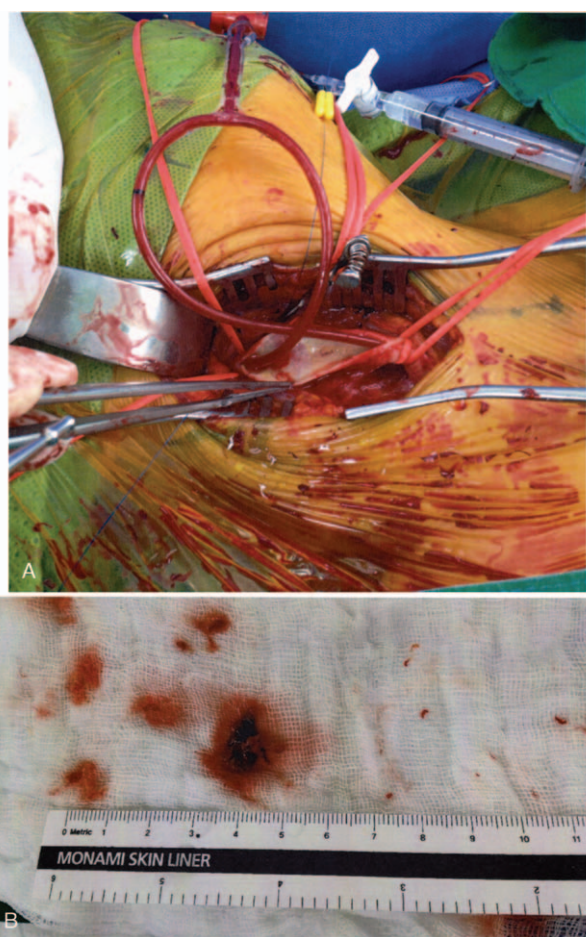


Figure 3. A. Internal carotid artery was exposed and opened longitudinally. Inahara shunt was inserted and thrombectomy was performed without event. B. Thrombi specimen was removed from internal carotid artery (1 × 0.5 cm).

increased not only by duration, type, and extent of trauma or surgery, but also by accumulation of other predisposing factors.^[15] In this case, MRI showed multiple arterial thrombotic defects at postoperative day 1 after CEA. We conducted additional laboratory tests. Results showed APC resistance, presence of antinuclear antibody, presence of anti-cardiolipin antibody (IgM), and thrombocytosis. Homocysteine and lupus antibody were not detected. These laboratory findings indicated that the patient had a tendency to develop blood clot formation. In this case, the role of APC resistance in arterial thrombosis and infarction after vascular surgery cannot be accurately determined, but some studies reported that APC resistance is associated with early graft occlusion and late thrombotic complications after vascular surgery in patients with underlying arterial disease.^[11,16]

A normal person has an APC ratio ranging from 2 to 5 (APC-sensitive plasma), whereas APC-resistant individuals have an APC ratio below or equal to 2.^[11] In this case, patient was reported to have positive APC resistance without showing the exact value. Although some controversy exists, screening for APC resistance may help identify patients who are at higher risk of developing earlier postoperative complications based on the results of these studies.^[11,14]

To date, there are no established guidelines for managing thrombotic patients with APC resistance in the perioperative setting. Prophylactic anticoagulation is administered following the published protocol, because there is no evidence that can serve as a basis to alter the perioperative management. An acute thrombotic episode should be treated with heparin for 5 to 10 days, followed by oral anticoagulant (warfarin) within 24 hours to target an international normalized ratio (INR) of 2.0 to 3.0. In this case, the patient was not administered any anticoagulant before admission. Heparinization and thrombectomy were promptly conducted when postoperative thrombosis was detected, and neurologic deficit was not developed. Although the patient had no history of long-term anticoagulant use, recurrent thrombotic attack with APC resistance should be considered. All patients should be notified that they may require special attention before surgical, medical, or obstetric procedures that can increase the thrombotic risks.^[11]

aging.^[11] Thus, the probability of thrombosis in APC-resistant patients is dependent on the coexistence of other clinical risk factors.^[4,11] The risk of postoperative thrombosis may be

Table 2

Trend of complete blood cell count, blood coagulation test from preoperative to postoperative day 12.

Units	WBC (k/ μ L)	Hb (g/dL)	Hct (%)	Platelet (k/ μ L)	INR	aPTT (s)	aPTT (ratio)
Normal range	(4.0–11.0)	(12.0–16.0)	(36.0–46.0)	(140.0–400.0)	(0.84–1.16)	(21.0–39.4)	(0.72–1.28)
Preop	7.84	12.6	38.3	708	1.13	236.6	7.71
OP	9.14	10.2	30.8	610	1.09	36.7	1.20
POD 1	12.3	11	32.6	616	1.12	120	3.9
POD 2	11.79	9	27.1	666	1.08	142.6	4.64
POD 3	10.67	8.7	27.5	760	1.03	101.7	3.31
POD 4	10.28	8.5	27.5	742		82.6	2.69
POD 5	9.19	8.1	23.4	599		92.5	3.01
POD 6	9.14	8.4	23.9	554		71.2	2.32
POD 7	10.84	11.1	34.9	531		80.8	2.63
POD 8	9.06	11.1	32.6	518		88.3	2.88
POD 9	9.18	11.2	33.5	538		81.1	2.64
POD 10	8.84	12	36.4	554	3.07	82.9	2.70
POD 11	10.8	11.7	34.3	552	1.25	81.7	2.66
POD 12	10.98	11.3	34.6	499	1.14	81.0	2.64

aPTT = activated partial thromboplastin time, Hb = hemoglobin, Hct = hematocrit, INR = international normalized ratio, OP = operative day, POD = postoperative day, Preop = preoperative day, WBC = white blood cell.

Here, the patient had an underlying essential thrombocytosis (ET) with JAK2 mutation, which is present in 50% to 55% of individuals with ET.^[17] Major thrombotic events were reported to be more frequent in ET patients than in the normal population. Several risk factors for developing thrombosis have been known, such as age over 60 years, recurrent attacks, and thrombocytosis of longer duration.^[17] High leukocyte count was found to be an independent risk factor of thrombosis and survival in ET patients.^[18] Previous studies showed that circulating platelet-leukocyte aggregates are found to more frequent in ET patients with thrombosis.^[7] ET patients with JAK2 mutation have an increased risk of venous and arterial thrombosis.^[19] Furthermore, the occurrence of mucosal and gastrointestinal bleeding was likely due to the inverse relationship between platelet and von Willebrand factor.^[20] In 2018, Tefferi et al^[17] described that low-dose aspirin should be used in all ET patients except those with a platelet count of >1500,000/ μ L, with bleeding symptom, or with contraindication to aspirin. Cytoreductive agents should be given in ET patients aged >60 years and/or in patients with a history of thromboembolism and high platelet count (>1,500,000/ μ L). The goal of cytoreductive therapy is to decrease the platelet count below 400,000/ μ L. Hydroxyurea is recommended as first-line myelosuppressive agent in ET patients. Platelet-lowering therapy could be considered in patients with microvascular disturbance, leukocytosis, and/or cardiovascular risk factors, such as hypertension and smoking.

4. Conclusions

Activated protein C resistance appears to represent hypercoagulability associated with early graft occlusion and late thrombotic complications after vascular surgery. In this case, the Korean patient developed recurrent carotid artery thrombosis at postoperative day 1 after CEA, and it was later discovered that she had APC resistance with FVL mutation and essential thrombocytosis with JAK2 mutation. The combination of these 2 diseases increased the patient's risk of thrombosis. It is important to note that there is an increase possibility for patients to develop thrombosis in the perioperative period. Thus, patients with several risk factors for thrombosis should undergo a screening test to detect APC resistance and identify those who are at risk for developing earlier postoperative complications. In addition, a suitable anticoagulant treatment plan based on the patient's underlying disease should be made during the perioperative period.

5. Method

This was a case report. Ethics committee or institutional review board approval was not obtained.

It was not necessary for the case report. The patient signed informed consent for the publication of this case report.

Author contributions

Conceptualization: Jae Min Lee, Il Sang Han, Yong Joon Shin.

Formal analysis: In Young Huh.

Investigation: Jae Min Lee.

Project administration: In Young Huh, Il Sang Han.

Resources: Jae Min Lee, In Young Huh.

Supervision: In Young Huh.

Validation: Hyung Kwan Lee, Yong Joon Shin.

Visualization: In Young Huh, Hyung Kwan Lee, Yong Joon Shin.

Writing – original draft: Jae Min Lee.

Writing – review & editing: Jae Min Lee.

References

- [1] Gordon RJ, Lombard FW. Perioperative venous thromboembolism: a review. *Anesth Analg* 2017;125:403–12.
- [2] Anderson FA Jr, Wheeler HB. Physician practices in the management of venous thromboembolism: a community-wide survey. *J Vasc Surg* 1992;16:707–14.
- [3] Crowther MA, Kelton JG. Congenital thrombophilic states associated with venous thrombosis: a qualitative overview and proposed classification system. *Ann Intern Med* 2003;138:128–34.
- [4] Dahlback B. Activated protein C resistance and thrombosis: molecular mechanisms of hypercoagulable state due to FVR506Q mutation. *Semin Thromb Hemost* 1999;25:273–89.
- [5] Dahlbäck B, Carlsson M, Svensson PJ. Familial thrombophilia due to a previously unrecognized mechanism characterized by poor anticoagulant response to activated protein C: prediction of a cofactor to activated protein C. *Proc Natl Acad Sci U S A* 1993;90:1004–8.
- [6] Svensson PJ, Dahlback B. Resistance to activated protein C as a basis for venous thrombosis. *N Engl J Med* 1994;330:517–22.
- [7] Pedersen OH, Larsen ML, Grove EL, et al. Platelet characteristics in patients with essential thrombocytosis. *Cytometry B Clin Cytom* 2018;00B:000.
- [8] Schafer AL. Thrombocytosis. *N Engl J Med* 2004;350:1211–9.
- [9] Heit JA. Venous thromboembolism epidemiology: implications for prevention and management. *Semin Thromb Hemost* 2002;28 suppl 2:3–13.
- [10] Endler G, Mannhalter C. Polymorphisms in coagulation factor genes and their impact on arterial and venous thrombosis. *Clin Chim Acta* 2003;330:31–55.
- [11] Donahue BS. Factor V Leiden and perioperative risk. *Anesth Analg* 2004;98:1623–34.
- [12] Price DT, Ridker PM. Factor V Leiden mutation and the risks for thromboembolic disease: a clinical perspective. *Ann Intern Med* 1997;127:895–903.
- [13] Ridker PM, Miletich JP, Hennekens CH, et al. Ethnic distribution of factor V Leiden in 4047 men and women. Implications for venous thromboembolism screening. *JAMA* 1997;277:1305–7.
- [14] Bontempo FA, Hassett AC, Faruki H, et al. The factor V Leiden mutation: spectrum of thrombotic events and laboratory evaluation. *J Vasc Surg* 1997;25:271–5.
- [15] Anderson FA Jr, Spencer FA. Risk factors for venous thromboembolism. *Circulation* 2003;107:19–16.
- [16] Donaldson MC, Belkin M, Whittemore AD, et al. Impact of activated protein C resistance on general vascular surgical patients. *J Vasc Surg* 1997;25:1054–60.
- [17] Tefferi A, Vannucchi AM, Barbui T. Essential thrombocythemia treatment algorithm 2018. *Blood Cancer J* 2018;8:2.
- [18] Campbell PJ, MacLean C, Beer PA, et al. Correlation of blood counts with vascular complications in essential thrombocythemia: analysis of the prospective PT1 cohort. *Blood* 2012;120:1409–11.
- [19] Arellano-Rodrigo E, Alvarez-Larrán A, Reverter JC, et al. Platelet turnover, coagulation factors, and soluble markers of platelet and endothelial activation in essential thrombocythemia: relationship with thrombosis occurrence and JAK2 V617F allele burden. *Am J Hematol* 2009;84:102–8.
- [20] Piel-Julian ML, Mahévas M, Germain J, et al. Risk factors for bleeding, including platelet count threshold, in newly diagnosed immune thrombocytopenia adults. *J Thromb Haemost* 2018;16:1830–42.