

# Ischemic Stroke due to Virologically-Confirmed Varicella Zoster Virus Vasculopathy: A Case Series

Takao Hoshino, MD,\* Sono Toi, MD,\* Kunio Toda, MD,\* Yumiko Uchiyama, MD,†  
Hiroshi Yoshizawa, MD,\* Mutsumi Iijima, MD,\* Yuko Shimizu, MD,\* and  
Kazuo Kitagawa, MD\*

**Background:** Limited data are available regarding the characteristics and prognosis of patients with stroke due to varicella zoster virus (VZV) vasculopathy. **Methods:** We studied 4 patients (2 men and 2 women; age, 38-63 years) from a single center who developed acute ischemic stroke due to VZV vasculopathy. The virological diagnosis was confirmed by detecting VZV DNA and/or the IgG antibody to VZV in the cerebrospinal fluid. **Results:** Three patients were taking immunosuppressive agents, including prednisolone and/or methotrexate, at baseline. Each patient had a characteristic skin rash prior to stroke, with the interval from rash to stroke onset ranging from 13 to 122 days. Two patients experienced antecedent cranial nerve palsies; one had the third, seventh, ninth, and 10th nerve palsies and the other had the fourth nerve palsy before stroke. Cerebral infarctions were located in the anterior circulation lesion (n = 1), in the posterior circulation lesion (n = 2), and in both lesions (n = 1). Intracranial arterial stenosis was only identified in one patient on magnetic resonance angiography. A high plasma d-dimer level was detected in 1 patient, whereas high  $\beta$ -thromboglobulin and platelet factor 4 levels were detected in 2 patients. As a result of combined therapies with acyclovir, steroid, and antithrombotic agents, neurological symptoms markedly improved in 3 patients, whereas 1 patient was left with moderate hemiplegia. **Conclusions:** Cranial nerve palsies may be prodromal symptoms of VZV-associated stroke. Increased levels of thrombotic markers may support the use of antithrombotic agents, although the benefit of combined treatment should be determined through larger studies.

**Key Words:** Antithrombotic therapy—cranial nerve—ischemic stroke—varicella-zoster virus—vasculopathy

© 2018 National Stroke Association. Published by Elsevier Inc. All rights reserved.

From the \*Department of Neurology, Tokyo Women's Medical University Hospital, Tokyo, Japan; and †Department of Neurology, Tokyo Women's Medical University Yachiyo Medical Center, Chiba, Japan.

Received July 28, 2018; revision received September 26, 2018; accepted October 1, 2018.

Grant support: None.

Address correspondence to: Takao Hoshino, MD, Department of Neurology, Tokyo Women's Medical University, 8-1 Kawada-cho, Shinjuku-ku, Tokyo 162-8666, Japan. E-mails:

[hoshino.takao@twmu.ac.jp](mailto:hoshino.takao@twmu.ac.jp), [toi.sono@twmu.ac.jp](mailto:toi.sono@twmu.ac.jp),

[joykunio@yahoo.co.jp](mailto:joykunio@yahoo.co.jp), [yyyy@nij.twmu.ac.jp](mailto:yyyy@nij.twmu.ac.jp),

[hyoshizaw@nij.twmu.ac.jp](mailto:hyoshizaw@nij.twmu.ac.jp), [ijijima.mutsumi@twmu.ac.jp](mailto:ijijima.mutsumi@twmu.ac.jp),

[yshimizu@nij.twmu.ac.jp](mailto:yshimizu@nij.twmu.ac.jp), [kitagawa.kazuo@twmu.ac.jp](mailto:kitagawa.kazuo@twmu.ac.jp).

1052-3057/\$ - see front matter

© 2018 National Stroke Association. Published by Elsevier Inc. All rights reserved.

<https://doi.org/10.1016/j.jstrokecerebrovasdis.2018.10.001>

## Introduction

Varicella-zoster virus (VZV), a human neurotropic alphaherpesvirus, causes varicella (i.e., chickenpox) on primary infection, and then becomes latent in ganglionic neurons.<sup>1</sup> Years later, VZV can reactivate in the context of a decline in cell-mediated immunity of a virus host, manifesting as herpes zoster (i.e., shingles). Herpes zoster may be followed by postherpetic neuralgia, as well as various other neurologic complications such as Guillain-Barré syndrome, aseptic meningitis, myelitis, and cranial nerve palsies (e.g., Ramsay-Hunt syndrome, optic neuritis), especially in elderly or immunocompromized individuals.<sup>2-4</sup> Less commonly, ischemic and hemorrhagic strokes can occur secondary to VZV vasculopathy produced by direct VZV infiltration of cranial arteries.<sup>5</sup> VZV vasculopathy needs to be recognized as an important modern cause of cerebrovascular disease, given the projected

increase of aged and immunocompromized patients (e.g., those with cancer, diabetes, acquired immune deficiency syndrome, or those treated with various types of immunosuppressive agents). To date, however, there is a relative paucity of knowledge concerning VZV-associated stroke in terms of clinical characteristics and prognosis, since rarity of the disorder may have hindered large-sample studies. Moreover, treatment and prevention strategies are yet to be established because of a lack of controlled trials.<sup>5</sup> Therefore, an accumulation of cases is necessary for a better understanding of this disorder and guiding optimal management. Here, we report a single-center experience of 4 patients who had ischemic stroke due to virologically-verified VZV vasculopathy.

## Materials and Methods

The study protocol was approved by the ethics committee of our hospital (no. 3031 and 2955R). We retrospectively reviewed our single-center registry of consecutive patients with acute ischemic stroke who had been hospitalized between April 2009 and January 2018, and identified 4 patients (2 men and 2 women; age range, 38-63 years) with stroke due to VZV vasculopathy. We described clinical features, laboratory and radiological examination findings, treatment, and functional outcomes. VZV infection was verified through detecting VZV DNA by polymerase chain reaction (PCR) and/or the anti-VZV IgG antibody by means of an enzyme immune assay in the cerebrospinal fluid (CSF).<sup>5,6</sup> Ischemic stroke was diagnosed based on neurologic observations and magnetic resonance imaging (MRI) findings.

## Results

Demographics, key clinical and examination findings, treatment, and the functional prognosis of the 4 patients are summarized in [Table 1](#).

### Patients

#### Case 1

A 63-year-old woman, who had been treated with oral prednisolone and methotrexate for rheumatoid arthritis, presented with a sudden onset of right oculomotor nerve palsy (i.e., ophthalmoplegia, ptosis, and dilation of the pupil with sluggish light reflex). The following day, she developed right facial nerve palsy, hoarseness, and dysphagia. The left-sided gag reflex was markedly decreased, and paralysis of the left vocal cord was confirmed with direct laryngoscopy, which suggested glossopharyngeal and vagus nerve palsies. A brain MRI and magnetic resonance angiography (MRA) were unremarkable. Routine laboratory tests showed no abnormalities except for a high plasma d-dimer level of 2.9  $\mu\text{g}/\text{mL}$ . The CSF contained 24 lymphocytes/ $\text{mm}^3$  and 91 mg/dL of protein,

whereas intrathecal IgG production was not increased. We started administering intravenous methylprednisolone 1 g/day for 3 days initially. Later, both VZV DNA and VZV IgG (9.8 optical density [OD]) were found to be positive in her CSF, and we added intravenous acyclovir 10 mg/kg<sup>3</sup> times daily for 14 days. On the day that we started acyclovir therapy (i.e., 15 and 14 days later from the onset of oculomotor nerve palsy and facial nerve palsy, respectively), herpes zoster appeared on her right leg and buttock (L2 and L5 myelomere lesions).

Thirteen days after the rash had appeared, she developed left hemiplegia. A diffusion-weighted MRI showed multiple acute brain infarctions ([Fig 1, A-D](#)). The plasma d-dimer level had increased to 13.0  $\mu\text{g}/\text{mL}$ . We started a continuous infusion of heparin; however, asymptomatic brain infarctions newly appeared on the follow-up MRI at 1 month ([Fig 1, E and F](#)). In addition, there was a marked increase in the intrathecal inflammatory response to 153 mg/dL protein and an IgG index of 2.19, whereas the VZV DNA was negative. Therefore, we added a further 2 courses of high-dose methylprednisolone therapy. Systemic examinations to detect malignancies were performed, and all results were negative. The cranial nerve palsies gradually improved, although moderate hemiplegia persisted. This patient was transferred to a rehabilitation center 73 days after the initial stroke event, with a modified Rankin Scale score of 3.

#### Case 2

A 51-year-old man with a 10-year history of poorly-controlled diabetes mellitus was admitted to our department because of dysarthria, dysphagia, left limb ataxia, and thermal hypoesthesia on the right side of his body. Twenty-four days prior to admission, he had consulted a dermatologist, presenting with fever and vesicular eruptions on the left side of his head. He was immediately prescribed oral acyclovir for 3 days, for a suspected diagnosis of herpes zoster, and his symptoms improved at once. On admission, a diffusion-weighted MRI revealed an acute infarction in the left lateral medulla ([Fig 2](#)) with no abnormalities seen in the cranial arteries on MRA. Laboratory tests revealed a leukocyte count of  $11.3 \times 10^3/\text{L}$ , and a glycated hemoglobin (HbA1c) level of 7.8%. Blood coagulation tests showed high  $\beta$ -thromboglobulin and platelet factor 4 (PF4) levels of 132 ng/mL and 45 ng/mL, respectively, whereas the d-dimer level was normal. The CSF contained 18 cells/ $\text{mm}^3$  (16 [88.9%] lymphocytes) and 48 mg/dL of protein. An enzyme immune assay of the CSF revealed IgG antibodies to VZV at a level of 14.0 OD, but PCR for VZV DNA was negative. He promptly underwent treatment with intravenous acyclovir 10 mg/kg<sup>3</sup> times daily for 14 days, as well as argatroban and oral clopidogrel. Within 2 weeks, the neurological deficits had completely recovered and he was discharged 22 days after the stroke onset. He has not experienced a recurrent stroke

**Table 1.** Summary of 4 cases with ischemic stroke due to VZV vasculopathy

Case	Age, y/sex	Comorbidities/ medications	Rash	Interval from rash to stroke	Infarct lesions	MRA	Thrombotic markers			CSF VZV		Treatments	mRS at discharge
							D-dimer	$\beta$ TG	PF4	DNA	IgG		
1	63/woman	RA/PSL, MTX	+	13 days	Multiple	Normal	High	Normal	Normal	+	+	ACV, Steroid, AC	3
2	51/man	Diabetes	+	24 days	Posterior	Normal	Normal	High	High	-	+	ACV, AC, AP	0
3	38/man	SLE/PSL, MTX, TAC, HCQ	+	122 days	Posterior	BA stenosis	Normal	Normal	Normal	-	+	ACV, Steroid, AP	0
4	54/woman	RA, SJS/MTX	+	33 days	Anterior	Normal	Normal	High	High	-	+	ACV, Steroid, AC, AP	2

Abbreviations: AC, anticoagulant; ACV, acyclovir; AP, antiplatelet; BA, basilar artery;  $\beta$ TG,  $\beta$ -thromboglobulin; CSF, cerebrospinal fluid; HCQ, hydroxychloroquine sulfate; MRA, magnetic resonance angiography; MTX, methotrexate; mRS, modified Rankin Scale; PF4, platelet factor 4; PSL, prednisolone; RA, rheumatoid arthritis; SJS, Sjogren's syndrome; SLE, systemic lupus erythematosus; TAC, tacrolimus; VZV, varicella zoster virus.

in more than 3 years since the start of clopidogrel monotherapy.

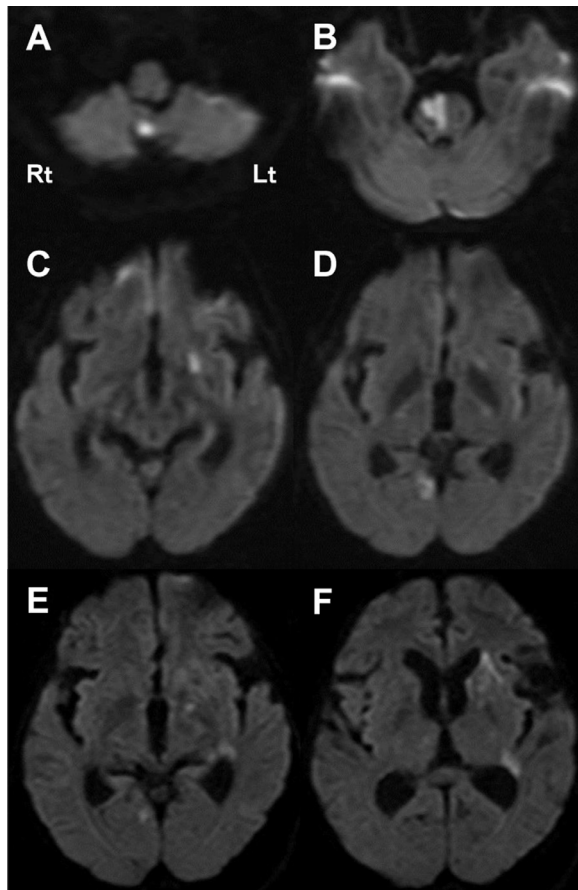
### Case 3

A 38-year-old man, who had been treated for systemic lupus erythematosus (SLE) with prednisolone, methotrexate, tacrolimus, and hydroxychloroquine sulfate, developed fever, nausea, and headache. Four days later, he noted a skin rash on his left arm. With deterioration of his symptoms, he consulted a primary physician and began oral acyclovir therapy for suspected VZV meningitis. Four days after the initiation of the antiviral treatment, he noticed diplopia when rising and was admitted to our department. Neurological examinations revealed a right-sided trochlear nerve palsy. A CSF analysis revealed lymphocytic pleocytosis (246 cells/mm<sup>3</sup>, 191 [77.6%] lymphocytes), an increased level of protein (328 mg/dL) with a high IgG index (0.78). VZV DNA was negative by PCR, but VZV IgG antibody was positive at a level of 67.9 OD. He was immediately treated with intravenous acyclovir 10 mg/kg<sup>3</sup> times daily for 14 days, and the ophthalmoplegia completely disappeared. He was discharged without any neurological deficits.

Approximately 4 months after the first symptoms (i.e., 122 and 118 days from skin rash and diplopia, respectively), he presented with an abrupt onset of dysarthria and left ataxic hemiparesis. A diffusion-weighted MRI of the brain demonstrated a high-intensity lesion in the right ventral pons (Fig 3, A), which showed no contrast enhancement on postgadolinium T1-weighted imaging (Fig 3, B). A brain MRA demonstrated a mild stenosis in the proximal segment of the basilar artery that was not seen at the time of prior hospitalization (Fig 3, C). Routine blood tests, including a complete blood cell count, biochemistry, and coagulation markers, showed no abnormalities. The CSF contained 12 cells/mm<sup>3</sup> (10 [83.3%] lymphocytes) and 99 mg/dL of protein. Anti-VZV IgG was still detected (65.2 OD), whereas amplifiable VZV DNA was not present. There appeared to be no evidence of an acute exacerbation of the SLE in terms of clinical and laboratory markers. He was treated with oral aspirin 100 mg/day, intravenous acyclovir 10 mg/kg<sup>3</sup> times daily for 14 days, and intravenous methylprednisolone 1 g/day for 3 days. Nineteen days after admission, he was discharged having fully recovered. Because the basilar artery stenosis did not change on follow-up MRAs, he was prescribed aspirin for secondary prevention.

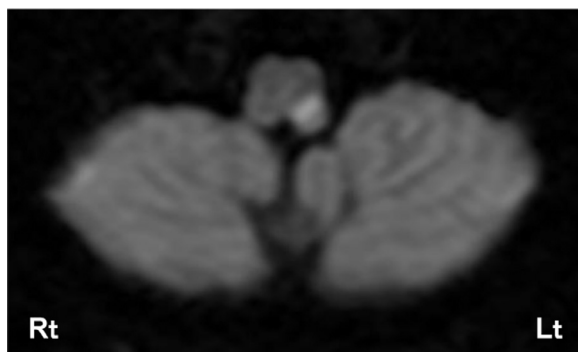
### Case 4

A 54-year-old woman taking methotrexate for rheumatoid arthritis and Sjogren's syndrome was admitted to our department because of sudden dysarthria and weakness of the right side of the face, arm, and leg. Thirty-three days earlier, she had experienced herpes zoster in the



**Figure 1.** Diffusion-weighted MRI in Case 1. Diffusion-weighted MRI revealed acute multiple infarcts (A-D). Follow-up MRI at one month revealed new lesions (E, F). MRI indicates magnetic resonance imaging.

ophthalmic division of the left trigeminal nerve and had received intravenous acyclovir 10 mg/kg<sup>3</sup> times daily for 8 days. Since then, she had complained of occasional nausea and vomiting but she denied fever, chills, headache, or neck stiffness. On admission, a diffusion-weighted MRI demonstrated an acute infarct in the left lenticulostriate artery territory (Fig 4, A-D). There were no stenotic lesions in the cranial large arteries observed on MRA. The blood

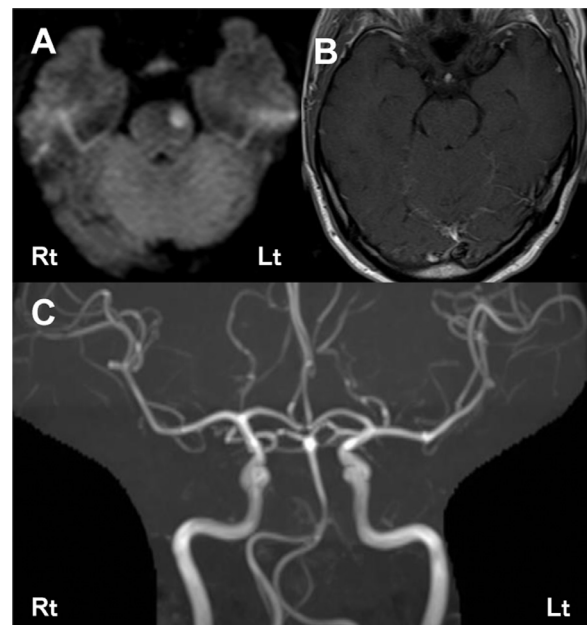


**Figure 2.** Diffusion-weighted MRI in Case 2. Diffusion-weighted MRI on admission revealed an acute infarct in the left lateral medulla. MRI indicates magnetic resonance imaging.

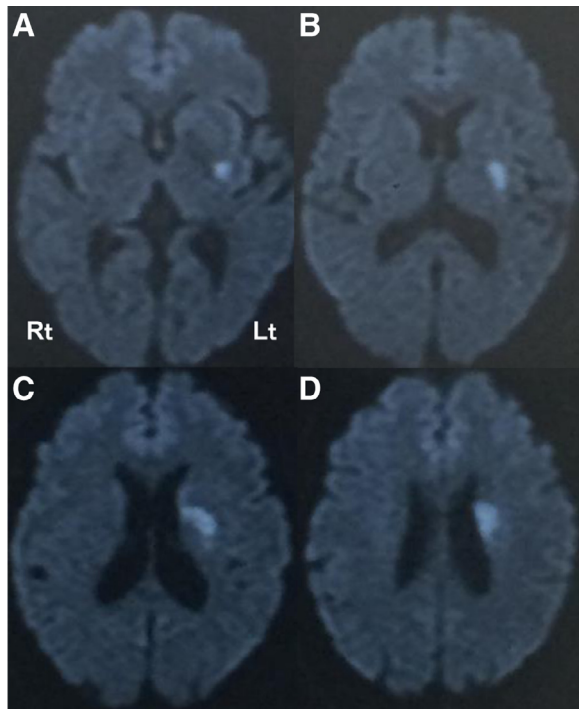
cell count and biochemistry findings were unremarkable. Plasma  $\beta$ -thromboglobulin and PF4 were increased at a level of 136 ng/mL and 55 ng/mL, respectively, whereas the d-dimer level was within the normal range. A CSF analysis revealed a mild lymphocytic pleocytosis (17 cells/mm<sup>3</sup>, 94.1% lymphocytes), a slightly positive VZV IgG antibody at a level of 0.92 OD, and negative VZV DNA. She was treated with intravenous argatroban, oral clopidogrel, and aspirin. There was a gradual improvement in speech and motor function during the hospitalization period, and she became able to walk without assistance. She was transferred to a rehabilitation center 54 days after admission with a modified Rankin Scale score of 2.

### Discussion

This study reviewed our single-center experience of 4 patients with acute ischemic stroke due to VZV vasculopathy. The diagnoses were confirmed through CSF evaluations that revealed positive VZV DNA and/or VZV IgG. All 4 patients were immunocompromised, which should have led to the reactivation of VZV. Of particular note, 2 of the 4 patients had a diagnosis of rheumatoid arthritis and had been treated with methotrexate and/or prednisolone. In addition, one patient was also being treated with prednisolone and methotrexate for SLE. Such backgrounds appear to be comparable with results of a previous nation-wide study in Taiwan that reported a



**Figure 3.** MRI and MRA in Case 3. Diffusion-weighted MRI revealed a high-intensity lesion in the right ventral pons (A). The lesion showed no contrast enhancement on post-gadolinium T1-weighted imaging (B). MRA demonstrated a mild stenosis in the proximal segment of basilar artery (C). MRI indicates magnetic resonance imaging; MRA, magnetic resonance angiography.



**Figure 4.** Diffusion-weighted MRI in Case 4. Diffusion-weighted MRI revealed an acute infarct in the left lenticulostriate artery territory (A-D). MRI indicates magnetic resonance imaging.

significantly elevated 2.53- and 2.30-fold risk of herpes zoster and related stroke in rheumatoid arthritis patients, respectively, than in the general population.<sup>7</sup> Furthermore, a significant association between the use of prednisolone or methotrexate and the herpes zoster risk was shown to be dose-dependent. Therefore, careful monitoring may be needed, particularly for patients with rheumatoid arthritis who are taking specific immunosuppressive agents in high doses.

In our case series, each stroke was preceded by a characteristic skin rash. The interval from rash to stroke was between 2 weeks and 4 months, which was largely consistent with prior reports. According to the largest case study series to date that included 30 virologically-verified patients, the mean interval was 4.1 months.<sup>8</sup> Additionally, that study also reported that 37% of patients lacked antecedent rash before developing stroke. In such circumstances, a diagnosis would not be made unless physicians actively suspected the possibility of VZV vasculopathy and conducted CSF examinations. Therefore, some patients with VZV-related stroke might have been overlooked in our study, and possibly in most of the prior case studies, since it is not considered feasible to conduct lumbar punctures on all stroke patients. Several population-based surveys have demonstrated that VZV infection is a strong risk factor for future stroke, with a 1.02- to 4.52-fold increased risk.<sup>9</sup> This may imply that VZV vasculopathy is more common than expected as a cause of stroke, although direct associations of VZV reactivation with

stroke have not been virologically or histologically proven in these large-sample studies.

Previous histological studies indicated that direct infiltration of the VZV into vessel walls is the main pathogenesis of VZV vasculopathy.<sup>10-12</sup> The VZV can be found in the adventitia in the early phase of infection and in the media and intima later,<sup>10</sup> suggesting that the VZV infiltrates transmurally from the adventitia to the intima, presumably after transaxonal spread to the artery from ganglia. Through measuring substance P concentrations in animal experiments, Saito and Moskowitz demonstrated that cervical dorsal roots and trigeminal ganglia send axonal projections to both cerebral anterior and posterior arteries.<sup>13</sup> If a similar anatomy exists in humans, the spread of the virus from ganglia to multiple arteries could be explained. Indeed, an autopsy study revealed patchy distributions of viral antigen from one artery to another,<sup>11</sup> as with our Case 1. In addition, in immunocompromised patients, VZV has been found to more often involve small arteries, rather than large arteries.<sup>2</sup> This may be comparable with observations from our series that significant stenosis of large arteries was found in only 25% (1/4) of immunocompromised patients on MRA.

It is worth noting that 2 of 4 strokes followed cranial nerve palsies. Cases 1 and 3 experienced third, seventh, ninth and 10th nerve palsies and a fourth nerve palsy before developing stroke, respectively. Cranial neuropathies after herpes zoster infection are not rare, but the underlying mechanisms have not been fully understood.<sup>5</sup> Zoster ophthalmicus<sup>14</sup> and oticus<sup>15</sup> often affect cranial nerves in the proximities through a direct infiltration of VZV. There is also a possibility that immune-mediated mechanisms as seen in Guillain-Barré syndrome are responsible for cranial nerve palsies.<sup>16</sup> Furthermore, cranial neuropathies, particularly when multiple, can be secondary to vasculopathy.<sup>5</sup> It is known that 3 arterial systems play a role in the vascularization of cranial nerves: the inferolateral trunk from the internal carotid artery supplying cranial nerves III, IV, V1, and VI; the middle meningeal system from the external carotid artery supplying nerves V2, V3, and VII; and the ascending pharyngeal system from the external carotid artery supplying nerves IX, X, XI, and XII.<sup>17</sup> Although no definitive mechanism could be identified for our patients, temporal associations (i.e., followed by stroke) may support a vascular pathology. At the very least, cranial neuropathies after herpes zoster infection may be important prodromal symptoms of stroke due to VZV vasculopathy.

Optimal treatments of VZV vasculopathy remain to be established. Patients in previous descriptive studies have usually been treated with intravenous acyclovir, and with steroid therapy simultaneously, in most cases.<sup>5,18</sup> Infected arteries typically show inflammatory responses in histological evaluations,<sup>10,11</sup> supporting the use of steroid therapy. The effect of treatment appears to vary widely depending on patient backgrounds.<sup>8</sup> Acquired immune

deficiency syndrome,<sup>18</sup> adalimumab (a tumor necrosis factor  $\alpha$  antagonist) use,<sup>19</sup> or fingolimod use<sup>20</sup> may be associated with poor outcomes. Despite antithrombotic agents not having been used in most previously-reported cases, we decided to start anticoagulant and/or antiplatelet therapies from the acute phase for all patients, based on the elevated markers of thrombogenesis (i.e., d-dimer) and platelet activation (i.e.,  $\beta$ -thromboglobulin and PF4). Our choice of treatment is also supported by findings from a previous pathological study that demonstrated in situ thrombosis of the occluded arteries in VZV vasculopathy.<sup>21</sup> The pattern of increased thrombotic markers differed in each patient. A high d-dimer level and normal  $\beta$ -thromboglobulin/PF4 levels were found in Case 1, whereas a normal d-dimer level and high  $\beta$ -thromboglobulin/PF4 levels were found in Cases 2 and 4. These variations may reflect a difference in the process of thrombus formation between the patients, and should possibly be taken into account during antithrombotic agent selection and use. As a result of antiviral, steroidal, and antithrombotic therapies, stroke symptoms had been maximal at onset and almost resolved at 3 months. A larger number of such patients are warranted to better determine the benefits of the combined treatment in terms of acute management and long-term secondary prevention.

## Conclusions

Clinicians should be aware of VZV vasculopathy as a potential stroke etiology in immunocompromized patients following herpes zoster infection, especially in those taking methotrexate. Also, neurologists who treat stroke patients need to check the history of VZV infection and consider diagnostic lumbar puncture in high-risk patients. Cranial nerve palsies may be prodromal symptoms of VZV-associated stroke. Thrombotic markers, including d-dimer,  $\beta$ -thromboglobulin, or PF4, are often increased, which helps to identify the mechanism of thrombus formation and may promote the use of acute antithrombotic therapy. The combined use of acyclovir, steroid therapy, and antithrombotic agents could be a preferred treatment for VZV-related stroke, although further controlled trials are needed to verify this.

## References

- Gershon AA, Breuer J, Cohen JJ, et al. Varicella zoster virus infection. *Nat Rev Dis Primers* 2015;1:15016.
- Gilden DH, Kleinschmidt-DeMasters BK, LaGuardia JJ, et al. Neurologic complications of the reactivation of varicella-zoster virus. *N Engl J Med* 2000;342:635-645.
- Echevarría JM, Casas I, Martínez-Martín P. Infections of the nervous system caused by varicella-zoster virus: a review. *Intervirology* 1997;40:72-84.
- Steiner I, Kennedy PG, Pachner AR. The neurotropic herpes viruses: herpes simplex and varicella-zoster. *Lancet Neurol* 2007;6:1015-1028.
- Gilden D, Cohrs RJ, Mahalingam R, et al. Varicella zoster virus vasculopathies: diverse clinical manifestations, laboratory features, pathogenesis, and treatment. *Lancet Neurol* 2009;8:731-740.
- Nagel MA, Forghani B, Mahalingam R, et al. The value of detecting anti-VZV IgG antibody in CSF to diagnose VZV vasculopathy. *Neurology* 2007;68:1069-1073.
- Liao TL, Lin CH, Chen HH, et al. Significant associations of neurological complications of Herpes Zoster with stroke in rheumatoid arthritis patients. *J Am Heart Assoc* 2017;6:e006304.
- Nagel MA, Cohrs RJ, Mahalingam R, et al. The varicella zoster virus vasculopathies: clinical, CSF, imaging, and virologic features. *Neurology* 2008;70:853-860.
- Yang SY, Li HX, Yi XH, et al. Risk of stroke in patients with Herpes Zoster: a systematic review and meta-analysis. *J Stroke Cerebrovasc Dis* 2017;26:301-307.
- Nagel MA, Traktinskiy I, Azarkh Y, et al. Varicella zoster virus vasculopathy: analysis of virus-infected arteries. *Neurology* 2011;77:364-370.
- Gilden DH, Kleinschmidt-DeMasters BK, Wellish M, et al. Varicella zoster virus, a cause of waxing and waning vasculitis: the New England Journal of Medicine case 5-1995 revisited. *Neurology* 1996;47:1441-1446.
- Melanson M, Chalk C, Georgevich L, et al. Varicella-zoster virus DNA in CSF and arteries in delayed contralateral hemiplegia: evidence for viral invasion of cerebral arteries. *Neurology* 1996;47:569-570.
- Saito K, Moskowitz MA. Contributions from the upper cervical dorsal roots and trigeminal ganglia to the feline circle of Willis. *Stroke* 1989;20:524-526.
- Liesegang TJ. Herpes zoster ophthalmicus natural history, risk factors, clinical presentation, and morbidity. *Ophthalmology* 2008;115:S3-12.
- Sweeney CJ, Gilden DH. Ramsay Hunt syndrome. *J Neurol Neurosurg Psychiatry* 2001;71:149-154.
- Shoji H, Hirose K, Uono M, et al. A case of facial diplegia following herpes zoster ophthalmicus. *Eur Neurol* 1980;19:327-329.
- Lapresle J, Lasjaunias P. Cranial nerve ischaemic arterial syndromes. A review. *Brain* 1986;109:207-216.
- Gilden DH, Bennett JL, Kleinschmidt-DeMasters BK, et al. The value of cerebrospinal fluid antiviral antibody in the diagnosis of neurologic disease produced by varicella zoster virus. *J Neurol Sci* 1998;159:140-144.
- Baek W, Lee SG, Kim YS, et al. Fatal varicella-zoster virus vasculopathy associated with adalimumab therapy. *Arch Neurol* 2012;69:1193-1196.
- Ratchford JN, Costello K, Reich DS, et al. Varicella-zoster virus encephalitis and vasculopathy in a patient treated with fingolimod. *Neurology* 2012;79:2002-2004.
- Eidelberg D, Sotrel A, Horoupian DS, et al. Thrombotic cerebral vasculopathy associated with herpes zoster. *Ann Neurol* 1986;19:7-14.