
**34th ANNUAL MEETING — AMERICAN COLLEGE OF ANGIOLOGY
PARADISE ISLAND, BAHAMAS — OCTOBER, 1987
SYMPOSIUM PROCEEDINGS**

**Traumatic Aneurysms of Cerebral Vessels:
A Case Study and Review of the Literature**



Emilio D. Soria, M.D.*

Assistant Professor of Neurology,
SUNY at Buffalo, School of Medicine,
V.A. Medical Center,
Buffalo, New York

Margaret W. Paroski, M.D., F.A.C.A.**

and

Mary E. Schamann B.A.†

BUFFALO, NEW YORK

Abstract

Traumatic cerebral aneurysms (TCAs) are rare: few more than 100 cases are recorded in the world literature. TCAs are located predominantly in the supratentorial compartment and are classified as either "true" or "false." A true aneurysm is a dilation resulting from partial disruption of the arterial wall. A false aneurysm results from a full-thickness tear, with the scar from the brain tissue or an organized hematoma acting as the aneurysmal wall.

The authors present a case of a false traumatic aneurysm of the pericallosal artery, which was discovered in a young patient fourteen months after a self-inflicted gunshot wound to his head. The aneurysm was an incidental finding on a CT scan performed for the investigation of his late posttraumatic seizures. Its presence was confirmed by angiography.

The interval between the traumatic episode and the diagnosis of a TCA usually ranges from a few hours

** Assistant Professor of Neurology, SUNY at Buffalo, School of Medicine, V.A. Medical Center, Buffalo, New York

† Medical Student, SUNY at Buffalo, School of Medicine, Buffalo, New York

* Photograph by Nicholas Gabriele

Presented at the 34th Annual Meeting of the American College of Angiology, Paradise Island, Bahamas, October, 1987

to a few weeks, for most are discovered by angiography performed in the acute or subacute stage of a head injury. The long interval between the injury and the diagnosis in our case is exceptional.

A previous CT scan done four months after the injury did not reveal the aneurysm, which strongly suggests a protracted growth of the aneurysmal sac long after the trauma.

Introduction

There are many categories of intracranial aneurysms: mycotic, congenital, arteriosclerotic, and traumatic.

Traumatic cerebral aneurysms (TCAs) are distinctly uncommon.¹ The report on the cooperative study of intracranial aneurysms and subarachnoid hemorrhage in 1968,² based on 6368 cases of intracranial aneurysms and arteriovenous malformations, did not record a single case of TCA. Indeed, the analysis of 2187 penetrating wounds of the brain from U.S. soldiers in Vietnam showed only 2 cases.³

TCAs can be divided into two main categories according to their pathogenesis: true and false aneurysms.⁴

The development of true aneurysms in the cerebral arteries can be explained by their distinctive histologic characteristics. They differ from arteries seen elsewhere in the body in that their elastic tissue is almost exclusively concentrated in their thin internal elastic lamina. When the internal elastic lamina is broken, the artery can herniate and expand through the gap, producing a true aneurysm.

In the cases where a rent in the vascular wall has produced a complete disruption of all layers, a false aneurysm may develop, as the cavity of an encapsulated hematoma may communicate with the arterial lumen. The wall is composed of fibroconnective tissue, which results from the organization of the clot. It is arguable whether the cerebral substance itself could provide a buttress strong enough to allow formation of a false aneurysm.

TCAs can also be classified by their basal or peripheral location in the intracranial cavity.⁵

Basal aneurysms occur as the result of injury to large basal arteries as they traverse the skull. Traumatic aneurysms of the intracranial carotid artery are relatively common, and most reported cases have occurred with fractures of the base of the skull caused by blunt head injuries.⁶ These aneurysms often extend into the sphenoid sinus and may cause massive epistaxis when ruptured. Monocular blindness, primary optic atrophy, and a bruit over the orbit are also often present.

The most frequently described cause of traumatic aneurysms of the cortical peripheral arteries is a direct arterial injury by a penetrating wound. These direct injuries are caused by a wide variety of weapons and missiles or by a fragment of bone in a depressed skull fracture.^{7,8} The trauma can sometimes be iatrogenic, as in a case of an aneurysm seen in an artery directly under a previous burr hole site,⁹ and an aneurysm underlying the anterior fontanelle in a child who underwent repeated needle taps of a subdural hematoma.¹⁰

The development of TCA is also possible with closed head injury.¹¹ The cortical cerebral arteries are in close relation to the skull and the hard infoldings of the dura mater. Blunt trauma

to these cortical branches includes injury to the pericallosal artery by the edge of the falx or to the middle cerebral artery by the sphenoid ridge.¹²

Case Report

A twenty-four-year-old man went to a hunting party in Arizona on New Year's Eve and became intoxicated with alcohol. While performing a parody of Russian roulette he suffered a self-inflicted small-caliber gunshot to his head. The bullet entered the right temple, traversed the frontal lobes, and perforated the left temporal bone, but did not exit through the scalp on that side. The bullet was palpable beneath the scalp on the left temple.

He was admitted in a semicomatose state to a local hospital, where on the day of admission, he underwent exploration and debridement of the entry wound.

A CT scan done on admission without contrast enhancement showed the transverse path of the gunshot wound from right frontal to left frontal region with hemorrhage along the tract. There was a large hematoma in the right frontal lobe intermixed with multiple small metallic and bony fragments. The lateral ventricles appeared somewhat compressed, but there was no midline shift. A minimal subarachnoid hemorrhage was also noted.

Three days after admission he underwent debridement of the exit wound. The bullet, broken into pieces, was delivered from the subgaleal compartment, and four fragments of loose bone were removed. Through the bony defect, a portion of necrotic cerebral tissue ejected spontaneously. A small fungating mass of necrotic brain and a small hematoma were resected. It was decided not to attempt a debridement of his frontal lobes for fear of increasing the functional loss.

In the immediate postoperative period he developed fever and nuchal rigidity. On the fifth day after admission a spinal tap was performed. CSF analysis revealed a white blood cell count of 1,485 cells μ L, a red blood cell count of 14,147 cells/ μ L, a glucose level of 34 mg/dL, and a protein content of 84 mg/dL. Spinal fluid cultures were negative. It was considered that most likely the patient had meningismus secondary to the presence of cerebral debris and blood products in the CSF. He was treated with antibiotics for several days and the fever and meningeal signs subsided.

He continued to do well; his level of alertness progressively improved. Twenty-four days after his admission he was transferred to the Veterans Administration Medical Center in Buffalo, New York. At the time of discharge there was no evidence of any focal neurologic deficits except for a mild change in his judgment and personality. He was discharged on phenytoin 100 mg qid for the prophylactic treatment of seizures.

He resumed his daily activities, very similar to the life-style prior to his head injury. He was periodically seen as an outpatient in the neurology clinic, where he had normal results from neurologic examination, except for bilateral anosmia and a mild personality disturbance characterized by lack of motivation. A neuropsychological evaluation demonstrated that the recovery of his intellectual capabilities was fairly complete, and he appeared to be functionally at a level very near estimates of his premorbid intelligence.

A CT scan, with and without contrast enhancement, performed four months after the injury, revealed a band-like low-density area that ran across the posterior portion of the orbital

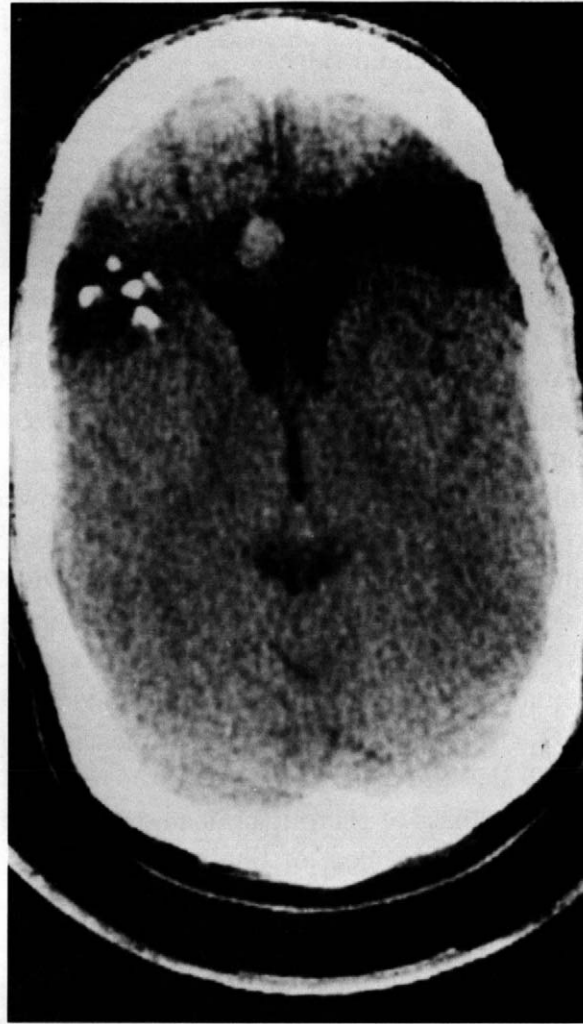

FIG. 1. CT scan of the head shows a round, contrast-enhancing lesion in the midline, anterior to the frontal horns. The lesion is located in the bullet trajectory across the frontal lobes. There are several scattered bone fragments on the right side.

aspect of both frontal lobes. In the right frontal lobe multiple tiny high-density areas were seen, which most likely represented scattered bony fragments.

Fourteen months after the injury he had a generalized tonic-clonic seizure with urinary incontinence. The seizure prompted a repeated CT scan (Fig. 1) that again showed the bullet track across the frontal lobes and some scattered bone fragments, but at this time there was evidence of a high-density, contrast-enhancing round lesion, located in the midline anterior to the frontal horns. This lesion was diagnosed as a possible aneurysm, and a cerebral angiogram was performed. The angiogram revealed an irregularly shaped aneurysm in the pericallosal portion of the left anterior cerebral artery (Fig. 2). The aneurysm did not have a neck (Fig. 3) and had a delayed emptying, for it was clearly visible in the capillary and venous phases of the angiogram (Fig. 4). There was no evidence of vasospasm and the rest of the intracranial vascular system was normal.

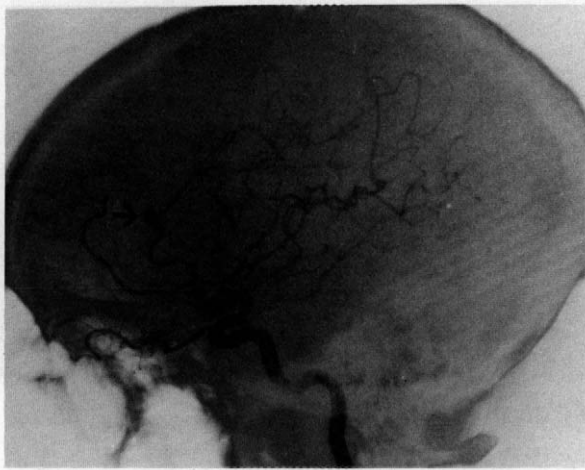

FIG. 2. Left carotid angiography, lateral view. An irregularly shaped aneurysm is visible in the pericallosal artery (arrow).

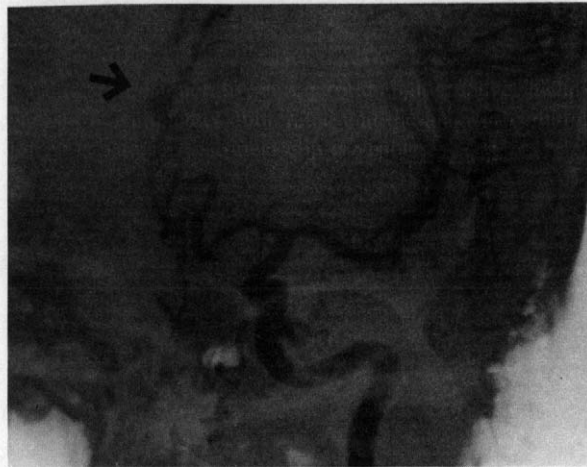

FIG. 3. Left carotid angiography, anteroposterior view. The aneurysm (arrow) has no neck, and it is not located at a branching point.

He underwent a right frontal craniotomy and aneurysmectomy. Temporary clips were placed on the left pericallosal artery, proximal and distal to the aneurysmal dome. The aneurysmal sac was then completely excised and the free edges were oversewn to reconstitute blood flow along the artery. A clip was placed around the surgical repair.

The pathologic examination revealed a false aneurysmal sac that measured approximately 15 mm in diameter. It showed a dome-shaped, smooth fibrous wall of cicatricial collagenous tissue. Elastic stain was negative.

He recovered from the operation uneventfully. One month later, a cerebral angiogram demonstrated normal patency of the anterior cerebral artery and complete obliteration of the aneurysm (Fig. 5).

After the operation, he has been periodically followed in the neurology clinic and for the last two years has continued to do well. He has occasional tonic-clonic seizures, mostly during sleep, for which he is treated with phenytoin.

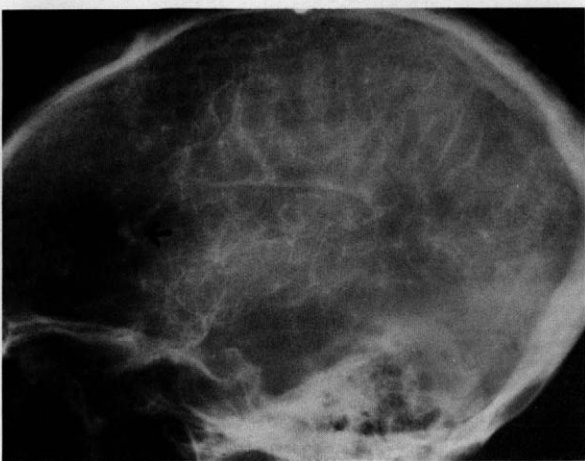

FIG. 4. Left carotid angiography, early venous phase. The aneurysm is still clearly visible (arrow), demonstrating a delayed emptying of the sac.

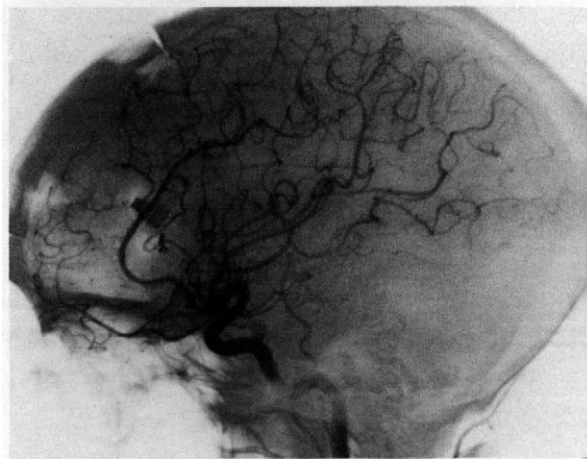


FIG. 5. Postoperative left carotid angiography. The aneurysm is completely obliterated and the anterior cerebral artery is patent. A surgical clip is visible.

Discussion

TCAs are difficult to uncover on clinical grounds alone. In 1981 Bollinger described a mechanism of delayed cerebral hemorrhage following head injury.¹³ He suggested that the cause of this “delayed apoplexy” was the local brain necrosis with softening, resulting in areas of weakening of the vessel walls that may eventually rupture. When cerebral angiography became widely used, it was found that some of the cases of delayed apoplexy were due to the rupture of a TCA.

Other than the syndrome of delayed deterioration after a head injury, there are few definite clinical signs pointing to the diagnosis of a ruptured TCA. In the complex scenario of the acute stage of a severe head injury there is such a manifold etiology of delayed deterioration, ranging from the development of cerebral edema to intercurrent metabolic abnormalities, that the presence of the syndrome is hardly specific.

The typical history of a ruptured TCA is an initial coma at the time of the head injury, followed by a lucid interval of variable duration. A very sudden deterioration takes place at the time of the rupture. The deterioration tends to be more rapid and the lucid interval more extended than in other delayed complications of head injury, such as epidural hematomas.¹⁴ Most TCAs are discovered by the performance of a cerebral angiogram for the evaluation of cerebral complications of a head injury. Since CT scan has almost completely replaced cerebral angiography in the evaluation of head-injured patients, the incidental radiologic diagnosis of TCA will be decreased, because CT scan will demonstrate the presence of a hematoma but will miss the underlying aneurysm unless it reaches a sufficiently large size to be visible, as in our case.

In most cases in the literature, the TCA has ruptured or was discovered by angiography in the initial three weeks after the injury. The average lucid interval in the cases reported seems to be about fourteen days.⁵ The discovery of the aneurysm, in our case fourteen months after the gunshot injury, is exceptional. However, a case of a TCA of the left middle cerebral artery that presented with fatal rupture ten years after a shotgun injury has been reported.¹⁵

The detection of the TCA in our case was a totally unexpected incidental finding of a CT scan done for the investigation of delayed posttraumatic seizures. There were no clues in the clinical history that would have suggested the presence of a TCA. It is very doubtful whether the posttraumatic seizures were in any way connected to the growth of the lesion.

TCAs can be set apart from congenital and mycotic aneurysms by their clinical and radiologic features.

Mycotic aneurysms are often multiple. Usually there is no history of trauma, while a history of severe sepsis — typically a bacterial endocarditis — is often present.

Unlike TCAs, congenital aneurysms usually arise close to the circle of Willis at the base of the brain rather than in distal cortical branches.

In this patient, the traumatic etiology of the aneurysm was quite obvious, for it was located in the track left in the brain by the bullet, but other typical features of the traumatic variety of aneurysms were also present. As in our case, TCAs have an irregular contour of the sac, they are located at a site other than a branching point, and do not have a neck.^{4,5} The delay in emptying of the sac in TCAs, often reported in the literature, was also present in this case.

The evolution of TCAs is poorly understood. A few reports of serial angiography of these lesions that demonstrated a progressive enlargement have appeared,¹⁶ but there have been a few instances of a decrease in size or even of spontaneous disappearance, presumably caused by thrombus formation in the aneurysmal lumen.¹⁷ In our case, a CT scan done four months after the injury did not reveal the presence of the aneurysm, whereas the CT scan done fourteen months after the injury did, which provides evidence for the protracted growth of the lesion.

TCAs run an unpredictable course. A devastating rupture is a frequent event.¹⁴ Their usual peripheral location reduces the risk of surgical intervention, and early diagnosis is, therefore, most important.¹ In this case, the aneurysm was successfully treated and the subsequent course was uneventful.

Emilio D. Soria, M.D.
Neurology Department
Veterans Administration Medical Center
3495 Bailey Avenue
Buffalo, NY 14215

References

- Jakobsson KE, Carlsson C, Elfverson J, et al: Traumatic aneurysms of cerebral arteries. A study of five cases. *Acta Neurochir* 71:91-98, 1984.
- Locksley HB: Report on the cooperative study of intracranial aneurysms and subarachnoid hemorrhage. Based on 6368 cases in the cooperative study. *J Neurosurg* 25:219-239, 1968.
- Hammon WM: Analysis of 2187 consecutive penetrating wounds of the brain from Vietnam. *J Neurosurg* 34:127-131, 1971.
- Burton C, Velasco F, Dorman J: Traumatic aneurysm of a peripheral cerebral artery: Review and case report. *J Neurosurg* 28:468-474, 1968.
- Benoit BG, Wortzman G: Traumatic cerebral aneurysms. Clinical features and natural history. *J Neurol Neurosurg Psychiatry* 36:127-138, 1973.
- Araki C, Handa H, Handa J, et al: Traumatic aneurysm of the intracranial extradural portion of the internal carotid artery. Report of a case. *J Neurosurg* 23:64-67, 1965.
- Acosta C, Williams PE Jr, Clark K: Traumatic aneurysms of the cerebral vessels. *J Neurosurg* 36:531-536, 1972.
- Chaddock WM: Traumatic cerebral aneurysm due to speargun injury. Case report. *J Neurosurg* 31:77-79, 1969.
- Eichler A, Story JL, Bennett DE, et al: Traumatic aneurysm of a cerebral artery. Case report. *J Neurosurg* 31:72-76, 1969.
- Overton Mc III, Calvin TH Jr: Iatrogenic cerebral cortical aneurysm. Case report. *J Neurosurg* 24:672-675, 1966.
- Smith DR, Kempe LG: Cerebral false aneurysm formation in closed head trauma. Case report. *J Neurosurg* 32:357-359, 1970.
- Smith KR, Bardenheier JA III: Aneurysm of the pericallosal artery caused by closed cranial trauma. Case report. *J Neurosurg* 29:551-554, 1968.
- Bollinger O: Über traumatische Spät-Apoplexie; ein Beitrag zur Lehre von der Hirnerschütterung. *Festschr Rud Virchow* 2:457-470, 1981.
- Fleischer AS, Patton JM, Tindall GT: Cerebral aneurysms of traumatic origin. *Surg Neurol* 4:233-239, 1975.
- Courville CB: Traumatic aneurysm of an intracranial artery. Description of a lesion incident to a shotgun wound of the skull and brain. *Bull Los Angeles Neurol Soc* 25:48-54, 1960.
- Bjorkesten C, Troupp H: Changes in the size of intracranial arterial aneurysms. *J Neurosurg* 19:583-588, 1962.
- Rumbaugh CL, Bergeron RT, Talalla A, et al: Traumatic aneurysms of the cortical cerebral arteries. Radiographic aspects. *Radiology* 96:49-54, 1970.