

# Teaching Video NeuroImages: Cerebral amyloid angiopathy-related transient focal neurologic episodes

## A video-EEG report

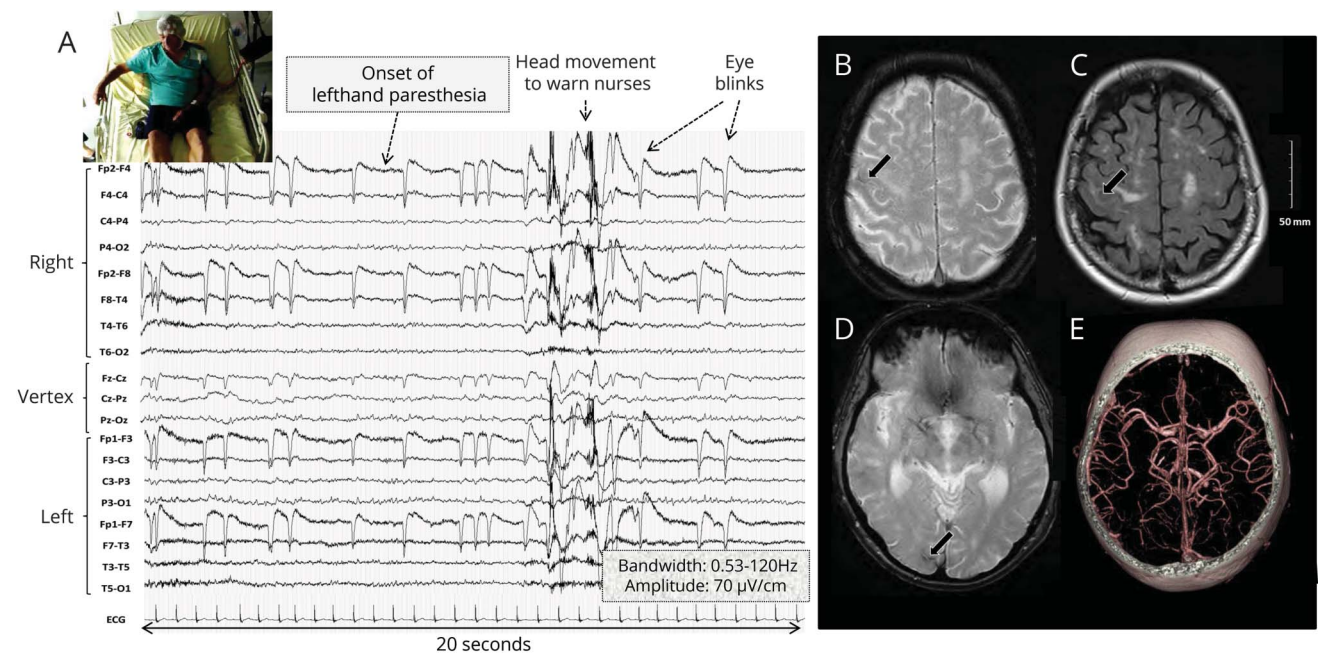
Alain Viguier, MD, Pierre Girardie, MD, Nicolas Raposo, MD, MSc, Lionel Calviere, MD, Marie Denuelle, MD, Luc Valton, MD, Jean Marc Olivot, MD, PhD, Jean Francois Albuher, MD, Fabrice Bonneville, MD, PhD, and Jonathan Curot, MD, MSc

### Correspondence

Dr. Viguier  
viguier.a@chu-toulouse.fr

*Neurology*® 2018;91:e2033-e2034. doi:10.1212/WNL.0000000000006555

### Figure EEG and imaging



(A) Video-EEG recording during one of the 4 transient focal neurologic episodes without any change on EEG. Acute subarachnoid hemorrhage in the right central sulcus: (B) hypointensity on T2\* and (C) hyperintensity on fluid-attenuated inversion recovery. (D) Cortical superficial siderosis in right medial occipitotemporal gyrus on T2\*. (E) CT angiography discloses no vascular abnormality.

A 77-year-old man, with no trauma history, presented with recurrent transient left arm paresthesia for 2 weeks. Brain MRI showed acute cortical subarachnoid hemorrhage and criteria for probable cerebral amyloid angiopathy (CAA) (figure, video 1). A 24-hour video-EEG recorded 4 transient focal neurologic episodes (TFNE) with the following sequence: paresthesia always starting from the hand and slowly spreading to the arm, the shoulder, and sometimes the perioral area. During these episodes, EEG remains unchanged.

### MORE ONLINE

#### Video

#### Teaching slides

[links.lww.com/WNL/A743](https://links.lww.com/WNL/A743)

From the Departments of Neurology (A.V., P.G., N.R., L.C., M.D., L.V., J.M.O., J.F.A., J.C.) and Neuroradiology (F.B.), Hôpital Pierre-Paul Riquet, Centre Hospitalier Universitaire de Toulouse; Toulouse NeuroImaging Center (A.V., N.R., L.C., J.M.O., J.F.A., F.B.), Université de Toulouse, INSERM U1214, UPS; CerCo (L.V., J.C.), CNRS, UMR5549, Toulouse Mind and Brain Institute; and Centre de Recherche Cerveau et Cognition (L.V., J.C.), Université de Toulouse, UPS, France.

Go to [Neurology.org/N](https://Neurology.org/N) for full disclosures. Funding information and disclosures deemed relevant by the authors, if any, are provided at the end of the article.

Although simple partial seizure may not have an EEG correlate, this case supports the hypothesis of focal cortical spreading depression rather than ischemic or epileptic origin of CAA-related TFNE.<sup>1</sup>

### Author contributions

A. Viguier, P. Girardie, and J. Curot: case report concept and design, drafting the manuscript. A. Viguier, P. Girardie, L. Calviere, and F. Bonneville: patient's clinical assessment, acquisition of clinical and radiologic data. J. Curot, M. Denuelle, and L. Valton: acquisition, analysis, and interpretation of EEG video recording. A. Viguier, P. Girardie, N. Raposo,

L. Calviere, J.M. Olivot, J.F. Albucher, and J. Curot: revised the manuscript.

### Study funding

No targeted funding reported.

### Disclosure

The authors report no disclosures relevant to the manuscript. Go to [Neurology.org/N](http://Neurology.org/N) for full disclosures.

### Reference

1. Ni J, Auriel E, Jindal J, et al. The characteristics of superficial siderosis and convexity subarachnoid hemorrhage and clinical relevance in suspected cerebral amyloid angiopathy. *Cerebrovasc Dis* 2015;39:278–286.

# Neurology®

## Teaching Video NeuroImages: Cerebral amyloid angiopathy-related transient focal neurologic episodes: A video-EEG report

Alain Viguier, Pierre Girardie, Nicolas Raposo, et al.

*Neurology* 2018;91:e2033-e2034

DOI 10.1212/WNL.0000000000006555

**This information is current as of November 19, 2018**

<b>Updated Information &amp; Services</b>	including high resolution figures, can be found at: <a href="http://n.neurology.org/content/91/21/e2033.full">http://n.neurology.org/content/91/21/e2033.full</a>
<b>References</b>	This article cites 1 articles, 0 of which you can access for free at: <a href="http://n.neurology.org/content/91/21/e2033.full#ref-list-1">http://n.neurology.org/content/91/21/e2033.full#ref-list-1</a>
<b>Subspecialty Collections</b>	This article, along with others on similar topics, appears in the following collection(s): <b>All Epilepsy/Seizures</b> <a href="http://n.neurology.org/cgi/collection/all_epilepsy_seizures">http://n.neurology.org/cgi/collection/all_epilepsy_seizures</a> <b>EEG; see Epilepsy/Seizures</b> <a href="http://n.neurology.org/cgi/collection/eeg_see_epilepsy-seizures">http://n.neurology.org/cgi/collection/eeg_see_epilepsy-seizures</a> <b>Subarachnoid hemorrhage</b> <a href="http://n.neurology.org/cgi/collection/subarachnoid_hemorrhage">http://n.neurology.org/cgi/collection/subarachnoid_hemorrhage</a>
<b>Permissions &amp; Licensing</b>	Information about reproducing this article in parts (figures, tables) or in its entirety can be found online at: <a href="http://www.neurology.org/about/about_the_journal#permissions">http://www.neurology.org/about/about_the_journal#permissions</a>
<b>Reprints</b>	Information about ordering reprints can be found online: <a href="http://n.neurology.org/subscribers/advertise">http://n.neurology.org/subscribers/advertise</a>

*Neurology*® is the official journal of the American Academy of Neurology. Published continuously since 1951, it is now a weekly with 48 issues per year. Copyright © 2018 American Academy of Neurology. All rights reserved. Print ISSN: 0028-3878. Online ISSN: 1526-632X.

