

Teaching Video NeuroImages: Oculopalatal myoclonus

A possible consequence of brainstem injury

Omolara Lawal, MBBS, and Adeniyi Fisayo, MD

Neurology® 2018;91:e2104-e2105. doi:10.1212/WNL.0000000000006563

Correspondence

Dr. Lawal
omolara.lawal@yale.edu

Figure Brain MRI, axial fluid-attenuated inversion recovery

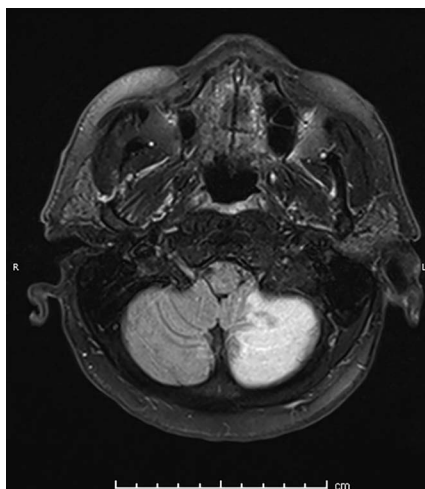


Image shows the patient's infarct, involving the caudal portion of the left cerebellar hemisphere. Area of involvement corresponds to posterior inferior cerebellar artery territory.

A 61-year-old man with previous left cerebellar infarct complained of double vision and dizziness several months postinfarct. Infarct is shown in the figure. Examination showed rotatory nystagmus in all directions of gaze, worse on left gaze (video 1). Oral examination showed palatal tremor (video 2). Oculopalatal tremor (OPT) is thought to result from interruption of connections between the red nucleus (midbrain), dentate nucleus (cerebellum), and inferior olive (medulla).^{1,2} The most common cause is brainstem infarction or hemorrhage,¹ but it has also been observed with multiple sclerosis and other inflammatory entities. OPT usually becomes apparent several months after the injury. Treatment may include gabapentin, memantine, benzodiazepines, and valproic acid.

Author contributions

O. Lawal: study concept and design, acquisition of data, preparation and revision of manuscript. A. Fisayo: clinical care of patient, acquisition of data, revision of manuscript for intellectual content, study supervision.

Study funding

No targeted funding reported.

MORE ONLINE

Video

→Teaching slides

links.lww.com/WNL/A746

From the Departments of Neurology (O.L., A.F.) and Neurology (Neuro-ophthalmology) (A.F.), Yale School of Medicine, New Haven, CT.

Go to Neurology.org/N for full disclosures. Funding information and disclosures deemed relevant by the authors, if any, are provided at the end of the article.

Disclosure

The authors report no disclosures relevant to the manuscript.
Go to Neurology.org/N for full disclosures.

References

1. Tilikete C, Desestret V. Hypertrophic olivary degeneration and palatal or oculopalatal tremor. *Front Neurol* 2017;8:302.
2. Borruat FX. Oculopalatal tremor: current concepts and new observations, *Curr Opin Neurol* 2013;26:67–73.

Neurology®

Teaching Video NeuroImages: Oculopalatal myoclonus: A possible consequence of brainstem injury

Omolara Lawal and Adeniyi Fisayo
Neurology 2018;91:e2104-e2105
DOI 10.1212/WNL.0000000000006563

This information is current as of November 26, 2018

Updated Information & Services	including high resolution figures, can be found at: http://n.neurology.org/content/91/22/e2104.full
References	This article cites 2 articles, 0 of which you can access for free at: http://n.neurology.org/content/91/22/e2104.full#ref-list-1
Subspecialty Collections	This article, along with others on similar topics, appears in the following collection(s): All Cerebrovascular disease/Stroke http://n.neurology.org/cgi/collection/all_cerebrovascular_disease_stroke Diplopia (double vision) http://n.neurology.org/cgi/collection/diplopia_double_vision Nystagmus http://n.neurology.org/cgi/collection/nystagmus Tremor http://n.neurology.org/cgi/collection/tremor
Permissions & Licensing	Information about reproducing this article in parts (figures, tables) or in its entirety can be found online at: http://www.neurology.org/about/about_the_journal#permissions
Reprints	Information about ordering reprints can be found online: http://n.neurology.org/subscribers/advertise

Neurology® is the official journal of the American Academy of Neurology. Published continuously since 1951, it is now a weekly with 48 issues per year. Copyright © 2018 American Academy of Neurology. All rights reserved. Print ISSN: 0028-3878. Online ISSN: 1526-632X.

