



Clinical letter

Fixation-off sensitivity in mitochondrial encephalomyopathy, lactic acidosis, and stroke-like episodes (MELAS) syndrome

Sangwon Lee, Dan-A Oh, Eun-Kee Bae*

Department of Neurology, Inha University Hospital, Incheon, Republic of Korea

1. Introduction

Fixation-off sensitivity (FOS) is a rare phenomenon of electroencephalography (EEG) induced by elimination of central vision/fixation [1]. FOS is characterized by

posterior or generalized epileptiform discharges that consistently occur after closing of the eyes and last as long as the eyes are closed for more than 3 s [2,3]. It is differentiated from other “eye-condition” related visual sensitive phenomena, including eye closure sensitivity (just immediately triggered by eye closure lasting for 3 s or less) and scotosensitivity (elicited by complete darkness; irrespective of eye opening and closure) [2,3]. Although FOS has been reported in various epileptic conditions representatively including idiopathic childhood occipital epilepsies, it has never been reported in patients with mitochondrial encephalomyopathy, lactic acidosis, and stroke-like episodes (MELAS) syndrome so far. Herein we report a unique case of FOS with or without scotosensitivity presented with a new-onset seizure in genetically confirmed MELAS syndrome.

2. Case report

A 22-year old man visited our emergency department presenting with a new-onset seizure while he was sleeping at night. The seizure was assumed as a generalized tonic-clonic type and its duration was about 2 min according to the witness of his parents. His initial vital signs including blood pressure and body temperature were within normal range. He was alert at the time of arrival and showed no focal neurologic deficits. He had a few years of history of diabetes mellitus (DM) being treated with oral hypoglycemic agents. He had no other history of medical illness except DM. In his family history, his mother has also been treated with oral hypoglycemic agents due to DM since her first pregnancy. Other family members including his father and one little brother did not report any specific medical illnesses and a history of seizures or any neurologic symptoms. His initial laboratory data were clinically insignificant except elevated levels of lactic acid (10.40 mmol/L; normal range 0.50–1.50) and HbA1c (8.3%; normal range 4.0–6.0). His brain magnetic resonance imaging (MRI) and magnetic resonance angiography (MRA) were normal. EEG revealed

generalized spike-and-waves and polyspikes that consistently occur after closing of the eyes and last as long as the eyes are closed, which is suggestive of FOS (Fig. 1). Although he did not have any stroke-like episodes, we examined a mitochondrially encoded tRNA leucine 1 (MT-TL1) gene test from his peripheral blood in suspicion of MELAS syndrome because of young-age onset DM and his short stature (163 cm) in addition to a seizure. The m.3243 A > G mutation was confirmed through this test. Thereafter his mother with DM and one asymptomatic little brother wanted to check the same genetic tests, both of them were also confirmed to have m.3243 A > G mutation. He has been seizure-free with antiepileptic drugs (lamotrigine, levetiracetam) for more than 6 months after the first seizure.

3. Discussion

Although various abnormal EEG findings can be encountered in patients with MELAS syndrome, to our knowledge, FOS with or without scotosensitivity has not been reported so far. FOS was first documented in four children with occipital paroxysms (two had what is now known as Panayiotopoulos syndrome, one had idiopathic childhood occipital epilepsy of Gastaut and one had symptomatic occipital epilepsy) [1]. Since then it is most commonly encountered in patients with idiopathic childhood occipital epilepsies, but may also be observed in cases of symptomatic or cryptogenic focal and generalized epilepsies, as well as in asymptomatic non-epileptic individuals [2]. Although FOS is rarely seen in the adult population, it often represents the EEG expression of symptomatic epilepsies (cortical malformations, celiac disease, calcified vascular malformation, and stroke, etc.) [4]. Strictly speaking, we should have differentiated FOS with scotosensitivity by the elimination of central vision/fixation in the presence of light with the use of modified Ganzfeld stimulation or Frenzel lenses. Although we didn't have a chance to perform this test, pure scotosensitivity is extremely rare and specific characteristics of light sensitivity has also been rarely studied in detail in the previous relevant literatures [3]. Besides, his generalized spike-and-waves and polyspikes on EEG consistently occurred even during the photic stimulation, we think that this phenomenon is unlikely to be scotosensitivity. However we could not completely rule out the possibility of combined scotosensitivity, we

* Corresponding author at: Department of Neurology, Inha University Hospital, 27, Inhang-Ro, Jung-Gu, Incheon, Republic of Korea.
E-mail address: alchemist0210@gmail.com (E.-K. Bae).

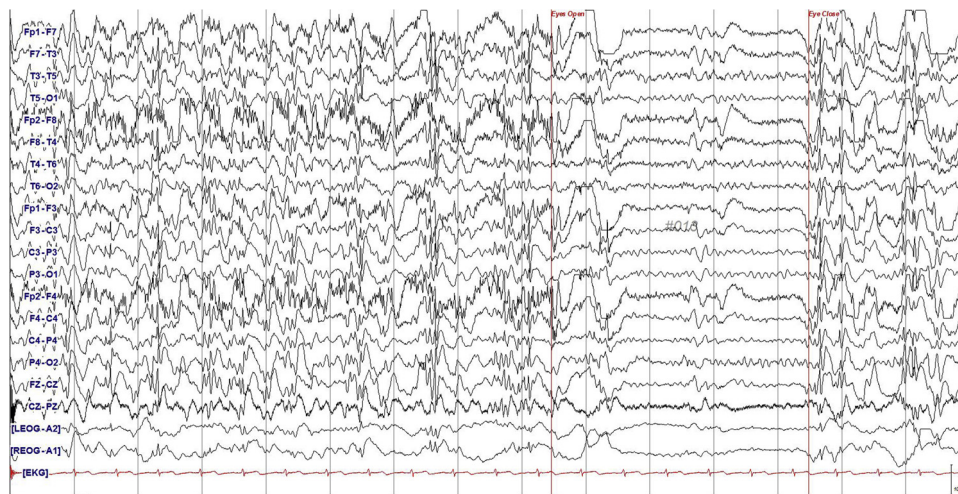


Fig. 1. Generalized epileptiform discharges that consistently occur after closing of the eyes and last as long as the eyes are closed.

used the term “FOS with or without scotosensitivity” here. Although the underlying mechanisms remain still uncertain due to its rarity, FOS is thought to be modulated by α -rhythm generators and influenced by cortical hyperexcitability [4]. In MELAS syndrome, epileptic seizures occur primarily in association with stroke-like episodes, however, they can happen in patient with normal brain MRI like our patient. The underlying epileptogenic pathophysiology is quite obscure in this situation. Our case suggests that the occipital hyperexcitability associated with FOS might have a pathophysiologic role in some patients with MELAS syndrome. In addition, we propose that MELAS syndrome should be considered as one of the rare but possible causes of adult-onset FOS.

Conflict of interest

None.

Acknowledgment

This work was supported by INHA UNIVERSITY Research Grant (INHA56992).

References

- [1] Panayiotopoulos CP. Inhibitory effect of central vision on occipital lobe seizures. *Neurology* 1981;31:1330–3.
- [2] Brigo F, Rossini F, Stefani A, Nardone R, Tezzon F, Fiaschi A, Manganotti P, Bongiovanni LG. Fixation-off sensitivity. *Clin Neurophysiol* 2013;124:221–7.
- [3] Karkare KD, Menon RN, Radhakrishnan A, Cherian A, Thomas SV. Electroclinical characteristics and syndromic associations of “eye-condition” related visual sensitive epilepsies-A cross-sectional study. *Seizure* 2018;58:62–71.
- [4] Fattouch J, Casciato S, Lapenta L, Morano A, Fanella M, Lombardi L, Manfredi M, Giallonardo AT, Di Bonaventura C. The spectrum of epileptic syndromes with fixation off sensitivity persisting in adult life. *Epilepsia* 2013;54(Suppl 7):59–65.