




Official Journal of the European Paediatric Neurology Society



Case study

Recurrent arterial ischemic stroke with good response to mycophenolate mofetil



Benedikte Van Driessche^{a,*}, Patrick Verloo^a, Nele Herregods^b,
Veerle Mondelaers^c, Joke Dehoorne^d, Rudy Van Coster^a, Helene Verhelst^a

^a Department of Paediatrics, Division of Paediatric Neurology, Ghent University Hospital, C. Heymanslaan 10, B-9000, Gent, Belgium

^b Department of Radiology, Division of Paediatric Radiology, Ghent University Hospital, C. Heymanslaan 10, B-9000, Gent, Belgium

^c Department of Paediatrics, Division of Paediatric Haemato-oncology and Stem Cell Transplantation, Ghent University Hospital, C. Heymanslaan 10, B-9000, Gent, Belgium

^d Department of Paediatrics, Division Paediatric Rheumatology, Ghent University Hospital, C. Heymanslaan 10, B-9000, Gent, Belgium

ARTICLE INFO

Article history:

Received 13 February 2018

Received in revised form

24 October 2018

Accepted 6 November 2018

Keywords:

Arterial ischemic stroke
Primary angitis of the central nervous system
Mycophenolate mofetil
Childhood

ABSTRACT

Background: Arterial ischemic stroke is rare in childhood. Often, the diagnosis is made after considerable delay. A thorough workup to pinpoint the underlying etiology is necessary, as a correct diagnosis is the determining factor in treatment decision. In case of primary angitis of the central nervous system, treatment with corticosteroids and immunosuppressive agents is indicated.

Case study: We described an eleven-year-old boy who presented at the age of six years with left hemiparesis and hemianopia. Cerebral imaging showed acute ischemia in the right posterior cerebral artery territory. Extensive workup was negative. In the following eight months, he had recurrent strokes on three separate occasions due to progressive arteriopathy involving multiple large- and medium-sized vessels. A presumed diagnosis of primary angitis of the central nervous system was made. Pulse intravenous methylprednisolone therapy was started followed by oral prednisolone. After the fourth stroke, a six-month treatment with cyclophosphamide was given which was followed by maintenance treatment with azathioprine. Shortly after cessation of corticosteroids and cyclophosphamide the subject relapsed. Cyclophosphamide was restarted in combination with corticosteroids and subsequently replaced by mycophenolate mofetil. Under mycophenolate mofetil maintenance treatment combined with low-dose corticosteroids, the patient achieved disease control with a relapse-free period of more than four years.

Conclusion: A guideline for current treatment of relapsing central nervous system angitis in childhood is missing in the literature. We describe a subject with multiple relapses despite

* Corresponding author. Department of Paediatrics, Division of Paediatric Neurology, Ghent University Hospital, C. Heymanslaan 10, B-9000, Gent, Belgium.

E-mail addresses: Benedikte.VanDriessche@ugent.be (B. Van Driessche), Patrick.Verloo@ugent.be (P. Verloo), Nele.Herregods@ugent.be (N. Herregods), Veerle.Mondelaers@ugent.be (V. Mondelaers), Joke.Dehoorne@ugent.be (J. Dehoorne), Rudy.VanCoster@ugent.be (R. Van Coster), Helene.Verhelst@ugent.be (H. Verhelst).

<https://doi.org/10.1016/j.ejpn.2018.11.003>

1090-3798/© 2018 European Paediatric Neurology Society. Published by Elsevier Ltd. All rights reserved.

treatment with corticosteroids and immunosuppressive agents, and stabilization of his clinical condition and of the radiological signs under mycophenolate mofetil treatment.

© 2018 European Paediatric Neurology Society. Published by Elsevier Ltd. All rights reserved.

Abbreviations

PACNS	primary angiitis of the central nervous system
CT	computed tomography
PCA	posterior cerebral artery
MRA	magnetic resonance angiography
ANF	antinuclear factor
ANCA	anti-neutrophil cytoplasmic antibodies
CSF	cerebral spinal fluid
ASA	acetylsalicylic acid
MRI	magnetic resonance imaging
ACA	anterior cerebral artery
MCA	medial cerebral artery
IV	intravenous
MMF	mycophenolate mofetil
FLAIR	fluid attenuated inversion recovery
DWI	diffusion weighted imaging
TOF	Time-of-flight
MIP	maximum intensity projection
CNS	central nervous system
cPACNS	childhood primary angiitis of the central nervous system
MPA	mycophenolic acid
NO	nitric oxide
PCR	polymerase chain reaction
HSV	Herpes Simplex virus
VZV	Varicella Zoster virus

1. Introduction

Arterial ischemic stroke is rare in childhood. A thorough workup is necessary to identify the underlying etiology. The main causal factors are cardiac disorders, sickle cell disease, thrombophilia and arteriopathy including genetic vasculopathy, moyamoya, arterial dissection, transient cerebral arteriopathy and vasculitis. Furthermore, mitochondrial disorders causing stroke or stroke-like episodes have to be excluded. The risk of recurrence is increased in the subjects with one of these causal factors.^{1–3} Primary angiitis of the central nervous system (PACNS) is among the differential diagnosis and necessitates a treatment with corticosteroids and immunosuppressive agents. In case of a thromboembolism, on the other hand, thrombolysis or endovascular therapy has to be considered and secondary prophylaxis is indicated.

2. Case study

The proband presented at the age of six years with pain and weakness of the left arm and leg and hyperesthesia at the left side of the face. Neurological examination revealed left hemiparesis and hemianopia. Cerebral computed tomography (CT) showed a hypodense area in the right posterior cerebral artery (PCA) territory. Magnetic resonance angiography (MRA) confirmed ischemic lesions involving the right medio-occipital cortex, hippocampus and thalamus with diffuse stenosis of the right PCA (See Fig. 1). Electroencephalogram, echocardiography, fundoscopy, infectious, prothrombotic and metabolic investigations were normal. Autoimmune screening revealed mildly elevated ANF and atypical ANCA. Cerebral spinal fluid (CSF) analysis showed oligoclonal banding (see Table 1). Genetic investigation demonstrated a homozygous MTHFR 677C > T mutation, without increase of homocystein blood concentration. For an overview of all the investigations concerning the thrombophilia screening see Table 2. Acetylsalicylic acid (ASA) was started. The patient clinically improved, but continued to suffer from equilibrium disturbance and left hemianopia.

One month later, he was readmitted because of acute onset left hemiparesis and headache. He was still treated with ASA and had received tranexamic acid for dental surgery the day before admission. Cerebral magnetic resonance imaging (MRI) revealed an area of acute ischemia in the right anterior cerebral artery (ACA), medial cerebral artery (MCA) and both PCA territories. MRA demonstrated occlusion of the right MCA, the right ACA and both PCAs (See Fig. 1). Cervical and abdominal duplex ultrasound was normal. The propositus was treated with intravenous (IV) methylprednisolone pulses. ASA was replaced by clopidogrel. CSF analysis performed six weeks after the second stroke was normal, oligoclonal bands were not detected (see Table 1).

Two months after the second stroke, the subject developed an acute onset episode with nystagmus, strabismus and partial visual loss. Cerebral MRI demonstrated two new focal ischemic lesions and MRA revealed a new occlusion of the posterior communicating artery. Cerebral angiography confirmed the pre-existing occlusion and stenosis of both PCAs, right MCA and ACA (See Fig. 1). The differential diagnosis was between a genetic vasculopathy, mitochondrial disease and vasculitis. Considering the serious condition of recurrent brain infarctions, a biopsy of brain parenchyma was taken, and a biopsy of skin and skeletal muscle. Brain biopsy demonstrated cortical necrosis and ischemia of the white matter, but no signs of vasculitis. Microscopic examination of the skin and muscle biopsy specimen did not reveal any abnormality. Mitochondrial enzyme activities were normal. A five day pulse of methylprednisolone (30 mg/kg/day) was given followed by oral prednisolone. Under prednisolone

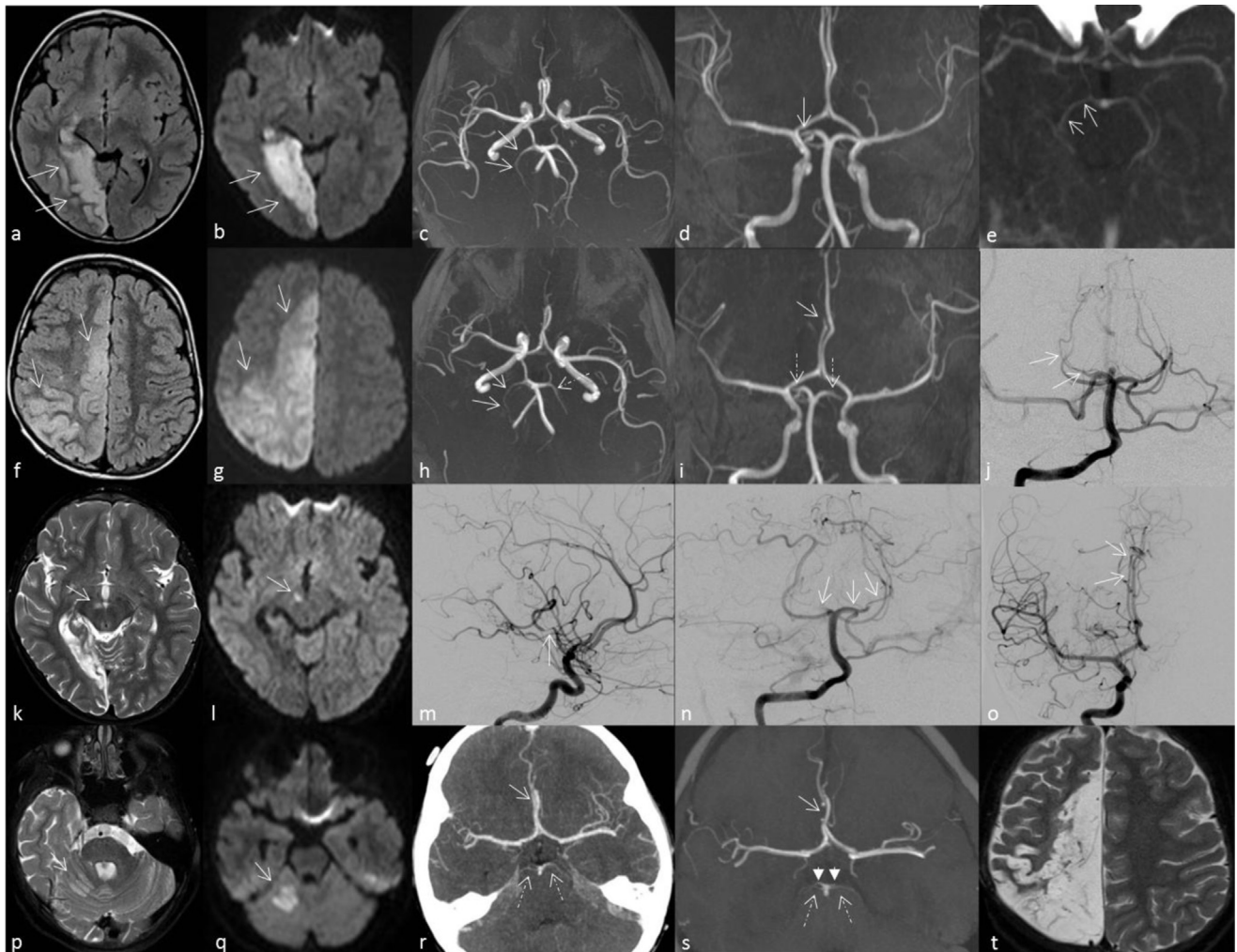


Fig. 1 – Overview of images after the consecutive strokes: a-e: episode 1: a-b. MRI: axial fluid attenuated inversion recovery (FLAIR) and axial diffusion weighted imaging (DWI) (arrows: infarction in right PCA territory), c-d. axial and coronal reconstruction of MRA time-of-flight (TOF) (arrows: narrowing of right PCA), e. maximum intensity projection (MIP)-image of CT angiography (arrows: narrowed right PCA as compared to left PCA) f-j: episode 2: f-g. MRI: axial FLAIR and DWI (arrows: extensive ischemic area in right ACA territory), h-i. axial (arrows: very thin aspect of right PCA, dotted arrow: narrow aspect of left PCA) and coronal (arrow: ‘stop’ image of right ACA, dotted arrows: thin aspect of both PCAs) reconstruction of MRA TOF, j. cerebral angiography (arrows: very thin aspect of right PCA) k-o: episode 3: k-l. MRI: axial T2 and DWI (arrows: ischemic area involving right cerebral peduncle), m-o. cerebral angiography (m. arrow: stenosis of posteroparietal branch of MCA, n. arrows: ‘stop’ image of right PCA and very thin aspect of left PCA, o. arrows: narrowed right ACA with ‘stop’ image and collateralization) p-t: episode 5: p-q. MRI: axial T2 and DWI (arrows: ischemic lesion in the superior cerebellar artery territory), r. MIP-image of CT angiography (arrow: thin aspect of right ACA, dotted arrows: thin aspect of both PCAs), s. semiaxial reconstruction of MRA TOF (arrow: thin aspect of right ACA, dotted arrows: thin aspect of both superior cerebellar arteries, arrowheads: ‘stop’ images of both PCAs), t. MRI T2 (end stage image with extensive encephalomalacia in the right ACA territory).

treatment, progressive stenosis of both PCAs was visualized on serial MRI. Steroids were stopped. Additional genetic investigations by Sanger sequencing revealed that the subject was heterozygous for variants of unknown significance in the *ABCC6*, *ENPP1* and *COL4A1* gene. The father was heterozygous for the *ABCC6*, *ENPP1* and the previously described *MTHFR* variant, the mother for the *COL4A1* variant. Both parents were healthy without any history of vasculopathy.

Three months later, the patient presented with a sudden collapse followed by impaired awareness. MRI showed an ischemic lesion in the left thalamus, MRA revealed a

persistent “stop” image of both PCAs and narrow aspect of the left superior cerebellar artery. Corticosteroids were recommenced (initial methylprednisolone pulses followed by oral prednisolone). Additionally, a treatment with monthly IV cyclophosphamide pulses (750 mg/m^2) was started. Clinical improvement was observed. After six months he was switched to maintenance treatment with azathioprine.

The patient remained stable during six months. One month after cessation of steroids and six weeks after switching from cyclophosphamide to azathioprine he

Table 1 – Overview of CSF sample results.

CSF samples	Leukocytes (0–5/ μ l)	Erythrocytes (0/ μ l)	Glucose (49–80 mg/dl)	Protein (15–50 mg/dl)	PCR	Oligoclonal banding
Sample 1 (first stroke)	<5	1018	67	23	HSV, VZV, Enterovirus negative	present
Sample 2 (6 weeks after second stroke)	<5	<5	64	16		absent
Sample 3 (2 weeks after third stroke)	35	16472	59	40		absent
Sample 4 (fourth stroke)	<5	<5	54	16	Respiratory viruses negative Mycoplasma pneumoniae negative	absent

CSF: cerebrospinal fluid, PCR: polymerase chain reaction, HSV: Herpes Simplex virus, VZV: Varicella Zoster virus.

relapsed. Cerebral MRI showed a new ischemic lesion in the right superior cerebellar artery territory (See Fig. 1). High-dose corticosteroids and monthly cyclophosphamide pulses were restarted, resulting in recovery of symptoms. After one month, a maintenance treatment with mycophenolate mofetil (MMF, 600 mg/m²) was associated while cyclophosphamide was stopped after three courses. Steroids were tapered over ten months to low dose (5 mg/day). Under treatment with MMF and corticosteroids, clinical and radiological stabilization was achieved. MRA was repeated every three to nine months which revealed unaltered bilateral diffuse ischemic lesions predominantly in the right hemisphere and unaltered stenosis of the affected vessels. The patient is followed up now for more than four years after the last stroke. He has a residual spastic left hemiparesis, paresis of the right arm and left hemianopia. Currently, he remains on treatment with MMF, clopidogrel and low dose prednisolone.

3. Discussion

We report on a subject with arterial ischemic stroke complicated by multiple relapses involving several large- and medium-sized vessels. After a thorough diagnostic workup, a presumed diagnosis of primary angiitis of the central nervous system (PACNS) was made. PACNS is an inflammatory brain disorder causing severe neurological deficits in previously healthy patients by inflammation of cerebral vessels without systemic involvement.^{4,5} The diagnostic criteria of Calabrese and Mallek includes an acquired unexplained neurological deficit, classic angiographic or histopathological features of CNS vasculitis and no evidence of systemic vasculitis.^{4–6} Childhood PACNS (cPACNS) is defined as PACNS in the subjects >1 month and \leq 18 years old.⁵ The absence of vasculitis signs outside the brain implies a considerable restriction in diagnostic opportunities. The limited sensitivity and specificity of the available diagnostic examinations adds to the diagnostic complexity.

In the subject presented here, blood analyses showed no arguments for systemic autoimmune, infectious or metabolic disorders. The first lumbar puncture revealed oligoclonal bands; however, subsequent CSF testing was normal (see Table 1). The presence of oligoclonal bands in the first sample, which was performed during the acute phase, is probably secondary to acquired cerebral damage. The absence of oligoclonal bands in repeat samples argues against an inflammatory process. Genetic analysis showed a homozygous MTHFR 677C > T mutation. The homozygous MTHFR 677 TT genotype is known to be associated with mild hyperhomocysteinemia and is a weak risk factor for thromboembolic disease but is not considered as a cause of stroke.⁷ Moreover, in the presented case, an increase of the homocystein concentration was not detected. Genetic workup showed in addition three variants of unknown significance, which were also found in the healthy parents and are considered as non relevant. MRA confirmed occlusion and stenosis of several large- and medium-sized vessels, without signs of vasculitis. Ultimate confirmation of vasculitis in the context of PACNS necessitates cerebral angiography, and when inconclusive, brain biopsy. However, the specificity of brain biopsy is low, with a false-negative ratio of up to 25%.⁵ In the presented case, we could not confirm the diagnostic criteria⁶ since cerebral angiography and brain biopsy did not show signs of vasculitis. The absence of vasculitis on brain biopsy could be due to previous steroid therapy or sampling error. In order to avoid additional brain injury the biopsy was performed in a stroke area. Despite these negative findings, we hypothesized that the proband had cPACNS based on the clinical evolution and radiological features. Positive arguments in favor of cPACNS were the development of significant arterial stenosis in a time span of several weeks, involvement of different vascular territories, clinical improvement after start of corticosteroids, and relapse tendency after discontinuation of immunosuppressive agents. Even though the diagnostic criteria of cPACNS could not be fully met, it can be crucial to continue to consider this diagnosis, as early initiation of treatment may reverse the neurological deficits and prevent recurrence.

Table 2 – Overview of investigations of thrombophilia.

Parameter	Patient value	Reference values
Laboratory tests		
Prothrombin time (PT)	93%	70–120%
Activated partial thromboplastin time (aPTT)	35.8s	28.9–38.1s
International Normalized Ratio (INR)	1.0	0.9–1.1
Fibrinogen	277 mg/dl	200–400 mg/dl
Antitrombine	140%	64–120%
Protein C activity	139%	59–168%
Protein S antigen	101%	70–148%
Activated protein C resistance (APCR)	2.33	>2.0
Lupus anticoagulant	absent	absent
Factor VIII	85%	60–150%
Factor IX	126%	60–150%
Factor XI	115%	60–140%
Factor XII	195%	50–200%
Factor XIII	85%	55–175%
Plasminogen	145%	80–120%
Von Willebrand Factor antigen	49.6%	48–157%
Von Willebrand Factor Ristocetin Cofactor (vWF:RCo)	45.8%	44–162%
FII G20210A mutation	homozygous normal	
MTHFR 677C > T mutation	homozygous	
Homocystein	4.6 μmol/L	3.3–8.3 μmol/L
Immunophenotyping of granulocytes and monocytes: FLAER expression	homogeneous FLAER expression. No arguments for paroxysmal nocturnal hemoglobinuria (PNH)	
Antiphospholipid antibodies	negative	negative
Echocardiography Duplex ultrasonography	normal normal aspect of abdominal and cervical vessels	

The choice of treatment of cPACNS is based mainly on clinical experience and observational data due to lack of randomized controlled trials. In case of progressive cPACNS, induction therapy with high-dose corticosteroids and cyclophosphamide followed by maintenance therapy with an immunosuppressant agent is recommended.⁵ In the presented subject, a treatment with corticosteroids and monthly cyclophosphamide pulses was given followed by azathioprine. The patient relapsed shortly after cessation of corticosteroids and cyclophosphamide. After introduction of MMF maintenance therapy the clinical and radiological status of the proband stabilized and a relapse-free period of more than four years was seen. However it remains difficult to prove that the stabilization of the subject is due to MMF treatment and not to the natural evolution of the underlying process.

MMF is a prodrug of mycophenolic acid (MPA). MPA inhibits inosine-5'-monophosphate dehydrogenase, an enzyme in guanosine nucleotides synthesis. Depletion of guanosine nucleotide inhibits the proliferation of lymphocytes and antibody formation. Furthermore, MPA induces apoptosis of activated T-lymphocytes, suppresses the recruitment of lymphocytes and monocytes into inflammatory sites and decreases the production of NO and subsequent tissue damage.^{8,9}

The evidence of efficacy of MMF as immunosuppressive agent in cPACNS is limited. Rosati et al. reported four cases of progressive cPACNS successfully treated with MMF.¹⁰ Sen et al. described three children with cPACNS who achieved disease control with MMF after failure of first-line immunosuppressive agents.¹¹ Hutchinson et al. reported a higher incidence of side effects and relapses in small vessel cPACNS under maintenance therapy with azathioprine as compared to MMF.¹²

In conclusion, cPACNS remains a difficult diagnosis and a therapeutic challenge. Early recognition is essential as timely initiation of treatment may reverse neurological deficits and prevent permanent brain damage. Unfortunately, efficient non-invasive diagnostic modalities and evidence-based treatment protocols in relapsing disease are missing. The proband demonstrated a good clinical and radiological response under MMF treatment (See Fig. 1).

Funding

This research did not receive any specific grant from funding agencies in the public, commercial, or not-for-profit sectors.

Declarations of interest

None.

REFERENCES

- Fullerton HJ, Wintermark M, Hills NK, et al. Risk of recurrent arterial ischemic stroke in childhood: a prospective international study. *Stroke* 2016;**47**(1):53–9. <https://doi.org/10.1161/STROKEAHA.115.011173>.
- Greenham M, Gordon A, Anderson V, MacKay MT. Outcome in childhood stroke. *Stroke* 2016;**47**(4):1159–64. <https://doi.org/10.1161/STROKEAHA.115.011622>.
- Kirkham F. Stroke in childhood. *Arch Dis Child* 1999;**81**(1):85–9. <http://adc.bmj.com/content/81/1/85.full>.
- Gowdie P, Twilt M, Benseler SM. Primary and secondary central nervous system vasculitis. *J Child Neurol* 2012;**27**(11):1448–59. <https://doi.org/10.1177/0883073812459352>.
- Hajj-Ali RA, Singhal AB, Benseler S, Molloy E, Calabrese LH. Primary angiitis of the CNS. *Lancet Neurol* 2011;**10**(6):561–72. [https://doi.org/10.1016/S1474-4422\(11\)70081-3](https://doi.org/10.1016/S1474-4422(11)70081-3).
- Calabrese LH, Mallek JA. Primary angiitis of the central nervous system. Report of 8 new cases, review of the literature, and proposal for diagnostic criteria. *Medicine (Baltimore)* 1988;**67**:20–39.

7. Alsayouf H, Zamel KM, Heyer GL, Khuhro AL, Kahwash SB, de los Reyes EC. Role of methylenetetrahydrofolate reductase gene (MTHFR) 677C>T polymorphism in pediatric cerebrovascular disorders. *J Child Neurol* 2011;**26**(3):318–21. <https://doi.org/10.1177/0883073810381446>.
8. Allison AC, Eugui EM. Mycophenolate mofetil and its mechanisms of action. *Immunopharmacology* 2000;**47**:85–118. [https://doi.org/10.1016/S0162-3109\(00\)00188-0](https://doi.org/10.1016/S0162-3109(00)00188-0).
9. Allison A. Mechanisms of action of mycophenolate mofetil. *Lupus* 2005;**14**(3_suppl):2–8. <https://doi.org/10.1191/0961203305LU2109OA>.
10. Rosati A, Cosi A, Basile M, et al. Mycophenolate mofetil as induction and long-term maintaining treatment in childhood: primary angiitis of the central nervous system. *Jt Bone Spine* 2017;**84**(3):353–6. <https://doi.org/10.1016/j.jbspin.2016.12.004>.
11. Sen ES, Leone V, Abinun M, et al. Treatment of primary angiitis of the central nervous system in childhood with mycophenolate mofetil. *Rheumatology* 2010;**49**(4):806–11. <https://doi.org/10.1093/rheumatology/kep453>.
12. Hutchinson C, Elbers J, Halliday W, et al. Treatment of small vessel primary CNS vasculitis in children: an open-label cohort study. *Lancet Neurol* 2010;**9**(11):1078–84. [https://doi.org/10.1016/S1474-4422\(10\)70243-X](https://doi.org/10.1016/S1474-4422(10)70243-X).