

# Cortical surface intracranial electrodes identify clinically relevant seizures missed on scalp EEG after traumatic intracranial hemorrhage

Chris R. Marcellino<sup>1</sup>, Samuel Lapalme-Remis<sup>2</sup>,  
Alejandro A. Rabinstein<sup>2</sup>, Jamie J. Van Gompel<sup>1</sup>,  
Gregory A. Worrell<sup>2</sup>, Eric T. Payne<sup>2</sup>, Sara Hocker<sup>2</sup>

<sup>1</sup> Department of Neurologic Surgery

<sup>2</sup> Department of Neurology, Mayo Clinic, Rochester, Minnesota, USA

Received June 20, 2018; Accepted September 04, 2018

**ABSTRACT** – Seizures and other electrophysiological disturbances are an under-recognized cause of coma, focal deficits, and prolonged encephalopathy following subdural hematoma evacuation. In these patients, it is possible that seizures remain unrecognized on scalp EEG. It has been shown that a high burden of seizures and other electrophysiological disturbances exist following surgical evacuation and underlie the encephalopathy commonly seen in this patient population, predisposing them to medical complications and confounding estimates of prognosis. As part of a research protocol, we are performing intraoperative placement of cortical surface (non-parenchyma penetrating) intracranial EEG on patients who present after trauma and require emergent decompressive hemicraniectomy.

In this case report of a patient with high-velocity traumatic epidural, subdural, and subarachnoid hemorrhages, we identified frequent non-convulsive seizures or seizure-like SIRPIDs with intracranial cortical surface monitoring that were not identified on simultaneous scalp EEG. Stimulation consistently triggered these electrographic seizures in addition to rhythmic lateralized periodic discharges. His mental status improved rapidly after resolution of these electrographic seizures shortly after increasing anti-seizure medications, suggesting that they may have been contributing to his encephalopathy. More research is needed to determine the frequency of this phenomenon and determine whether treatment of such seizures improves patient outcomes.

**Key words:** traumatic brain injury, hematoma, subdural, trauma, intracranial EEG

**Correspondence:**

Chris Marcellino  
Mayo Clinic,  
Department of Neurologic Surgery,  
200 First Street SW,  
Rochester, Minnesota 55905, USA  
<marcellino.christopher@mayo.edu>

All intracranial hemorrhages may provoke seizures (Young *et al.*, 1996; Annegers *et al.*, 1998; Claassen *et al.*, 2003, 2007; Rudzinski *et al.*, 2011). The factors which lead to acute seizures or chronic epilepsy are an active field of study (Joseph *et al.*, 2016; Pollandt *et al.*, 2017). Traumatic brain injury (TBI) severity and spontaneous hemorrhage expansion have been shown to correlate with the risk of both acute seizures and epilepsy (Annegers *et al.*, 1998; Claassen *et al.*, 2003, 2007; Frey, 2003; Temkin, 2003; Rabinstein *et al.*, 2010; Rudzinski *et al.*, 2011). Subdural hematoma (SDH) and epidural hematoma are common causes of death and disability, and delayed complications often present a major challenge. Epileptic complications are common after acute SDH evacuation, with seizures or epileptiform changes occurring in 25% of patients. Published data suggest that this is frequently overlooked in the care of these patients (Rabinstein *et al.*, 2010). Seizures and epileptiform changes following SDH evacuation have a strong association with lower Glasgow Coma Scale scores after surgery and are more common after hematoma evacuation by craniotomy (Rabinstein *et al.*, 2010).

A growing and rapidly evolving body of evidence suggests that a significant proportion of encephalopathy seen in patients after intracerebral and subarachnoid hemorrhages are due to clinically undetected ictal activity (Claassen *et al.*, 2003, 2007, 2013a; Fabricius *et al.*, 2008; Mikell *et al.*, 2016). This has led to recommendations to consider EEG monitoring in comatose intracranial hemorrhage patients (Brophy *et al.*, 2012; Claassen *et al.*, 2013b). Yet such patients are not universally monitored with EEG in the absence of convulsive seizures, and even when monitored, it appears that a proportion of seizures go undetected on scalp EEG. Waziri *et al.* demonstrated this using bedside placement post-TBI of transcortical EEG (depth) electrodes, in which eight of 14 patients had electrographic seizures not seen on scalp EEG (Waziri *et al.*, 2009). Discrepancies between scalp and intracranial EEG (IEEG) are well known (Tao *et al.*, 2005; Brophy *et al.*, 2012) in patients undergoing epilepsy surgery evaluation with implanted electrodes. Comatose or otherwise encephalopathic patients after evacuation of SDH often have abnormal scalp EEG but no detected seizures despite prolonged monitoring (Rudzinski *et al.*, 2011).

We report the case of a comatose patient who underwent evacuation and decompressive hemicraniectomy for a traumatic epidural and subdural hematoma, whose IEEG showed frequent non-convulsive seizures that were not detected on concurrent scalp EEG. The patient had improvement in his state of consciousness after treatment with antiseizure medications aborted the seizures.

## Methods

This is a case report of a single patient that is part of an ongoing research project. To test our hypothesis that seizures and other electrophysiological disturbances are an under-recognized contributor to coma, focal deficits, and prolonged encephalopathy following SDH evacuation, we are performing an exploratory study to obtain IEEG on patients requiring emergent decompressive post-traumatic hemicraniectomy. The goal of this research is to detect and characterize these electrophysiological disturbances. The study protocol was approved by the Mayo Clinic Institutional Review Board.

Informed consent was obtained from the next of kin simultaneously with the initial portions of the emergency surgery. After the hemicraniectomy is drilled and the dura mater is opened widely in the standard fashion, a 1-lead 4-contact cylindrical electrode with platinum contacts (Ad-Tech Medical, Racine, Wisconsin, USA) is laid over each of the ipsilateral frontal cortex and motor strip, based on the anatomical estimation of the surgeon (*supplementary figure 1*). Practical concerns limit the number of cortical regions that can be monitored in this protocol, and the frontal and motor regions are generally visualized in craniotomies performed for trauma and are of high clinical yield. Regions of resected, cauterized, severely contused or friable brain are generally avoided (analogously to subdural surgical drain placement), but otherwise there is no specific targeting of injured anatomy. They are tunneled through the skin in a pre-sterilized area adjacent to the incision. As the dura is left open in decompressive hemicraniectomy to control intracranial pressure, the practice at our institution is to lay a single layer of thin oxidized regenerated cellulose sheets (Surgicel Original Absorbable Hemostat; Ethicon Inc., Somerville, New Jersey, USA) over the exposed cortex to improve hemostasis and provide an additional barrier between scalp and brain to facilitate cranioplasty. The IEEG leads are placed under this layer, which helps secure them in place during closure. A tin disk reference is placed on the scalp at the CP<sub>z</sub> position and EEG data is acquired in reference through an XLTEK EMU40X amplifier and displayed electronically using Natus NeuroWorks Software (Natus Medical Incorporated, Pleasanton, California, USA). EEG recordings from the scalp and electrodes are obtained simultaneously. Following wound closure, the patient is transferred to the neurosciences ICU. A post-operative non-contrast computed tomography (CT) scan of the head is obtained, after which scalp macroelectrodes are placed in conventional fashion to provide correlation with the cortical EEG and to aid treatment of any

macroscopic seizures. The imaging data is collected to confirm the cortical location of the IEEG leads. Both the IEEG and external EEG leads are maintained for a maximum of five days or until the patient is conscious, without focal neurological deficits, and not overtly encephalopathic, at which point the leads are removed percutaneously without requiring further surgery.

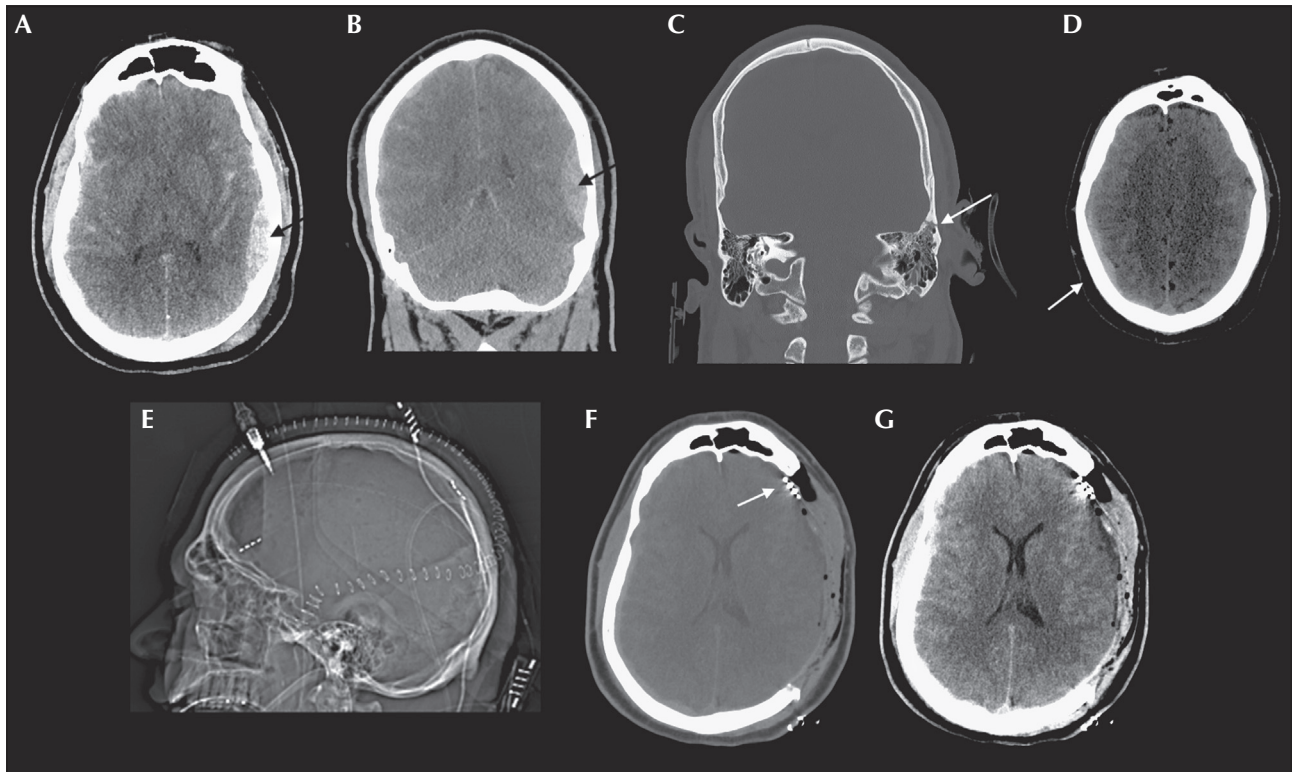
## Case study

A 32-year-old man with no neurologic history fell off a moving vehicle at high speed and struck his head on the pavement, and ultimately required surgical evacuation and decompression due to large epidural and subdural hematomas (*figure 1 A-D*). He underwent emergent surgical evacuation with IEEG lead placement under the study protocol. A post-operative CT showed a decreased mass effect and adequate placement

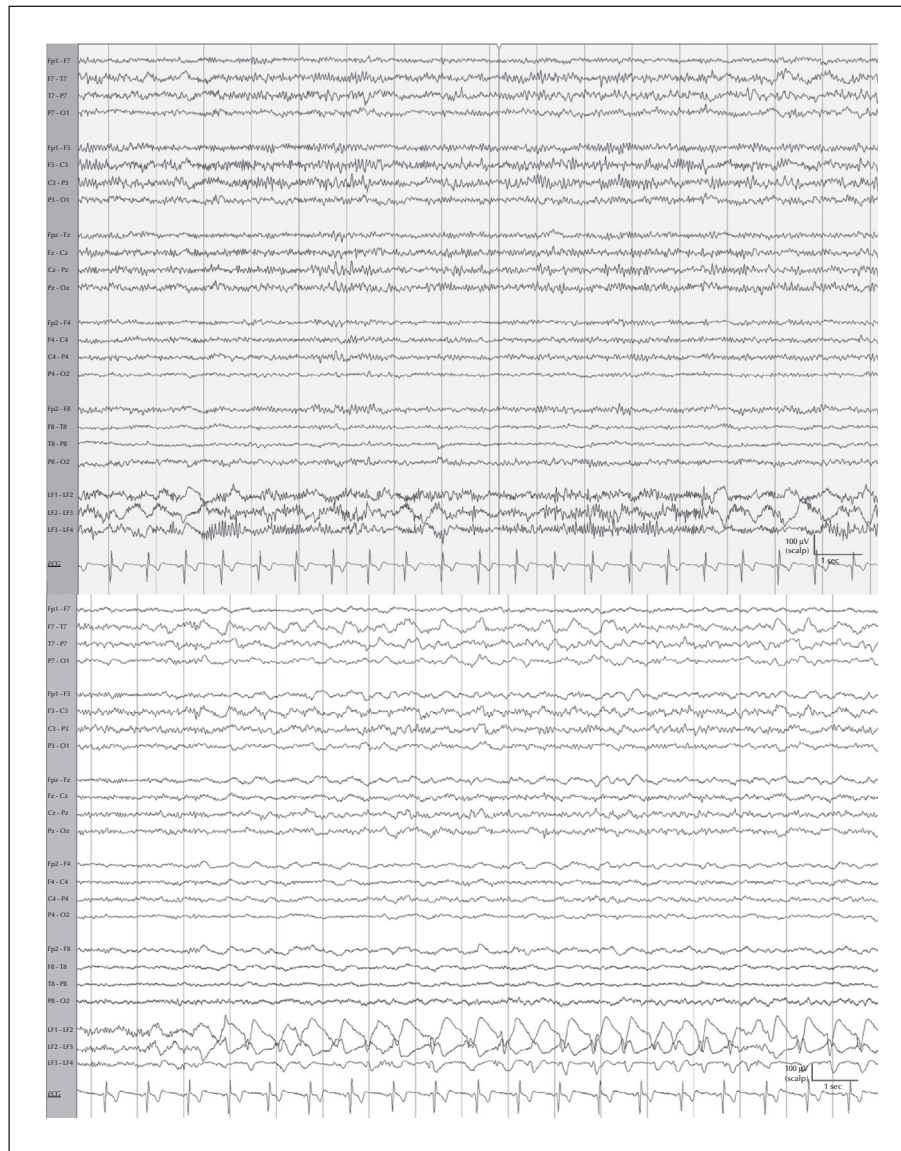
of the cortical electrodes over the frontal and parietal lobes (*figure 1E-G*).

Scalp and intracranial EEG were recorded for 94 hours starting shortly after completion of surgery. Scalp EEG initially demonstrated severe diffuse slowing (1-4 Hz) with overlying fast activity (12-20 Hz), consistent with an anesthetic effect, and a left hemispheric breach rhythm. After discontinuation of propofol on the third post-operative day, left hemispheric focal slowing persisted (*figure 2*).

From the onset of IEEG recording, the frontal electrode recorded successfully. The parietal electrode did not record (likely due to mechanical damage to its delicate leads) and its channels were hidden in the review montage. The frontal subdural electrode showed intermittent, waxing and waning, sharply-contoured rhythmic delta activity, as well as periodic sharp waves, consistent with lateralized periodic discharges.



**Figure 1.** Pre- and post-operative CT imaging. Pre-operative CT head non-contrast (A) axial and (B) coronal slices showing left temporal epidural hematoma (arrows) with maximal radial diameter of 16 mm, (C) the overlying oblique non-displaced fracture of the left temporal bone (arrow), which extends through the squamous portion into the petrous portion (not shown), and (D) contralateral right convexity contracoup SDH (arrow). There was also a small amount of air tracking into the Eustachian tube and surrounding the fracture, but no disruption of the petrous carotid was visible on angiography (also not shown.) This resulted in mild effacement of the ambient cisterns and right greater than left lateral ventricles without significant midline shift. Note that this epidural hematoma crosses the suture lines and may be confused with an SDH, but this is due to the dura's skull insertion disruption by the fracture. The largest lesion was directly visualized above the dura intraoperatively, although smaller subdural fluid collections and intraparenchymal contusions were visible after opening dura. Immediately post-operative head CT non-contrast, after left hemicraniectomy and cortical electrode placement in the frontal lobe and estimated location of the motor cortex (arrows) (E) scout reconstruction, shows placement of cortical electrodes over the left frontal and parietal lobes, and (F) axial slice shows post-operative localization of the frontal lobe EEG lead (arrow: motor cortex lead not shown in this slice) and (G) the same slice windowed for soft tissue to show substantial improvement in mass effect after evacuation.



**Figure 2.** Scalp and frontal cortical IEEG and seizure. Upper panel: longitudinal bipolar montage scalp EEG showing diffuse slowing with overlying fast activity (12-20 Hz). Intermittent focal delta slowing and a breach rhythm are seen over the left hemisphere, maximal in the centrotemporal region. The bottom three bipolar channels display concurrent cortical IEEG derived from the frontal electrodes, as indicated by leads LF1-LF4. These demonstrate intermittent rhythmic delta activity that is at times sharply contoured. The non-recording parietal electrode channels are not shown. Lower panel: sharply contoured activity seen on cortical EEG has become rhythmic, following an initial evolution. There is spread to the LF3-LF4 channel, where a clear spike and wave morphology is seen. Waxing and waning rhythmic focal slowing without clear evolution is intermittently seen on concurrent scalp EEG despite persistence of the IEEG seizure. (Filter settings: LFF: 1 Hz; HFF: 70 Hz; notch: 60 Hz; sensitivity: 10  $\mu$ V; timebase: 15 mm/sec.)

At times, the rhythmic delta activity evolved in frequency, location, and morphology, persisting for at least ten seconds, thus meeting the criteria for electrographic seizures used by Claassen *et al.* (2004) in their study of seizure detection by continuous EEG in critically ill patients. On scalp EEG, however, this ictal activity was not detected, although intermittent rhythmic or quasi-rhythmic delta slowing (1-2 Hz) without evolution was concurrently seen on occasion (figure 2). The rhythmic activity could also be triggered

consistently with stimulation (e.g. nursing care), suggesting stimulus-induced rhythmic, periodic, or ictal discharges (SIRPIDs) (Hirsch *et al.*, 2004). There were no convulsive seizures.

In response to the IEEG findings and given persistence of coma despite anesthesia wean, antiseizure treatment with levetiracetam was increased until the electrographic seizures identified on IEEG resolved at a daily total dose of 2,000 mg. The patient's level of consciousness improved shortly after the seizures were

controlled on the fourth post-operative day, suggesting that the electrographic seizures may have contributed to a worsened encephalopathy. During the night and morning prior to his improvement in consciousness, the rhythmic delta scalp correlate and IEEG lateralized periodic discharges became less frequent. The patient improved and was extubated on the fifth post-operative day. He was without a focal neurological deficit. Antiseizure medications were discontinued three months post-operatively without issue, over eight months of follow-up.

## Discussion

IEEG findings for seizures and SIRPIDs were identified following extra-axial hematoma evacuation for this patient using our method of cortical surface monitoring and were not identified on simultaneous scalp EEG. The patient was comatose while these findings were present and he regained alertness shortly after seizures were successfully treated, and although these were temporally related events, the correlation is uncertain. This case illustrates that, after evacuation of an extra-axial post-traumatic hematoma, clinically relevant focal subclinical seizure activity may be missed on scalp EEG or have subtle intermittent non-specific correlate not meeting criteria for seizures.

Our patient did not experience any adverse events related to the study. We chose electrodes that are widely used in elective epilepsy monitoring surgery as “depth” electrodes, and are FDA approved for IEEG monitoring. They allow for percutaneous removal in stereotactic EEG, but are used strictly over the cortex in our study (without penetrating the parenchyma) and were chosen for their ability to be removed percutaneously at the bedside without subjecting the patient to an additional operation. Despite the established safety of intraparenchymal placement seen in prior TBI IEEG studies (Waziri *et al.*, 2009) and elective epilepsy surgery, this protocol minimizes any potential risk of iatrogenic hemorrhage and trauma to the penumbra, watershed or eloquent cortical tissue most pertinent for monitoring to avoid further injury to the friable traumatically injured brain in our experimental study protocol.

Future research into the risk factors, diagnosis, and best treatment of subclinical seizures after traumatic brain injury is warranted. Continued development of consensus-based guidelines for monitoring and treatment in cases of reduced consciousness after TBI may be useful. It is unclear if routine placement of minimally invasive IEEG leads after surgery for TBI is warranted, and this may be a topic of future outcomes-based research. The development of more

effective percutaneously removable monitoring electrodes, perhaps integrated into surgical drains, or intracranial pressure or tissue oxygenation monitors, will increase their utility in this cohort, and continued research into IEEG in trauma patients may enhance our understanding of both epileptogenesis and non-convulsive seizures in this population. □

### Supplementary data.

Summary didactic slides and a supplementary figure are available on the [www.epilepticdisorders.com](http://www.epilepticdisorders.com) website.

### Acknowledgements and disclosures.

Funding was obtained for the study using institutional funding sources and does not pose any conflicts of interest relevant to this study.

None of the authors have any conflict of interest to declare.

## References

- Annegers JF, Hauser WA, Coan SP, Rocca WA. A population-based study of seizures after traumatic brain injuries. *N Engl J Med* 1998; 338: 20-4.
- Brophy GM, Bell R, Claassen J, *et al.* Guidelines for the evaluation and management of status epilepticus. *Neurocrit Care* 2012; 17: 3-23.
- Claassen J, Peery S, Kreiter KT, *et al.* Predictors and clinical impact of epilepsy after subarachnoid hemorrhage. *Neurology* 2003; 60: 208-14.
- Claassen J, Mayer S, Kowalski R, Emerson R, Hirsch L. Detection of electrographic seizures with continuous EEG monitoring in critically ill patients. *Neurology* 2004; 62: 1743-8.
- Claassen J, Jetté N, Chum F, *et al.* Electrographic seizures and periodic discharges after intracerebral hemorrhage. *Neurology* 2007; 69: 1356-65.
- Claassen J, Perotte A, Albers D, *et al.* Nonconvulsive seizures after subarachnoid hemorrhage: multimodal detection and outcomes. *Ann Neurol* 2013a; 74: 53-64.
- Claassen J, Taccone FS, Horn P, Holtkamp M, Stocchetti N, Oddo M. Recommendations on the use of EEG monitoring in critically ill patients: consensus statement from the neurointensive care section of the ESICM. *Intensive Care Med* 2013b; 39: 1337-51.
- Fabricius M, Fuhr S, Willumsen L, *et al.* Association of seizures with cortical spreading depression and peri-infarct depolarisations in the acutely injured human brain. *Clin Neurophysiol* 2008; 119: 1973-84.
- Frey LC. Epidemiology of posttraumatic epilepsy: a critical review. *Epilepsia* 2003; 44: 11-7.
- Hirsch LJ, Claassen J, Mayer SA, Emerson RG. Stimulus-induced rhythmic, periodic, or ictal discharges (SIRPIDs): a common EEG phenomenon in the critically ill. *Epilepsia* 2004; 45: 109-23.



Joseph JR, Smith BW, Williamson CA, Park P. Seizure correlates with prolonged hospital stay, increased costs, and increased mortality in nontraumatic subdural hematoma. *World Neurosurg* 2016; 92: 366-70.

Mikell CB, Dyster TG, Claassen J. Invasive seizure monitoring in the critically-ill brain injury patient: current practices and a review of the literature. *Seizure* 2016; 41: 201-5.

Pollandt S, Ouyang B, Bleck TP, Busl KM. Seizures and epileptiform discharges in patients with acute subdural hematoma. *J Clin Neurophysiol* 2017; 34: 55-60.

Rabinstein AA, Chung SY, Rudzinski LA, Lanzino G. Seizures after evacuation of subdural hematomas: incidence, risk factors, and functional impact. *J Neurosurg* 2010; 112: 455-60.

Rudzinski LA, Rabinstein AA, Chung SY, et al. Electroencephalographic findings in acute subdural hematoma. *J Clin Neurophysiol* 2011; 28: 633-41.

Tao JX, Ray A, Hawes-Ebersole S, Ebersole JS. Intracranial EEG substrates of scalp EEG interictal spikes. *Epilepsia* 2005; 46: 669-76.

Temkin NR. Risk factors for posttraumatic seizures in adults. *Epilepsia* 2003; 44: 18-20.

Waziri A, Claassen J, Stuart RM, et al. Intracortical electroencephalography in acute brain injury. *Ann Neurol* 2009; 66: 366-77.

Young BG, Jordan KG, Doig GS. An assessment of nonconvulsive seizures in the intensive care unit using continuous EEG monitoring: an investigation of variables associated with mortality. *Neurology* 1996; 47: 83-9.

## TEST YOURSELF



- (1) Can TBI (and other critically ill) patients have seizures that are not visible on conventional scalp EEG?
- (2) What are SIRPIDs?
- (3) What methods for invasive EEG monitoring exist?

*Note: Reading the manuscript provides an answer to all questions. Correct answers may be accessed on the website, [www.epilepticdisorders.com](http://www.epilepticdisorders.com), under the section "The EpiCentre".*