

## CASE REPORT

## Delayed presentation of neck arteries dissection, caused by water slide activity

Ayman Mahmoud Alboudi,<sup>1</sup> Pournamy Sarathchandran,<sup>1</sup> Samar Sameer Geblawi<sup>2</sup>

<sup>1</sup>Department of Neurology, Rashid Hospital, Dubai, United Arab Emirates  
<sup>2</sup>Pediatrics, Icare clinics, Dubai, Dubai, UAE

**Correspondence to**  
 Dr Ayman Mahmoud Alboudi,  
 alboudi.a@gmail.com

Accepted 20 August 2018

**SUMMARY**

A 16-year-old Korean boy presented with acute onset vertigo, dysphagia and gait ataxia of 16 hours duration. He had history of headache and neck pain along with transient vertigo during a water slide ride 12 days before presentation. CT brain showed left cerebellar and left lateral medullary infarcts. CT angiography showed left vertebral dissection with occlusion of left posterior inferior cerebellar artery. A 52-year-old Indian man, presented with acute onset global aphasia and right hemiparesis within 3 hours of onset of symptoms. He received intravenous tissue plasminogen activator (tPA) with partial improvement in his symptoms. He had headache and neck pain since 2 weeks, ever since he had a water slide ride. CT brain was normal, while the CT angiogram showed left carotid dissection. Cervical artery dissection has been reported with roller coaster rides and rarely with delayed presentations. Delayed presentation of cervical artery dissection after water rides have not been reported.

**BACKGROUND**

Cervical arteries dissection is a frequent cause of stroke in young. It is frequently classified as spontaneous dissection, since patients do not take minor trauma seriously. Trauma as minor as simple neck turns during water slide rides can produce cervical dissection.

Stroke can happen even after weeks of cervical trauma and dissection since complete occlusion of the artery or embolisation from the artery may take place after many days.

Complete history taking with enquiry to neck trauma will help for proper aetiological diagnosis of stroke in young and will aid proper management

**CASE PRESENTATION****Case 1**

A 16-year-old Korean boy presented with sudden onset vertigo, nausea and vomiting of 16 hours duration. He was unable to walk unaided and had severe dysphagia. He mentioned that he had been to a water park and had a water slide ride 12 days before the presentation, during which time he had transient vertigo lasting around 10 minutes.

His examination revealed left Horner's syndrome and left side gaze evoked nystagmus. Extraocular movements were normal and there was no facial asymmetry. Palatal movements were reduced on the left side with absent gag reflex on the left. Tongue movements were normal.

Motor power, reflexes and plantar response were normal in all four limbs. Sensation for pain was reduced on the left side of face and right side of body. He had left upper limb dysmetria and dysdiadocho kinesia. He was unable to stand or walk without support.

**Case 2**

A 52-year-old Indian man presented with aphasia and right-sided weakness. The patient fell down while he was trying to get out of his bed, and his wife found that he is not able to speak or comprehend and has right-sided weakness. He presented to emergency within 3 hours of onset of symptoms. He was not known to have hypertension or diabetes mellitus.

At presentation, his vital signs were stable. Neurological examination revealed left-sided Horner syndrome, global aphasia, partial right hemianopia, right-sided facial weakness (upper motor neuron type) and right-sided hemiparesis. Power in the upper limb was 3/5 while in the lower limb it was 4/5. He was with drawing limbs to painful stimuli. Cerebellar examination was limited due to poor comprehension. NIHSS at presentation was 17.

**INVESTIGATIONS**

Case 1: CT brain was done which is showed infarct involving left side of cerebellum and left lateral medulla (figure 1). CT angiography showed the non-visualisation of V4 part of left vertebral artery (figures 2 and 3).

Case 2: CT brain was done and was normal (figure 4). CT angiography was done and showed dissection of the left carotid artery (figures 5 and 6).

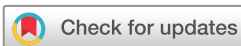Routine blood investigations including thyroid function tests, lipid profile and HbA1C were normal for both patients. ECG and 2D ECHO were normal in both cases. In addition, full thrombotic and vasculitic workup were done and did not reveal any abnormality (including protein C, protein S, antithrombin 3, activated protein C resistance, anti-DNA antibody, ANA, lupus anticoagulant, homocysteine, beta-2 glycoprotein, antineutrophil cytoplasmic antibodies p and c, anticardiolipin and anti-gliadin antibody).

**DIFFERENTIAL DIAGNOSIS**

Cardio embolic strokes, intracranial haemorrhage.

**TREATMENT**

Case 1 was not a candidate for thrombolysis since he presented outside the window period for



© BMJ Publishing Group Limited 2018. No commercial re-use. See rights and permissions. Published by BMJ.

**To cite:** Alboudi AM, Sarathchandran P, Geblawi SS. *BMJ Case Rep* 2018;**11**:e226333. doi:10.1136/bcr-2018-226333

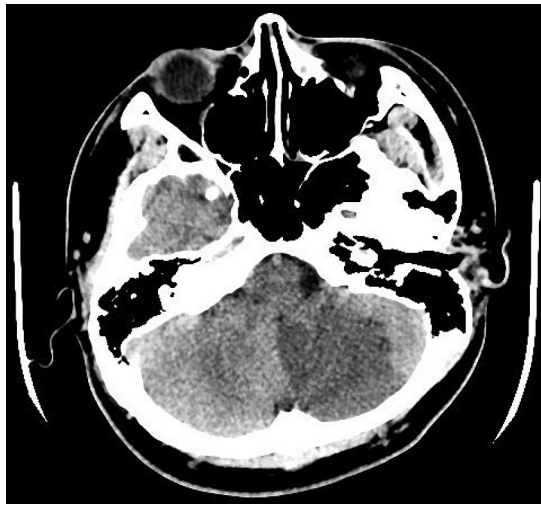


Figure 1 Plain CT brain, showing left cerebellar infarction.

thrombolysis. He was treated conservatively with antiplatelet and pantoprazole for gastric prophylaxis. He was started on nasogastric feeds due to severe dysphagia.

Case 2 received intravenous tPA since he presented within window period. He was started on aspirin after 24 hours. Both patients received intensive physiotherapy and speech therapy. There was no surgical or intra-arterial intervention on any of the patients.

Antiplatelet therapy was started for both patients (case 2, after 24 hours repeated CT brain with no haemorrhagic transformation), as there is no evidence of any superiority of anticoagulation.<sup>1</sup>

As there was no recurrent events, endovascular or surgical interventions were not considered.<sup>1</sup>

#### OUTCOME AND FOLLOW-UP

Nasogastric tube could be removed after a week for patient 1 and he had improved completely at 3 months follow-up.

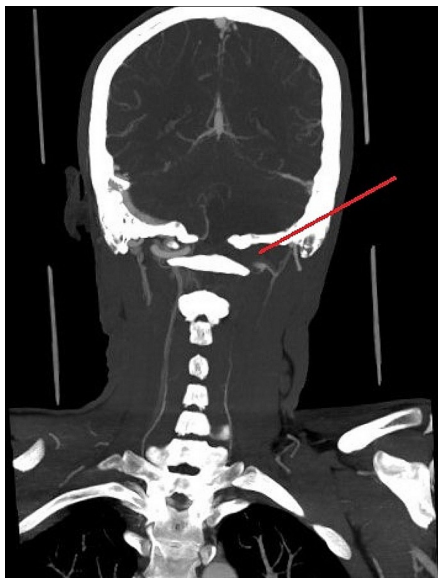


Figure 2 CT angiography showing V4 part occlusion of the left vertebral artery.

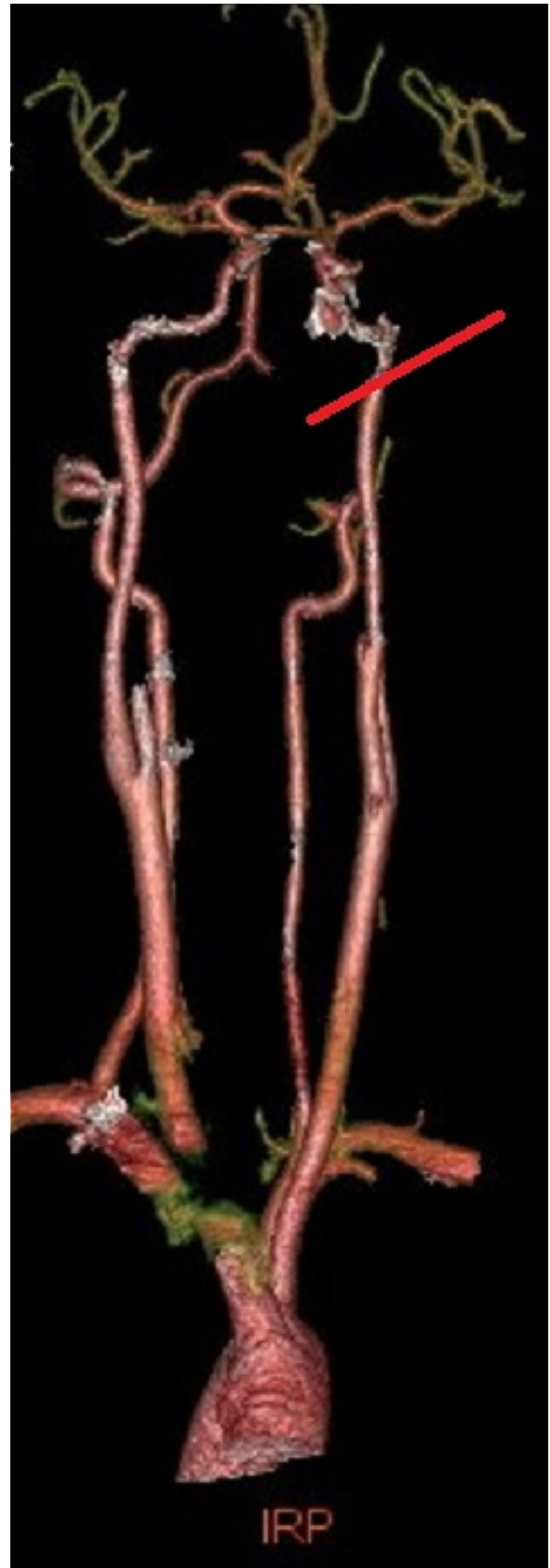
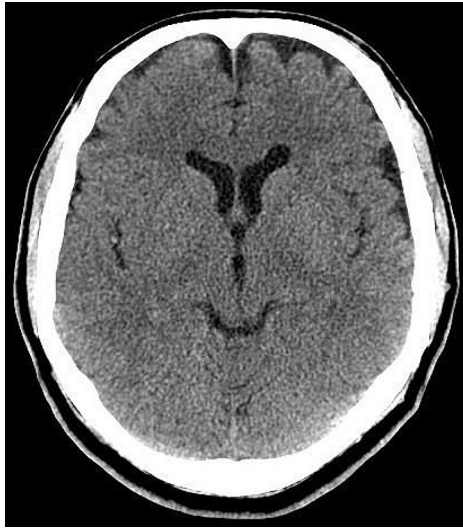

Figure 3 3D angiography.

Patient 2 started walking within few days, his speech started improving and at 3 months follow-up, except for mild word finding difficulty, he has completely improved.

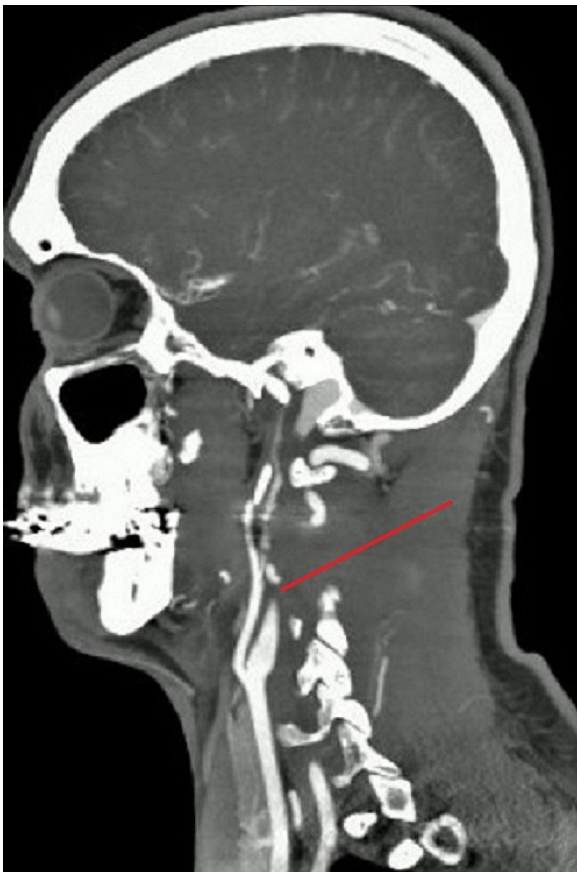


**Figure 4** Plain CT brain, normal.

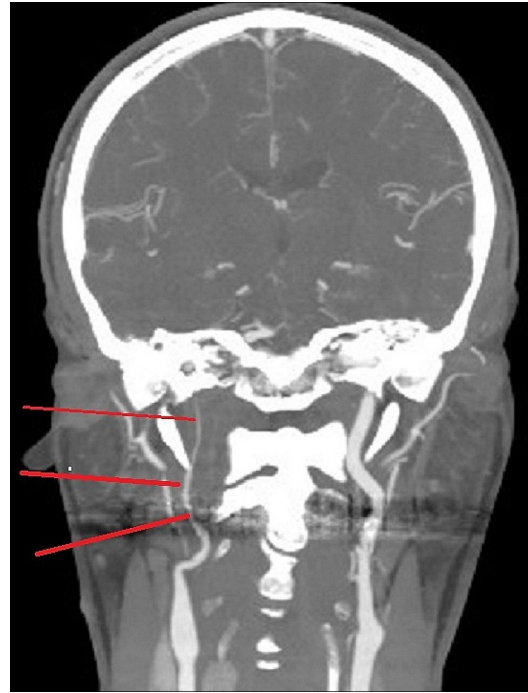
As the patients were improving without any new symptoms or complains, we did not think there was a need to repeat the imaging.

#### DISCUSSION

Cervical arteries dissection is frequently classified as spontaneous, since patients do not take minor trauma seriously. Many causes are mentioned in the literature for cervical arteries dissections. These include swimming,<sup>2 3</sup> scuba diving<sup>4-6</sup> and



**Figure 5** CT angiography, sagittal, showing dissection of the left internal carotid artery.



**Figure 6** CT angiography, coronal, showing dissection of the left internal carotid artery.

#### Learning points

- ▶ Water slides can be responsible for cervical arteries dissection, with mechanisms similar to roller coaster ride-related dissection.
- ▶ Patients presenting with non-specific complains, such as neck pain or headache after a water slide, should be suspected to have cervical arteries dissection.
- ▶ Neurological symptoms can occur even after weeks of cervical artery injury.
- ▶ No difference between antiplatelet and anticoagulation in treating stroke caused by cervical arteries dissection, as by current guidelines.
- ▶ Although the cases are not presenting a new mechanism or new symptoms, but are highlighting a very important point of the delayed stroke after dissection and reminding the doctors of this issue.

springboard diving<sup>7</sup> to mention a few of water activities that can present with cervical arteries dissection. Interestingly, one of the causes mentioned in the literature of cervical arteries dissection is roller coaster or Amusement Park rides<sup>8-11</sup> and this cause was the closest in mechanism to our two causes. In addition, both carotid and vertebral arteries dissection were reported as a complication for roller coaster rides. The proposed mechanism is the hyper-extension, hyperflexion and rotation of the neck,<sup>10</sup> which can be proposed as the possible mechanism of the dissection after water slides. Remarkably, our two patients had delayed presentation, such a scenario is mentioned in the literature and the proposed mechanism is explained by intimal tear or vasa vasorum injury, which cause leak of blood cells into the connective tissue of the artery and progress slowly, causing gradual stenosis up to full occlusion of the artery.<sup>12</sup> Artery to artery embolisation is another mechanism that can explain the delayed presentation. One important reason for delayed presentation is inaccurate

history taking with headache being considered as non-specific headache rather than impending dissection especially in patients with history suggestive of direct or indirect neck trauma.<sup>13</sup>

**Contributors** AMA: diagnosis and management of the second case, writing the manuscript. PS: diagnosis and management of the second case, review of the manuscript. SSG: diagnosis and management of the first case, review of the manuscript.

**Funding** The authors have not declared a specific grant for this research from any funding agency in the public, commercial or not-for-profit sectors.

**Competing interests** None declared.

**Patient consent** Obtained.

**Provenance and peer review** Not commissioned; externally peer reviewed.

### REFERENCES

- 1 Kernan WN, Ovbiagele B, Black HR, *et al.* Guidelines for the prevention of stroke in patients with stroke and transient ischemic attack: a guideline for healthcare professionals from the American Heart Association/American Stroke Association. *Stroke* 2014;45:2160–236.
- 2 Ersoy A, Koç ER, DüzgünÜ, *et al.* A case of carotid artery dissection developed after swimming: The role of heterozygote C677T MTHFR gen mutation, 2013.
- 3 Mohaghegh S, Hajian M. Stroke in a Young Swimmer. *Asian J Sports Med* 2015;6:e23812.
- 4 Bartsch T, Palaschewski M, Thilo B, *et al.* Internal carotid artery dissection and stroke after SCUBA diving: a case report and review of the literature. *J Neurol* 2009;256:1916–9.
- 5 Skurnik YD, Sthoeger Z. Carotid artery dissection after scuba diving. *Isr Med Assoc J* 2005;7:406–7.
- 6 Konno K, Kurita H, Ito N, *et al.* Extracranial vertebral artery dissection caused by scuba diving. *J Neurol* 2001;248:816–7.
- 7 Furtner M, Werner P, Felber S, *et al.* Bilateral carotid artery dissection caused by springboard diving. *Clin J Sport Med* 2006;16:76–8.
- 8 Sheikh SI, Singhal AB. Extension of "Roller Coaster Dissection" after Tissue Plasminogen Activator, 2010.
- 9 Blacker DJ, Wijidicks EFM. A ripping roller coaster ride. *Neurology* 2003;61:1255.
- 10 Lascelles K, Hewes D, Ganesan V. An unexpected consequence of a roller coaster ride. *J Neurol Neurosurg Psychiatry* 2001;71:704–5.
- 11 Biousse V, Chabriat H, Amarengo P, *et al.* Roller-coaster-induced vertebral artery dissection. *Lancet* 1995;346:767. England.
- 12 Völker W, Dittrich R, Grewe S, *et al.* The outer arterial wall layers are primarily affected in spontaneous cervical artery dissection. *Neurology* 2011;76:1463–71.
- 13 Schneck M, Simionescu M, Bijari A. Bilateral vertebral artery dissection possibly precipitated in delayed fashion as a result of roller coaster rides. *J Stroke Cerebrovasc Dis* 2008;17:39–41.

Copyright 2018 BMJ Publishing Group. All rights reserved. For permission to reuse any of this content visit <https://www.bmj.com/company/products-services/rights-and-licensing/permissions/>  
BMJ Case Report Fellows may re-use this article for personal use and teaching without any further permission.

Become a Fellow of BMJ Case Reports today and you can:

- ▶ Submit as many cases as you like
- ▶ Enjoy fast sympathetic peer review and rapid publication of accepted articles
- ▶ Access all the published articles
- ▶ Re-use any of the published material for personal use and teaching without further permission

For information on Institutional Fellowships contact [consortiasales@bmjgroup.com](mailto:consortiasales@bmjgroup.com)

Visit [casereports.bmj.com](http://casereports.bmj.com) for more articles like this and to become a Fellow