

Delayed-Onset Dystonia Associated with Corticospinal Tract Dysfunction¹

Stewart A. Factor, Juan Sanchez-Ramos, and William J. Weiner

University of Miami, Department of Neurology, Miami, Florida, U.S.A.

Summary: We report a young man with delayed-onset dystonia secondary to a cerebral infarction. The infarction was caused by an embolic event at the age of 18 months. Delay to onset of dystonia was 16 years and, prior to the onset of dystonia, the patient had profound corticospinal tract dysfunction manifested by a severe hemiparesis. Computed tomography scan revealed infarction of the lentiform nucleus and precentral gyrus. The profound involvement of the corticospinal tract both clinically and radiologically are features not previously described in symptomatic dystonia and contradict the concept that sparing of the corticospinal tract is an essential feature for the onset of acquired dystonia. **Key Words:** Delayed-onset dystonia—Hemidystonia—Cerebral infarction—Corticospinal tract—Trihexiphenidyl.

Although dystonia occurring months to years after a nonprogressive cerebral insult was first recognized over a century ago (1,2), it was in 1980 that Burke and associates (3) provided detailed clinical descriptions. In two recent studies of over 20 patients with symptomatic dystonia (4,5), the most common etiology for delayed onset was cerebrovascular disease. Cerebrovascular insults resulting in delayed-onset dystonia have included thrombotic and embolic infarctions, hypertensive hemorrhage, and lesions secondary to hemiplegic migraine. Patients with poststroke dystonia (often referred to as posthemiplegic dystonia) have been a source of extremely helpful data in determining the anatomic correlates of dystonia. Anatomic locations in previously published cases have most commonly included the putamen and, to a lesser extent, the caudate nucleus and thalamus. The corticospinal tract is typically spared or only minimally involved. The relative sparing of the corticospinal tract in delayed-onset dystonia has been supported by both clinical and pathologic observations. This has been considered to be an important prerequisite for dystonia to occur (6).

We present a case of a young man with delayed-onset dystonia associated with

¹ A videotape segment accompanies this article.

Address correspondence and reprint requests to Dr. W. J. Weiner at University of Miami School of Medicine, Department of Neurology (D4-5), P.O. Box 016960, Miami, FL 33101, U.S.A.

a past history of a cerebral embolic infarction secondary to a congenital heart defect. The resulting infarction included both subcortical and cortical areas, including the motor cortex, with significant dysfunction of the corticospinal tract.

CASE REPORT

The patient is a 21-year-old left-handed hispanic man who presented with a 3-year history of abnormal involuntary movements of the right upper and lower extremities. The movements in the upper extremity were described as twisting, with internal rotation of the arm and extension of the fingers and wrist. The lower extremity movements included curling under of the toes and inversion of the foot. The movements were progressive for ~2.5 years before reaching a plateau. Frequently, the movements resulted in sustained postures that lasted minutes to hours. The sustained postures of the foot made walking impossible at times, and this is the complaint that brought him to our clinic. He noted that stress and emotion worsen the movements. He has no sensory tricks to stop them. Biofeedback had not been helpful.

Past medical history revealed that his birth was complicated by poor progression. The records of this incident were not available, and all information was volunteered by his mother. After ~36 h of labor, fetal distress was present. A cesarean section was performed, and the umbilical cord was found around the infant's neck at the time of delivery. The infant (our patient) did not require respiratory support or resuscitation. Apgar scores were not known. A diagnosis of tetralogy of Fallot was made, and he was discharged from the hospital at 7 days.

Over the next 18 months, he developed normally both physically and intellectually, reaching all milestones at appropriate times. At the age of 18 months, he experienced a sudden onset of right hemiparesis secondary to a cardiac embolic event. The weakness was greater in a distal distribution and in the arm more than the leg. All dexterity of the right hand was lost, and he was unable to ambulate without assistance. Between 18 months and 7 years of age, he had two cardiac reconstructions performed, and he did well after both. His hemiparesis did not significantly improve, and he was left with a weak and spastic right upper extremity and no manual dexterity. He also had a weak, but spastic, lower extremity; however, after extensive physical therapy, he was able to ambulate without assistance with a hemiplegic gait. He denied the presence of abnormal involuntary movements prior to the age of 18 years. Intellectually, he continued to develop normally, and although he started school late, he has completed high school and 2 years of college with above-average grades. He is a well-adjusted individual, who did not consider himself to be handicapped until the onset of hemidystonia at the age of 18.

Medications include baclofen, 90 mg/day, for spasticity and digoxin, 0.25 mg/day. There is no history of neuroleptic use and no family history of dystonia or other movement disorder.

On examination, his blood pressure was 110/70. Cardiac exam revealed numerous chest scars from previous surgeries and a loud high-pitched ejection murmur.

The rest of the general exam was unremarkable. On neurologic exam, his mental status was completely normal. A right central facial palsy was observed. The remainder of the cranial nerves were normal. On motor examination, his left side was normal in strength and tone. No abnormal movements were seen. At rest, dystonic movements, including sustained postures that lasted seconds to minutes, were observed in the right arm and leg in a distal distribution. The fingers were extended with a swan neck-like posture, and the wrist was also extended. When the arms were extended with the palms down, the right arm rotated in a clockwise manner (from the examiner's perspective), such that the thumb position was rotated approximately 150°. He sat on his right hand in order to control the movements. In the lower extremity, the toes would curl under and the foot would plantar flex and invert. Muscle tone was increased on the right, and sustained postures could not be altered. He had no manual dexterity on the right in that he could not finger tap, and in addition, he was unable to toe tap on the right side but did so normally on the left. He had a right hemiparesis with $\frac{4}{5}$ proximal weakness in the right upper and lower extremities. Distally, significant weakness was observed; however, the extent of this weakness was obscured by the presence of dystonia. Muscle stretch reflexes were brisk and symmetrical. The plantar response was flexor on the left and equivocal on the right because of the presence of abnormal movements. Cerebellar exam revealed no ataxia. He could rise from a chair without assistance. He could ambulate independently; however, the dystonic movements continued while walking and may have actually increased in intensity. The toes of the right foot tended to curl with each step, forcing him to place weight on the dorsal aspect of his toes. He had no postural instability. Although the Fahn-Marsden scale (7) is sometimes less meaningful when scoring patients with secondary dystonia, it was utilized for this patient. The dystonic movement score was 28, whereas the disability score was 7. The latter score reflects the patient's overall disability and not disability of the involved side alone.

A computed tomography (CT) scan revealed an old left middle cerebral artery infarction involving the frontoparietal cortex (including the primary motor strip), subcortical white matter, and the lateral aspect of the lentiform nucleus. There was secondary hemiatrophy, lateral ventricular dilatation, and also atrophy of the thalamus (Fig. 1).

The patient was placed on trihexiphenidyl with a gradually increasing dose to 9 mg/day. Three months later, he noted significant improvement. The foot dystonia was occurring only under stressful situations, and this significantly improved his ambulation. In the upper extremity, he experienced less internal rotation and less finger extension; however, wrist extension appeared to be worse. The function of this extremity was less important, as it was only minimally functional before the onset of dystonia. When he extended his arm, the fingers were still in an abnormal posture and the wrist also remained extended. However, the movements occurred less frequently and to a lesser degree and the arm internal rotation decreased. The lower extremity revealed the same movements as observed previously, but they were occurring less frequently and had a shorter duration. With walking, the toes curled under less frequently, allowing him to walk flat-footed instead of on the

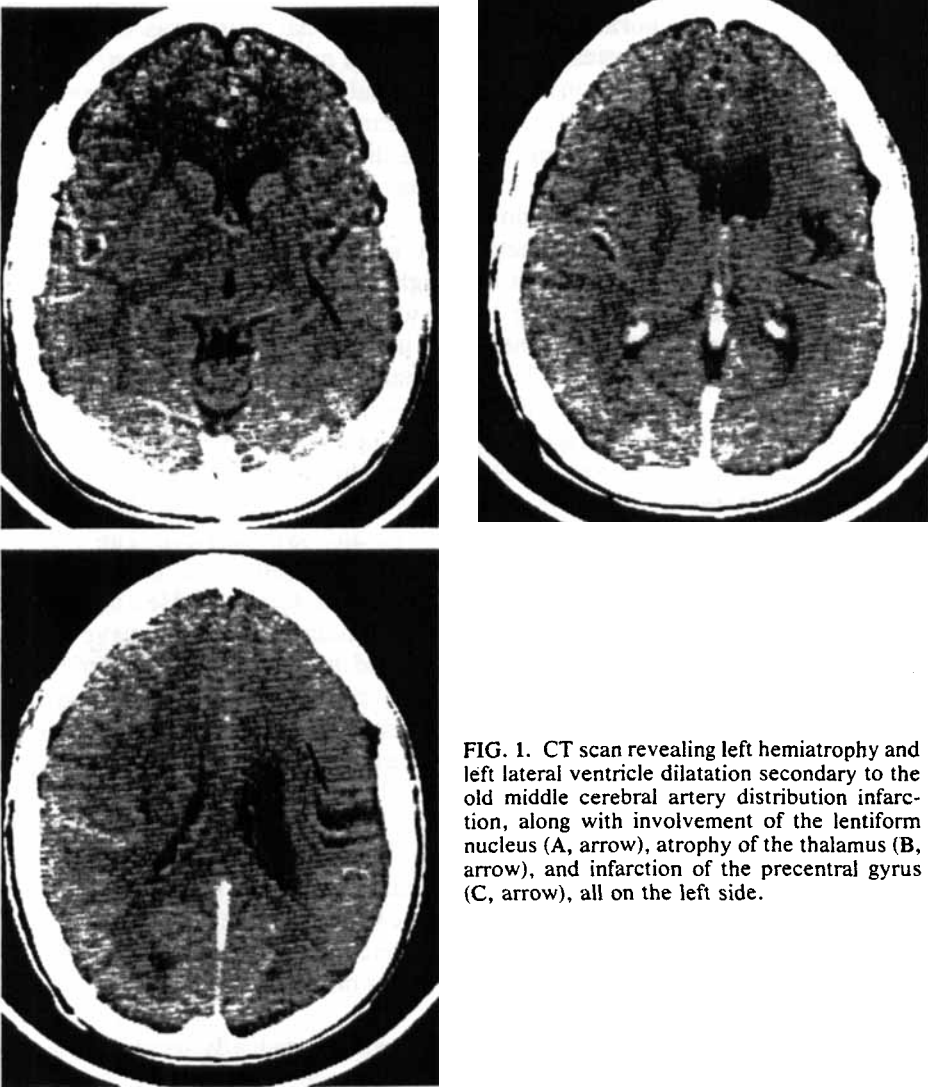


FIG. 1. CT scan revealing left hemiatrophy and left lateral ventricle dilatation secondary to the old middle cerebral artery distribution infarction, along with involvement of the lentiform nucleus (A, arrow), atrophy of the thalamus (B, arrow), and infarction of the precentral gyrus (C, arrow), all on the left side.

dorsal surfaces of the toes that had been seen previously. The Fahn-Marsden score was 24, whereas the disability score was 6. We recommended increasing the trihexiphenidyl, but the patient was satisfied with his current status and wished to remain on 9 mg.

DISCUSSION

The evidence suggests that the patient's dystonia is secondary to his cerebral infarction and not to perinatal hypoxia. First, there is a somatotopic relationship

between the distribution of the hemiparesis and the subsequent hemidystonia. Second, during the first 18 months of the patient's life, he was developing normally both physically and intellectually until the embolic event. Crothers and Paine (8) noted that the majority of patients with extrapyramidal cerebral palsy had abnormal motor development that was usually observed between the ages of 10 and 18 months. Although there may have been fetal distress in this patient, it would have had to have been mild, as there were no resuscitative measures employed, and the patient was sent home with no special instructions after a routine hospital stay. Whether or not mild fetal distress can influence the presentation of dystonia is difficult to assess and has been questioned (9). Burke and associates (3) discussed its possible influence on idiopathic torsion dystonia and drug-induced dystonia with no final conclusion.

Dystonia is a rare complication of stroke. However, it may occur in one of three settings. First, the movements may present acutely at the time of the insult (4,5,10). Second, dystonia may occur weeks to months after the vascular event as the neurologic deficit resolves—so-called posthemiplegic dystonia. In this situation, the dystonia represents part of the evolution of the lesion. The mechanism of onset of the dystonia is unclear but may be due to resolution of reversible changes, such as ischemic neuronal dysfunction or edema associated with the irreversible injury. The third setting involves the onset of dystonia at a remote time (1 year or more) after the vascular insult, when the patient is stabilized and the lesion is no longer thought to be evolving. This is the most uncommon situation, and our patient is in this category. The temporal difference in the appearance of dystonia suggests a different mechanism of onset in the third category as opposed to the second. It has been hypothesized that the mechanism of onset of delayed-onset dystonia occurring a year or more after the insult may be due to aberrant neuronal sprouting (3).

A review of the literature revealed 25 cases of delayed-onset dystonia secondary to cerebrovascular disease (see Table 1). Average age at the time of the vascular event in these patients was 54 years, with an average delay to onset of dystonia of 6 months. Only four patients (average age of 54) experienced a delay of 1 year or greater, with the longest being 3 years (4). Our patient experienced a delay of 16 years prior to the onset of dystonia and his age at the time of the stroke was the youngest (18 months). Pettigrew and Jankovic (5) observed a similar pattern, in that a cerebral injury prior to the age of 7 years resulted in a mean delay duration of 9.7 years to dystonia onset, whereas adult-onset injury led to an average delay of 6 months. This pattern is also present when evaluating perinatal insults that tend to result in the longest delay duration (the longest being 32 years) (5). These findings suggest that age at the time of injury may be more important than etiology of the injury in dictating the duration of delay. Other factors not yet understood probably also contribute to the delay duration, as Demierre (12) has described two young patients, one a 3-year-old with posttraumatic dystonia and the other a 7-year-old with poststroke dystonia, both of whom had only a 1-month delay.

The etiology of the stroke in the 25 patients with secondary dystonia included

TABLE 1. Clinical characteristics and CT results in 25 patients reported in the literature with poststroke dystonia

Reference	Patient no.	Age at insult	Duration of delay	Distribution of dystonia	Etiology of stroke	CT scan findings
Burke (1)	7	65	1 Year	Left arm and jaw	Infarction ^a	Right MCA territory
Grimes (11)	8	54	1 Year	Left arm	Infarction	Normal
	1	32	6 Months	Left hand	Hemiplegic migraine	Right putamen caudate, thalamus
	2	50	5 Months	Left arm and face	Infarction	Right putamen, thalamus, temporal and parietal cortex
	3	60	6 Months	Left arm	Infarction	Right putamen caudate, anterior internal capsule, thalamic atrophy
DeMierre (12)	2	7	3 Weeks	Left hemidystonia	Infarction	Right putamen
	3	17	1 Month	Left hemidystonia	Embolus infarction	Internal capsule caudate
Glatt (13)	2	68	4 Months	Left hemidystonia	Infarction	Right lentiform and caudate nuclei, internal capsule
Obeso (14)	1	22	2 Months	Left hemidystonia	Infarction	Right thalamus, occipital, temporal cortex
Sunohara (15)	1	61	3 Months	Left hemidystonia	Hemiplegic migraine	Right thalamus
Burton (16)	1	47	9 Months	Left hemidystonia	Infarction	Right thalamus, post-internal ^b capsule
Petigrew (5)	1	47	9 Months	Left hemidystonia	Infarction	Right putamen ^c
	15	36	1 Month	Left hemidystonia	Infarction	Internal capsule, Right basal ganglia

16	61	6 Months	Left hemidystonia	Infarction	Right internal capsule
17	46	1 Month	Left hand	Embolc infarction	Right basal ganglia
19	40	1 Month	Left hand and arm	Infarction	Right basal ganglia
20	72	1 Month	Right arm and head	Infarction	Normal
21	22	1 Month	Left hemidystonia	Hemiplegic migraine	Right internal capsule
22	52	1 Month	Right hemidystonia	Hypertensive hemorrhage	Left thalamus and basal ganglia
10	68	2 Months	Right hand	Infarction	Left thalamus
12	62	6 Months	Left hand	Infarction	Right thalamus
13	60	9 Months	Left hemidystonia	Hemorrhage	Right thalamus
19	52	4 Months	Right hemidystonia	Infarction	Left lentiform and caudate nuclei and internal capsule
20	51	6 Months	Right foot	Infarction	Left lentiform and caudate nuclei and internal capsule
21	49	1 Year	Left hemidystonia	Embolc infarction	Right lentiform and caudate nuclei and internal capsule
22	48	3 Years	Left hemidystonia	Infarction	Right lentiform and caudate nuclei and internal capsule

Marsden (4)

^a Infarction indicates thrombotic origin unless otherwise noted.

^b Indicates autopsy result.

^c Indicates both CT and MRI scan result.

three patients with embolic infarction, three patients with hemiplegic migraine, two patients with hypertensive hemorrhage, and the rest with probable thrombotic infarction. Of the three patients with embolic stroke, one was due to an artificial aortic valve that was surgically placed 9 years prior to the stroke (4), one was due to an arrhythmia (12), and in one, the source was not indicated. Our patient had an embolic event secondary to a congenital heart defect.

In a majority of the patients, including those with delays of 1 year or more, the neurologic deficits resolved to normal or near normal. This has been interpreted as clinical evidence that there was minimal corticospinal tract dysfunction. This was not the case with the patient presented here, in whom a dense hemiparesis remained up to the time of onset of his movement disorder, suggesting fairly significant corticospinal tract dysfunction. Thus, resolution of the hemiplegia is not necessary for the dystonia to occur. Marsden et al. (4) made the same suggestion as a result of observing patients with minimal initial neurologic deficits who had delayed-onset dystonia.

Dystonia is considered to be the result of basal ganglia dysfunction. As there are no known pathologic correlates to idiopathic torsion dystonia, the pathologic-anatomic basis of this movement disorder has been studied using cases of symptomatic dystonia. In 1968, Zeman and Whitlock (17) observed that basal ganglia pathology was consistently present in patients with symptomatic dystonia. Dooling and Adams (6) reported in 1975 on the postmortem examinations of five patients with posthemiplegic athetosis and compared the results with those of nine patients with adult-onset hemiplegia and no movement disorder. They concluded that the essential lesion for the onset of athetosis was located in the striatum, with secondary involvement of the striatopallidal pathway and the thalamus. In addition, the five patients with athetosis had relative sparing of the corticospinal tract as compared to the nine controls who did not, suggesting that sparing of the corticospinal tract was an essential condition for the onset of posthemiplegic athetosis. Since that time, additional studies utilizing neuroimaging techniques to evaluate posthemiplegic dystonia (11-16) have provided further evidence in support of Dooling and Adams's findings. In 1985, Pettigrew and Jankovic (5) reported 22 cases of symptomatic dystonia, eight of which were due to cerebrovascular disease (seven of these were delayed in onset). They stated that "sparing of the corticospinal tract and disruption of the pathways between the striatum, pallidum, and thalamus are probably essential for secondary dystonia to occur." Sixteen of their patients did have partial involvement of the corticospinal tract with internal capsule lesions, however, clinically, the dysfunction was always mild. Also in 1985, utilizing CT scans, Marsden et al. (4) evaluated the anatomical basis of symptomatic hemidystonia in 28 patients, 11 of whom had cerebrovascular disease (7 of these were delayed onset). It was concluded that "symptomatic dystonia may be produced by lesions in the thalamus or caudate or lentiform nuclei (particularly the putamen) or in a combination of these structures." They suggested that the dystonia was due to a release of premotor cortical activity from the thalamus. They found 13 patients with internal capsule lesions, but corticospinal tract dysfunction was considered to be mild on a clinical basis. In addition,

4 patients with cortical lesions were discussed. None of these had delayed onset dystonia and the primary motor cortex was not involved, thus sparing the corticospinal tract. Our patient, in addition to lentiform nucleus involvement, had definite corticospinal tract dysfunction both clinically (as noted by history and evident by the presence of a right hemiparesis, right central facial palsy, and equivocal right plantar response) and radiologically and a delayed-onset dystonia. We suggest that sparing of the corticospinal tract may not be essential for dystonia to occur. There may be other factors besides corticospinal tract sparing that differentiated posthemiplegic athetotic patients from controls. Research in this area should focus on the putamen as previously recommended by Burton and associates (16).

Symptomatic dystonia, like idiopathic dystonia, is a difficult entity to treat. Marked improvement in patients has been rare, and of the cases in Table 1 where results of treatment are available, there were only two patients with a significant response. In the patient presented by Obeso (14), propranolol with clonazepam was helpful, and in the patient presented by Sunohara (15), clonazepam and 5-hydroxytryptophan resulted in cessation of dystonia. Milder improvement has been observed with other combinations of medications; however, results with anticholinergics have been disappointing. Case 2 of Glatt actually worsened. Pettigrew and Jankovic (5) used trihexiphenidyl on five of seven poststroke dystonic patients as well as a number of other patients in their 22 cases with poor results. Fahn (18) has noted similar disappointment with these patients. The patient presented here experienced a good response with a low dose of trihexiphenidyl, with improvement of both foot and arm dystonia. His gait improved significantly, and this was his primary complaint. It is unclear why this patient should respond where the others did not. Perhaps the corticospinal tract involvement contributed to this in some way.

LEGEND TO VIDEOTAPE

Delayed-onset dystonia associated with corticospinal tract dysfunction. The patient has right hemidystonia that is distal in distribution. In the upper extremity, the fingers are extended with a swan neck deformity. With the arms extended anteriorly, the wrist is in an extended position and the arm is rotated in a clockwise manner. In the right lower extremity, the toes involuntarily curl under and the foot rotates internally. These involuntary movements are accentuated during ambulation.

Acknowledgment: This study was funded in part by the National Parkinson Foundation.

REFERENCES

1. Hammond WA. *A treatise on diseases of the nervous system*. New York: Appleton 1871.
2. Gowers WR. *A manual of diseases of the nervous system*. London: J and A Churchill, 1886.
3. Burke RE, Fahn S, Gold AP. Delayed onset dystonia in patients with "static" encephalopathy. *J Neurol Neurosurg Psychiatry* 1980;43:789-97.

4. Marsden CD, Obeso JA, Zarrantz JJ, Lang AE. The anatomical basis of symptomatic hemidystonia. *Brain* 1985;108:463-83.
5. Pettigrew LC, Jankovic J. Hemidystonia: a report of 22 patients and a review of the literature. *J Neurol Neurosurg Psychiatry* 1985;48:650-7.
6. Dooling EC, Adams RD. The pathologic anatomy of posthemiplegic athetosis. *Brain* 1975, 98:29-48.
7. Burke RE, Fahn S, Marsden CD, Bressman SB, Moskowitz C, Friedman J. Validity and reliability of a rating scale for primary torsion dystonias. *Neurology* 1985;35:73-7.
8. Crothers B, Paine RS. *The natural history of cerebral palsy*. Cambridge: Harvard University Press, 1959:120.
9. Obeso JA, Vaamonde J, Barraquer-Bordas L. Delayed onset dystonia (letter). *J Neurol Neurosurg Psychiatry* 1985;48:1,190-1.
10. Russo LS. Focal dystonia and lacunar infarction of the basal ganglia. *Arch Neurol* 1983;40:61-2.
11. Grimes JD, Hassan MN, Quarrington AM, D'Alton J. Delayed onset posthemiplegic dystonia: CT demonstration of basal ganglia pathology. *Neurology (NY)* 1982;32:1,033-5.
12. Demierre B, Rondot P. Dystonia caused by putamino-capsulo-caudate vascular lesions. *J Neurol Neurosurg Psychiatry* 1983;46:404-9.
13. Glatt SL, Nausieda PA. Posthemiplegic dystonia: radiographic and pharmacologic analysis. *Neurology* 1984;34(suppl):290-1.
14. Obeso JA, Martinez Vila E, Delgado G, Vaamonde J, Maravi E, Martinez Lage JM. Delayed onset dystonia following hemiplegic migraine. *Headache* 1984;24:266-8.
15. Sunohara N, Mukoyama M, Mano Y, Satoyoshi E. Action-induced rhythmic dystonia: an autopsy case. *Neurology (Cleveland)* 1984;34:321-7.
16. Burton K, Farrell K, Li D, Calne DB. Lesions of the putamen and dystonia: CT and magnetic resonance imaging. *Neurology* 1984;34:962-5.
17. Zeman W, Whitlock CC. Symptomatic dystonias. In: Vinken PJ, Bruyn GW, eds. *Handbook of neurology*. Amsterdam: North Holland, 1968;544-66.
18. Fahn S. High dosage anticholinergic therapy in dystonia. *Neurology* 1983;33:1,255-61.