


Accepted Manuscript

Multiple brain metastases from pancreatic adenocarcinoma presenting with simultaneous intratumoral hemorrhages: A case report

Satoshi Matsuo, MD, PhD, Toshiyuki Amano, MD, PhD, Shigeto Kawauchi, MD, PhD, Akira Nakamizo, MD, PhD



PII: S1878-8750(18)32859-6

DOI: <https://doi.org/10.1016/j.wneu.2018.12.036>

Reference: WNEU 10982

To appear in: *World Neurosurgery*

Received Date: 10 October 2018

Accepted Date: 5 December 2018

Please cite this article as: Matsuo S, Amano T, Kawauchi S, Nakamizo A, Multiple brain metastases from pancreatic adenocarcinoma presenting with simultaneous intratumoral hemorrhages: A case report, *World Neurosurgery* (2019), doi: <https://doi.org/10.1016/j.wneu.2018.12.036>.

This is a PDF file of an unedited manuscript that has been accepted for publication. As a service to our customers we are providing this early version of the manuscript. The manuscript will undergo copyediting, typesetting, and review of the resulting proof before it is published in its final form. Please note that during the production process errors may be discovered which could affect the content, and all legal disclaimers that apply to the journal pertain.

Multiple brain metastases from pancreatic adenocarcinoma presenting with simultaneous intratumoral hemorrhages: A case report

Satoshi Matsuo, MD, PhD^a, Toshiyuki Amano, MD, PhD^a, Shigeto Kawauchi, MD, PhD^b, Akira Nakamizo, MD, PhD^a

Departments of ^aNeurosurgery and ^bPathology, Clinical Research Institute, National Hospital Organization Kyushu Medical Center, Fukuoka, Japan

Declarations of interest: None.

Address all correspondence to: Satoshi Matsuo, MD, PhD

Department of Neurosurgery, Clinical Research Institute, National Hospital Organization, Kyushu Medical Center, 1-8-1 Jigyo-hama, Fukuoka 810-8563, Japan

TEL: +81-92-852-0700; FAX: +81-92-846-8485; E-mail: smatsuo1979@gmail.com

Keywords: Intratumoral hemorrhage, Metastatic brain tumor, Pancreatic adenocarcinoma

Abbreviation List: CT, computed tomography; MRI, magnetic resonance imaging

Abstract

Background

Pancreatic adenocarcinoma rarely metastasizes to the brain, and the clinical features of brain metastasis in such cases remain elusive. To the best of our knowledge, only 21 cases of brain metastasis from pancreatic adenocarcinoma have been previously reported in the English-language literature.

Case Description

One year 4 months before the current admission, a 61-year-old woman was diagnosed with pancreatic adenocarcinoma and began chemotherapy. Three days before the current admission, she developed acute dysarthria. She was referred to a cancer center, where neuroradiological examination revealed multiple metastatic brain tumors, including a 30-mm-diameter tumor in the right cerebellar region. She was transferred to our institute. Three days after admission, she developed sudden-onset disturbance of consciousness and left hemiparesis. Head computed tomography and magnetic resonance imaging showed that the multiple metastatic lesions had increased in size with the development of intratumoral hemorrhage and obstructive hydrocephalus. She underwent urgent removal of the tumor in the cerebellum. The obstructive hydrocephalus was relieved and her consciousness improved immediately after the surgery. She was transferred to the palliative care unit of the cancer center and died under hospice care 3 weeks after the surgery.

Conclusions

This case demonstrates that brain metastases from pancreatic adenocarcinoma can enlarge suddenly and

simultaneously by intratumoral hemorrhage even without coagulation disorders, resulting in neurological deterioration in a short time. Surgical resection of metastatic brain lesions from pancreatic adenocarcinoma has an extremely limited role, but such treatment can remove the neurological symptoms and temporarily improve the patient's quality of life in selected cases.

Introduction

Pancreatic adenocarcinoma is a relentlessly progressive and fatal disease with an overall 5-year survival rate of <5%.¹ Because of the absence of early signs or characteristic symptoms, most patients with pancreatic adenocarcinoma present with metastatic disease involving the lymph nodes, liver, peritoneum, lungs, or bone at the time of diagnosis.^{1,2} Pancreatic adenocarcinoma can metastasize to the central nervous system, but this is quite rare.^{2,3} Due to recent advancements in the treatment of pancreatic cancer, the incidence of brain metastasis in such patients may be increasing.⁴

We herein describe a case of multiple brain metastases from pancreatic adenocarcinoma that progressively enlarged by intratumoral hemorrhage and were treated surgically. To our knowledge, this is the first report of a patient with multiple hemorrhagic brain metastases that progressively and simultaneously enlarged within a short time.

Case report

One year 4 months before the present admission, a 61-year-old woman was found to have a tumor in the tail of the pancreas with ascites. Cytological analysis of the ascites led to a diagnosis of pancreatic adenocarcinoma. She underwent multi-agent systemic chemotherapy regimens involving gemcitabine, nab-paclitaxel, and S-1 (tegafur, gimeracil, and oteracil potassium). Three months before the present admission, she developed difficulty breathing, and chest computed tomography (CT) showed that the pleural effusion was due to carcinomatous pleurisy. After the patient underwent a modified FOLFIRINOX

regimen, her pleural effusion resolved and her dyspnea was relieved. Three days before the current admission, she presented to an emergency department with acute onset of dysarthria. Head CT and magnetic resonance imaging (MRI) showed multiple lesions, including a 3-cm cerebellar lesion (**Fig. 1**). A prognosis of at least a few months was predicted despite the presence of carcinomatous peritonitis and pleurisy and liver and brain metastases. Palliative whole-brain radiation was planned; however, the patient and her family expressed their desire to pursue treatment as long as she could tolerate it. On admission, her mental status was alert and she exhibited mild dysarthria. Laboratory data revealed no thrombocytopenia or blood coagulation disorders (platelet count, $299 \times 10^3/L$; activated partial thromboplastin time, 22.8 s; prothrombin time–international normalized ratio, 1.11). Suboccipital craniotomy with resection of the tumors in the cerebellum was planned to avoid obstructive hydrocephalus and brain stem compression induced by the enlargement of the lesions. Three days after admission, she developed a sudden disturbance of consciousness (Glasgow coma scale score of E3V3M6) and left hemiparesis. CT and MRI showed that the multiple metastatic lesions in the initial imaging studies had increased in size with intratumor hemorrhage and obstructive hydrocephalus (**Fig. 2**). After a lengthy discussion regarding the extent of her disease and the prognosis, the patient's family expressed their desire to pursue treatment as long as she could tolerate it. She underwent removal of the tumors in the cerebellum through a suboccipital craniotomy, and the obstructive hydrocephalus was improved (**Fig. 3**). Histopathological analysis revealed moderately to highly differentiated tubular adenocarcinoma, which was consistent with metastasis from the pancreatic adenocarcinoma (**Fig. 4**). Her disturbance of consciousness recovered immediately after the surgery, and

she could communicate with her family. Although removal of the supratentorial lesions was planned, the patient declined the additional surgery and was transferred to hospice care. Her clinical condition deteriorated, and she died under hospice care 3 weeks after the surgery.

Discussion

Brain metastasis, which occurs in 10% to 35% of adult patients with cancer,^{5,6} is frequently diagnosed in patients with lung cancer (48%), breast cancer (15%), testicular cancer (10%), and malignant melanoma (6%–10%); however, brain metastasis rarely arises from gastrointestinal tract cancers (<4%).² Brain metastasis from pancreatic adenocarcinoma is extremely rare (0.33%),³ and its clinical features remain elusive. To the best of our knowledge, only 22 cases of brain metastasis from pancreatic adenocarcinoma, including the present case, have been reported (Table 1).^{3,7-17} Most of the patients (86.4%, 19/22) showed other remote metastases in the liver, lungs, lymph nodes, or bone.¹⁶ The median time from diagnosis of pancreatic adenocarcinoma to brain metastasis was 17.8 months (range, 0–65 months). The brain metastasis occurred late in the clinical course, but it was the first clinical manifestation in 22.7% (5/22) of the patients. More than half of the patients showed a single lesion rather than multiple lesions (59.1%, 13/22). Seven of the 22 patients showed cystic brain metastases, and 10 patients showed solid metastases.

Only one patient in addition to the herein-described patient developed intratumoral hemorrhage of brain metastasis from pancreatic adenocarcinoma.⁸ However, intratumoral hemorrhage is common in brain metastasis from melanoma, breast, thyroid, and renal cell carcinoma.⁶ Kamar et al.⁸ reported a case

of multiple brain metastases from pancreatic adenocarcinoma accompanied by small frontoparietal hemorrhage, and repeated MRI showed tumor enlargement with intratumoral hemorrhage in a short time. The authors did not conclude that the cause of the intratumoral hemorrhage was thrombocytopenia. In our case, the patient's blood pressure was stable during the hospital stay, and no coagulation disorders were evident. The exact cause remains elusive; however, some systemic factors may result in simultaneous intratumoral hemorrhage. Aside from the etiology of the multiple tumor enlargement observed in the present case, we should be aware that multiple brain metastatic lesions from pancreatic adenocarcinoma can enlarge suddenly and simultaneously.

Until recently, pancreatic adenocarcinoma has been an aggressive malignancy with an extremely poor prognosis, and surgical resection of brain metastasis has had a very limited role. However, advancements in imaging techniques for early diagnosis and therapeutic agents have improved the prognosis of pancreatic adenocarcinoma over the past few decades.⁴ Among 13 patients with a single metastatic lesion, 9 (69.2%) patients underwent surgical resection and 6 (46.2%) survived for >12 months after surgery (**Table 1**). Unless a single metastasis is located in a high-risk area or the patient has a poor performance status, surgical resection appears to have a significant benefit for single metastatic lesions. In patients with multiple metastases (n = 9), the prognosis is extremely poor, and only two patients underwent surgical resection (**Table 1**). Kumar et al.¹⁵ described a patient who underwent three craniotomies followed by whole-brain irradiation during the disease course. However, the postoperative course was not described. In the present case, the patient died 3 weeks after the craniotomy because of worsening of the primary

lesion, and resection of the tumors might not have improved the prognosis. However, her disturbance of consciousness improved immediately after the surgery, and she was able to spend the remainder of her life meaningfully. In this regard, surgical resection might be of benefit to selected patients, even those with multiple brain metastases.

Conclusion

Brain metastases from pancreatic adenocarcinoma can enlarge suddenly and simultaneously by intratumoral hemorrhage even without coagulation disorders and cause neurological deterioration within a short time. Surgical resection of brain metastases from pancreatic adenocarcinoma has an extremely limited role, but it can improve the neurological symptoms even in patients with multiple brain metastases.

Acknowledgement

We would like to thank Angela Morben, DVM, ELS, from Edanz Group (www.edanzediting.com/ac), for editing a draft of this manuscript.

Funding

This research did not receive any specific grant from funding agencies in the public, commercial, or not-for-profit sectors.

Figure legends

Figure 1. Head CT and MRI on admission. (a, b) Axial CT and (c, d) fluid-attenuated inversion recovery MRI showed multiple mass lesions scattered throughout the parenchyma, including a 3-cm cerebellar lesion.

Figure 2. Head CT and MRI on Day 3. (a–c) Axial CT images showed an increase in the size of the lesions with intratumoral hemorrhage. (b) Mild enlargement of the ventricle was apparent.

Figure 3. Postoperative head CT images. (a) Axial CT showed complete removal of the tumors in the cerebellum. (b) Enlargement of the ventricle improved after the operation.

Figure 4. Histological examination of the resected brain tumor. At $\times 200$, the tumor displayed cribriform, acinar, and papillary architectural patterns infiltrating the brain parenchyma.

References

1. Hidalgo M. Pancreatic cancer. *N Engl J Med*. 2010;362:1605-1617.
2. Go PH, Klaassen Z, Meadows MC, Chamberlain RS. Gastrointestinal cancer and brain metastasis: a rare and ominous sign. *Cancer*. 2011;117:3630-3640.
3. Park KS, Kim M, Park SH, Lee KW. Nervous system involvement by pancreatic cancer. *J Neurooncol*. 2003;63:313-316.
4. Sun H, Ma H, Hong G, Sun H, Wang J. Survival improvement in patients with pancreatic cancer by decade: a period analysis of the SEER database, 1981-2010. *Sci Rep*. 2014;4:6747. doi: 10.1038/srep06747.
5. Lin X, DeAngelis LM. Treatment of Brain Metastases. *J Clin Oncol*. 2015;33(30):3475-3484.
6. Barajas RF Jr, Cha S. Metastasis in Adult Brain Tumors. *Neuroimaging Clin N Am*. 2016;26:601-620.
7. Kuratsu J, Murakami M, Uemura S, Ushio Y. Brain and skull metastases of hepatic or pancreatic cancer--report of six cases. *Neurol Med Chir (Tokyo)*. 1990;30:476-482.
8. El Kamar FG, Jindal K, Grossbard ML, Mizrahi HH, Kozuch PS. Pancreatic carcinoma with brain metastases: case report and literature review. *Dig Liver Dis*. 2004;36:355-360.
9. Caricato M, Borzomati D, Ausania F, Garberini A, Rabitti C, Tonini G, Coppola R. Cerebellar metastasis from pancreatic adenocarcinoma. A case report. *Pancreatol*. 2006;6:306-308.
10. Marepaily R, Micheals D, Sloan A, Hatfield J, Adsay V, Joyrich R, Ullah N, Tobi M. Octreotide

- uptake in intracranial metastasis of pancreatic ductal adenocarcinoma origin in a patient with a prolonged clinical course. *Dig Dis Sci.* 2009;54:188-190.
11. Lemke J, Barth TF, Juchems M, Kapapa T, Henne-Bruns D, Kornmann M. Long-term survival following resection of brain metastases from pancreatic cancer. *Anticancer Res.* 2011;31:4599-4603.
 12. Chiang KC, Yu CC, Chen JR, Huang YT, Huang CC, Yeh CN, Tsai CS, Chen LW, Chen HC, Hsu JT, Wang CH, Chen HY. Oncocytic-type intraductal papillary mucinous neoplasm (IPMN)-derived invasive oncocytic pancreatic carcinoma with brain metastasis - a case report. *World J Surg Oncol.* 2012;10:138. doi: 10.1186/1477-7819-10-138.
 13. Rao R, Sadashiv SK, Goday S, Monga D. An extremely rare case of pancreatic cancer presenting with leptomeningeal carcinomatosis and synchronous intraparenchymal brain metastasis. *Gastrointest Cancer Res.* 2013;6:90-92.
 14. Rajappa P, Margetis K, Wernicke G, Ginter P, Cope W, Sherr DL, Lavi E, Fine RL, Schwartz TH, Bruckner H, Pannullo SC. Stereotactic radiosurgery plays a critical role in enhancing long-term survival in a patient with pancreatic cancer metastatic to the brain. *Anticancer Res.* 2013;33:3899-3903.
 15. Kumar A, Dagar M, Herman J, Iacobuzio-Donahue C, Laheru D. CNS involvement in pancreatic adenocarcinoma: a report of eight cases from the Johns Hopkins Hospital and review of literature.

J Gastrointest Cancer. 2015;46:5-8.

16. Matsumoto H, Yoshida Y. Brain metastasis from pancreatic cancer: A case report and literature review. *Asian J Neurosurg.* 2015;10:35-39.

ACCEPTED MANUSCRIPT

Table 1. Summary of reported cases of brain metastasis from pancreatic adenocarcinoma

Authors	Age (y)/sex	Cyst or solid	Intratumoral hemorrhage	Therapy for brain metastasis	Other metastatic lesions	Interval* (mo)	Survival after BM diagnosis
Single metastatic lesion							
Kuratsu et al. ⁷	56/M	Cyst	-	Biopsy, Ommaya reservoir placement, radiation	LN	15	9 mo
	58/M	Solid	-	Resection	Liver	5	2 w
Park et al. ³	51/M	Cyst	-	BSC	Lung, liver, bone	0	2.9 ± 1.0 mo
	52/M	Solid	-	Radiation	Liver	5	2.9 ± 1.0 mo
Caricato et al. ⁹	67/M	Solid	-	Resection	LN	24	12 mo
Marepaily et al. ¹⁰	36/F	NA	-	Resection	Liver	11	BSC, NA
Lemke et al. ¹¹	48/F	NA	-	Resection, radiation	Liver	65	139 mo
	66/M	Solid	-	Resection, radiation	LN	12	72 mo
Chiang et al. ¹²	54/M	Cyst	-	Resection, radiation	-	0	20 mo
Rajappa et al. ¹⁴	67/M	Cyst	-	Resection, radiation	Liver	48	36 mo
Kumar et al. ¹⁵	61.5 (49–70)/NA	Solid	-	Resection	-	13	108 mo
	61.5 (49–70)/NA	Solid	-	Radiation	Lung	43	NA
Matsumoto and Yoshida ¹⁶	68/M	Cyst	-	Resection	LN	0	3 mo
Multiple metastatic lesions							
Park et al. ³	48/M	Solid	-	Radiation	Lung	4	2.9 ± 1.0 mo
	62/M	Cyst	-	BSC	Lung	0	2.9 ± 1.0 mo
Kamar et al. ⁸	56/M	Solid	+	Biopsy	Liver, LN	6	4 d
Rao et al. ¹³	57/M	Solid	-	Radiation	Lung, liver, bone,	0	BSC, NA
Kumar et al. ¹⁵	61.5 (49–70)/NA	NA	-	Resection, radiation	-	22	NA

	61.5 (49–70)/NA	NA	-	Radiation	Liver, bone	2	NA
	61.5 (49–70)/NA	NA	-	NA	Liver, bone	2	NA
	61.5 (49–70)/NA	Cyst	-	NA	LN, lung	57	NA
Present case	61/F	Solid	+	Resection, BSC	Lung, liver, peritoneal dissemination	16	3 w

*Interval between diagnosis of pancreatic adenocarcinoma and diagnosis of the metastatic brain tumor. BM, brain metastasis; BSC, best supportive care; d, days; F, female; LN, lymph node; M, male; mo, months; NA, not available; w, weeks

Figure 1

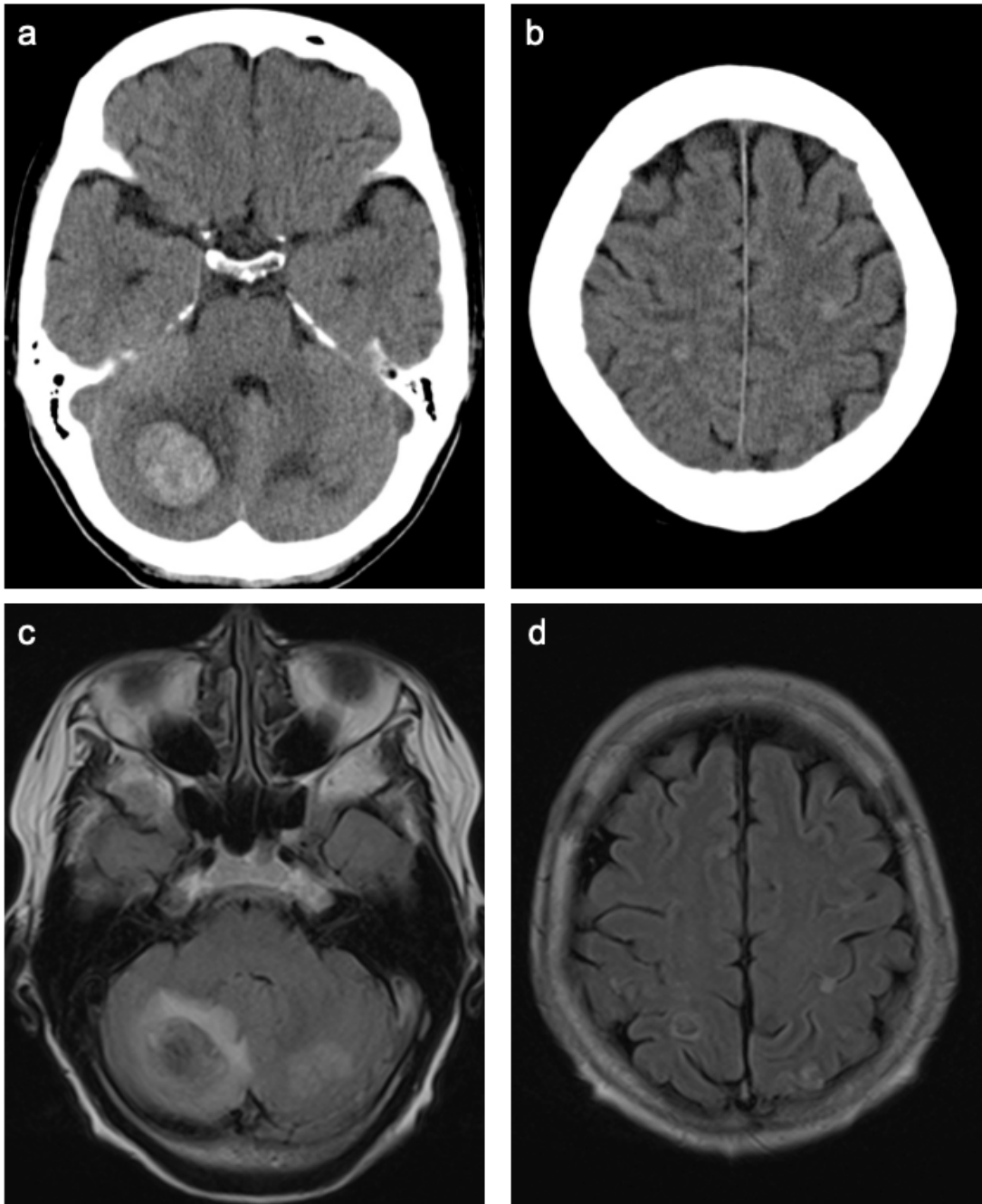


Figure 2

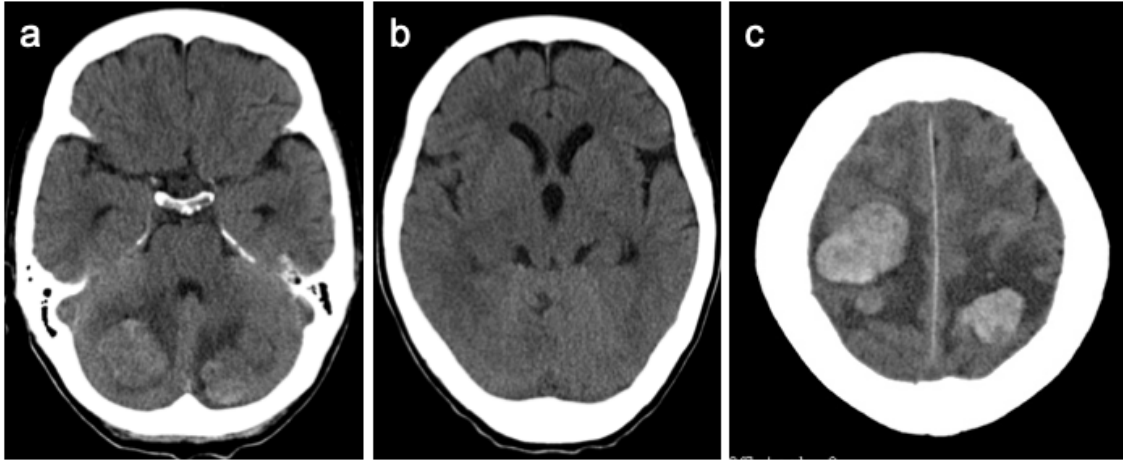


Figure 3

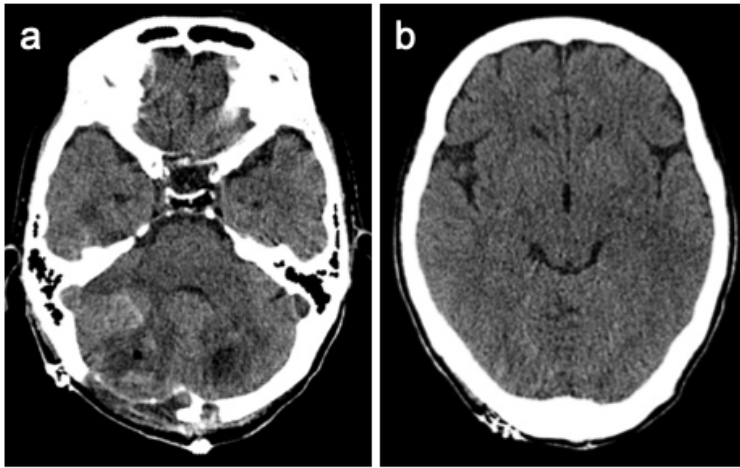


Figure 4

