



Published in final edited form as:

Neurologist. 2019 January ; 24(1): 37–39. doi:10.1097/NRL.000000000000208.

Rare Phenomenon of Limb-shaking TIA, Resolved With Intracranial Wingspan Stenting

Tamra Ranasinghe, MD*, SoHyun Boo, MD†, and Amelia Adcock, MD*

* Department of Neurology, West Virginia University, Morgantown, WV

† Department of Radiology, West Virginia University, Morgantown, WV.

Abstract

Objective: Illustrates the importance of differentiating limb-shaking transient ischemic attack (LS-TIA) from focal seizures and carefully selecting patients for intracranial stenting.

Background: LS-TIA is associated with severe carotid stenosis or occlusion, often precipitated by cerebral hypoperfusion. A case study of 313 patients with symptomatic intracranial artery stenosis/occlusion reported 11% with LS-TIA. In our literature search, we did not find any other cases of successful treatment of LS-TIA with an intracranial Wingspan stent.

Design/Methods: A 66-year-old woman with a history of atrial fibrillation on anticoagulation, hypertension, hyperlipidemia and left middle cerebral artery (MCA) stroke followed by a left internal carotid artery (ICA) endarterectomy presented with transient repetitive involuntary movements (TRIMs) over her right upper and lower limbs. She described episodes of numbness followed by TRIMs over the right side of her body lasting for 1 to 2 minutes. TRIMs occurred only while standing and usually resolved on sitting or lying down.

Results: Conventional angiogram showed severe stenosis of left supraclinoid ICA and proximal MCA. Brain single photon emission computed tomography scan showed impaired vascular reserve in the left MCA territory. An ambulatory electroencephalogram captured TRIMs without epileptiform discharges. She continued to have symptoms with no improvement over a period of 3 months on maximal medical management. She underwent successful endovascular treatment with the Wingspan stent system in the left M1 segment and terminal ICA. Following the revascularization procedure, her symptoms resolved.

Conclusions: It is vitally important to differentiate LS-TIA from focal seizures. This is the first documented case report of complete resolution of LS-TIA symptoms following an intracranial Wingspan stenting.

Keywords

stroke; limb-shaking TIA; intracranial stenting

Correspondence to: Tamra Ranasinghe, MD, Department of Neurology, West Virginia University, Morgantown, WV 26506., tamrar@gmail.com.

The authors declare no conflict of interest.

CASE REPORT

A 66-year-old woman with a history of paroxysmal atrial fibrillation on anticoagulation, hypertension, hyperlipidemia, former smoker, and left middle cerebral artery (MCA) stroke followed by a left carotid endarterectomy presented with transient repetitive involuntary movements (TRIMs) of her right upper and lower limbs. Following her initial left MCA stroke, she recovered much of her strength and sensation with rehabilitation. She did have some mild residual expressive aphasia. The repetitive stereotyped spells affecting her right hemi-body began 5 months following her left MCA stroke. She described episodes of numbness followed by TRIMs over the right side of her body along with dystonic right foot posturing lasting for 1 to 2 minutes. She denied loss of consciousness, bowel bladder incontinence, or postepisode confusion. TRIMs occurred multiple times per day hindering her activities of daily living. She noticed that her symptoms occurred only while standing and usually resolved on sitting or lying down.

CT angiogram showed a short segment of stenosis of the mid right MCA and a long segment of severe stenosis involving the left supraclinoid internal carotid artery (ICA), proximal M1 and anterior cerebral artery (Fig. 1). Brain single photon emission computed tomography scan performed before and after IV administration of 1 g Acetazolamide (Diamox) showed an asymmetric decreased perfusion in the left frontal, parietal, and central regions on both pre-Diamox and post-Diamox images. In addition, on post-Diamox scanning, there was further worsening of perfusion in the left parietal and central regions indicating impaired vascular reserve. A 48-hour ambulatory electro-encephalogram captured 2 TRIMs without corresponding epileptiform discharges or seizures. A single lead EKG performed throughout the tracing showed normal sinus rhythm. During the events, her blood pressure (BP) readings were noted to be low-normal (110 mm Hg) and her antihypertensive medications were tailored to a target BP of 140/80 mm Hg. Although this modification modestly reduced the frequency of TRIMs, she continued to experience daily events that significantly impeded her activities of daily living.

Symptoms persisted with no improvement over a period of 3 months on maximal medical management (aspirin 81 mg/d, plavix 75 mg/d, atorvastatin 80 mg/d, and apixaban 5 mg twice daily). BP were well-controlled; low density lipoprotein was 127; hemoglobin, A1c 6.6; body mass index of 25.25. After an extensive discussion regarding management options, including continuing medical management and extracranial-intracranial (EC-IC) bypass surgery, the patient elected to proceed with an intracranial stent placement.

Diagnostic cerebral angiogram showed ~98% stenosis of the terminal ICA, A1, and M1 segments. Following this, balloon angioplasty using a 1.5 mm Gateway balloon (Stryker Neurovascular, Fremont, CA) was performed across the terminal ICA/M1 segment. While preserving microwire access, the balloon was exchanged off for a 3 mm×20mm Wingspan self-expanding stent (Stryker Neurovascular). The stent covered the stenosis from the terminal ICA to the distal M1 segment. There was <20% residual stenosis with preserved flow across the anterior choroidal and posterior communicating artery.

Following the successful revascularization procedure for her symptomatic intracranial atherosclerotic disease (ICAD) in the left M1 segment MCA and terminal ICA (Fig. 2), her symptoms resolved.

DISCUSSION

Limb-shaking transient ischemic attack (LS-TIA) is associated with severe carotid stenosis or occlusion, often precipitated by cerebral hypoperfusion.¹ A case study of 313 patients with symptomatic intracranial artery stenosis/occlusion reported 11% with LS-TIA.² This indicates LS-TIA may be more common than generally reported. If not carefully evaluated it can be mistaken for seizures.³ As in this case, there was a high suspicion for epileptiform etiology with known prior left MCA stroke serving as a cortical substrate. However, the electroencephalogram did not capture any epileptiform discharges during her symptoms.

We believe our patient's right-sided TRIMs were symptomatic TIAs precipitated by cerebral hypoperfusion in the setting of severe intracranial stenosis over the left ICA and MCA. Symptomatic LS-TIA episodes have been reported due to decreased cerebral perfusion in the setting of antihypertensive medications⁴ and orthostatic hypotension.⁵ Following revascularization with a successful intracranial Wingspan stent placement, our patient continues to remain asymptomatic with complete resolution of her limb-shaking episodes at 12 months postprocedure.

The primary or secondary prevention of large-vessel-atherosclerotic-disease-related cerebrovascular ischemia has long been a matter of debate. A large randomized trial organized by the EC-IC Bypass Study Group failed to show a reduction in recurrent stroke in carotid occlusive disease with revascularization achieved via surgical bypass.⁶ However, uncertainty remained in patients with objective evidence of hemispheric hypoperfusion. The Carotid Occlusion Surgery Study (COSS) targeted patients with symptomatic carotid occlusion and evidence on positron emission tomography of increased oxygen extraction ipsilateral to the occlusion, a marker of hemodynamic cerebral ischemia. Participants were randomized to optimal medical therapy with or without EC-IC surgery. The study was prematurely terminated for futility with the composite outcome of 30-day ipsilateral stroke/mortality or 2-year ipsilateral stroke rate of ~20% in both surgical and medical arms.⁷ Notably, the majority of events occurred in the perioperative period. The long-term stroke rate more than doubled in the nonsurgical group when considering all events 2 or more days postprocedure (22.7% vs. 9.0%). Many variables including indirect versus direct bypass approaches, complexity of anatomy, hemodynamic fragility, and ischemic preconditioning are potential determinants of an individual patient's outcome.⁸ Furthermore, it is important to note that most of these patients had culprit disease isolated to their extracranial internal carotid arteries as opposed to MCA or tandem ICA-MCA stenoses. A trial randomizing 77 of these latter type of patients showed a significant and persistent benefit in reducing ipsilateral ischemic stroke. During a follow-up period close to 3 years, 13% in the surgical arm (superficial temporal artery—MCA bypass) compared with 45% of the medically treated patients experienced cerebrovascular ischemia ($P=0.008$).⁹

There are no management guidelines or protocols published on specific treatment for LS-TIA. Small observational study of patient with LS-TIA have showed successful surgical reperfusion with either carotid endarterectomy or EC-IC bypass.¹⁰ To the best of our knowledge, we are not aware of any other cases of successful treatment of LS-TIA with an intracranial Wingspan stent. In light of the SAMMPRIS trial,¹¹ endovascular treatment of ICAD has been reserved for those failing maximum medical management. Conversely, trying to replicate the maximum medical goals of SAMMPRIS proves to be clinically difficult to achieve in the typical practice. To date, the Wingspan stent system is the only Food and Drug Administration-approved device for ICAD.¹² The risk to benefit profile must be carefully discussed when deciding treatment for such a rare phenomenon of LS-TIA.

In neurology clinical practice, stroke is conceptualized to present with “negative” symptoms while seizure to present with “positive” symptoms. Hence it is vitally important to differentiate and diagnose LS-TIA from focal seizures. This case report illustrates the existence of a rare phenomenon and highlights the importance of its timely diagnosis for secondary stroke prevention. Further prospective studies and longer follow-up data of patients treated with intracranial stenting for LS-TIA would be beneficial in the future.

REFERENCES

1. Ali S, Khan MA, Khealani B. Limb-shaking transient ischemic attacks: case report and review of literature. *BMC Neurol.* 2006;6:5. [PubMed: 16438706]
2. Persoon S, Kappelle LJ, Klijn CJ, et al. Limb-shaking transient ischemic attacks in patients with internal carotid artery occlusion: a case-control study. *Brain.* 2010;133:915–922. [PubMed: 20157011]
3. Fisch BJ, Tatemichi TK, Prohovnik I, et al. Transient ischemic attacks resembling simple partial motor seizures (abstract). *Neurology.* 1988;38(suppl 1):264.
4. Leira EC, Ajax T, Adams HP, Jr. Limb-shaking carotid transient ischemic attacks successfully treated with modification of the antihypertensive regimen. *Arch Neurol.* 1997;54:904–905. [PubMed: 9236580]
5. Zaidat OO, Werz MA, Landis DM, et al. Orthostatic limb shaking from carotid hypoperfusion. *Neurology.* 1999;53:650–651. [PubMed: 10449141]
6. Extracranial/Intracranial (EC/IC) Bypass Study Group. Failure of extracranial-intracranial arterial bypass to reduce the risk of ischemic stroke. Results of an international randomized trial. *N Engl J Med.* 1985;313:1191–1200. [PubMed: 2865674]
7. Grubb RL, Jr, Powers WJ, Clarke WR, et al. Surgical results of the Carotid Occlusion Surgery Study. *J Neurosurg.* 2013;118:25–33. [PubMed: 23101451]
8. Reynolds MR, Grubb RL, Jr, Clarke WR, et al. Investigating the mechanisms of perioperative ischemic stroke in the Carotid Occlusion Surgery Study. *J Neurosurg.* 2013;119:988–995. [PubMed: 23909253]
9. Low SW, Teo K, Lwin S, et al. Improvement in cerebral hemodynamic parameters and outcomes after superficial temporal artery-middle cerebral artery bypass in patients with severe stenocclusive disease of the intracranial internal carotid or middle cerebral arteries. *J Neurosurg.* 2015;123:662–669. [PubMed: 26023999]
10. Yanagihara T, Piegras DG, Klass DW. Repetitive involuntary movement associated with episodic cerebral ischemia. *Ann Neurol.* 1985;18:244–250. [PubMed: 3929672]
11. Derdeyn CP, Chimowitz MI, Lynn MJ, et al. Aggressive medical treatment with or without stenting in high-risk patients with intracranial artery stenosis (SAMMPRIS): the final results of a randomized trial. *Lancet.* 2014;383:333–341. [PubMed: 24168957]

12. Zaidat OO, Klucznik R, Alexander MJ, et al. The NIH registry on use of the Wingspan stent for symptomatic 70–99% intracranial arterial stenosis. *Neurology*. 2008;70:1518–1524. [PubMed: 18235078]

Author Manuscript

Author Manuscript

Author Manuscript

Author Manuscript

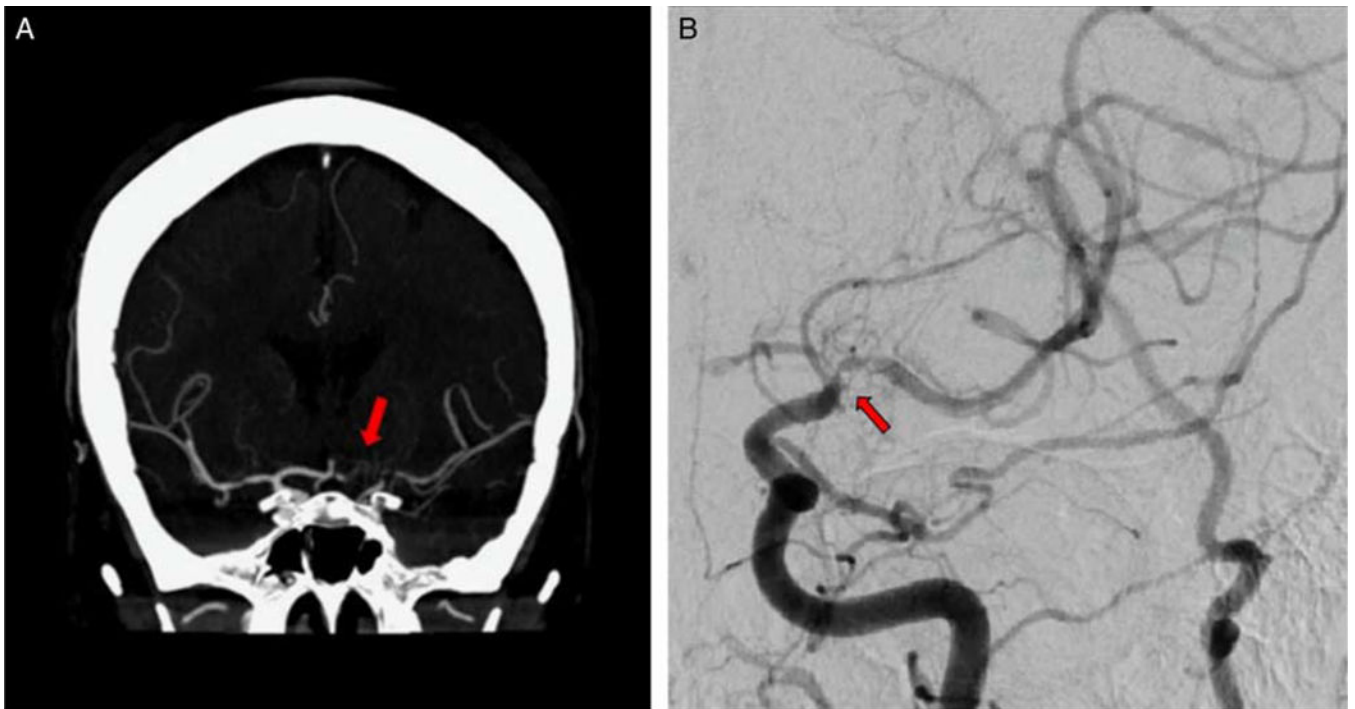


FIGURE 1.

Computed tomographic angiogram (A) and cerebral angiogram (B) show a long segment of severe intracranial atherosclerosis disease (arrow) involving the supraclinoid internal carotid artery and middle cerebral artery.

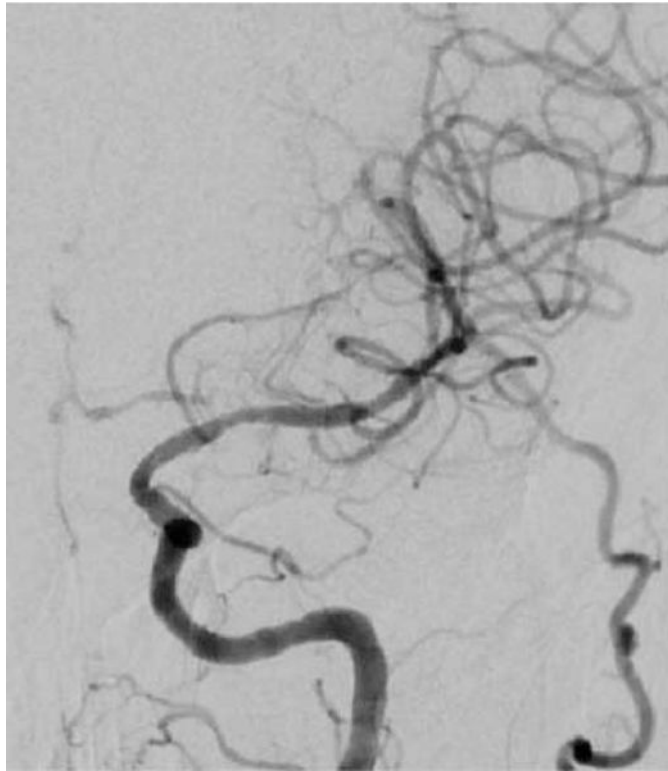


FIGURE 2. Following endovascular balloon angioplasty and wingspan stenting of the left M1 segment of middle cerebral artery and terminal internal carotid artery.