

Clinical Reasoning: A 14-year-old girl with headache, seizures, and confusion

Lijun Xiao, MD, Wenping Gu, MD, PhD, Bin Jiao, MD, PhD, Yunhai Liu, MD, PhD, and Xiaosu Yang, MD, PhD

Neurology® 2019;92:e161-e167. doi:10.1212/WNL.0000000000006726

Correspondence

Dr. Gu

Guwenping393@sohu.com

Section 1

A 14-year-old girl without any relevant medical history was transferred to our institution due to worsening headache along with nausea, vomiting, and generalized tonic-clonic (GTC) seizures for 7 days. She was also noted to have multiple psychological and behavioral abnormalities for 1 day. Her headache was described as severe holocephalic pain aggravated when lying down and alleviated after vomiting. No throbbing or phonophobia/photophobia was observed. Her seizures occurred once or twice a day, lasting about 1 minute each and resolving spontaneously. Symptoms were refractory to rotundine (dopamine D1 receptor antagonist), azasetron (antiemetic), mannitol, oxcarbazepine, and phenobarbital.

Psychological and behavioral abnormalities were noted including singing, raving, crying, and laughing intermittently. On physical examination, exotropia, hyperpigmentation of the skin, and long fingers were observed. On neurologic examination, the patient was unable to follow commands but responded to noxious stimuli. Funduscopic examination revealed papilledema. Plantar responses were extensor bilaterally.

D-dimer was high (2.72 mg/L, normal <0.5 mg/L), which suggested hypercoagulation and thrombogenesis. CT of head and intracranial arteries showed cerebral infarction and subarachnoid hemorrhage (figure 1, A) without arterial aneurysm or vascular malformation. Lumbar puncture revealed an opening pressure that was elevated at 300 mm of water, elevated red blood cells (>1,000 cells/mm³), and elevated white blood cells (about 20 cells/mm³). CSF glucose, chloride, and protein were normal.

A continuous EEG showed diffuse background slowing with epileptiform discharges including frequent spikes and sharp waves present over the bilateral frontal and temporal regions. CT venography (CTV) revealed cerebral venous sinus thrombosis (CVST) with filling defects of the sigmoid and right lateral sinuses (figure 1, B). There was no family history of headache, epilepsy, or CVST.

Question for consideration:

1. What is the cause of the patient's CVST?

GO TO SECTION 2

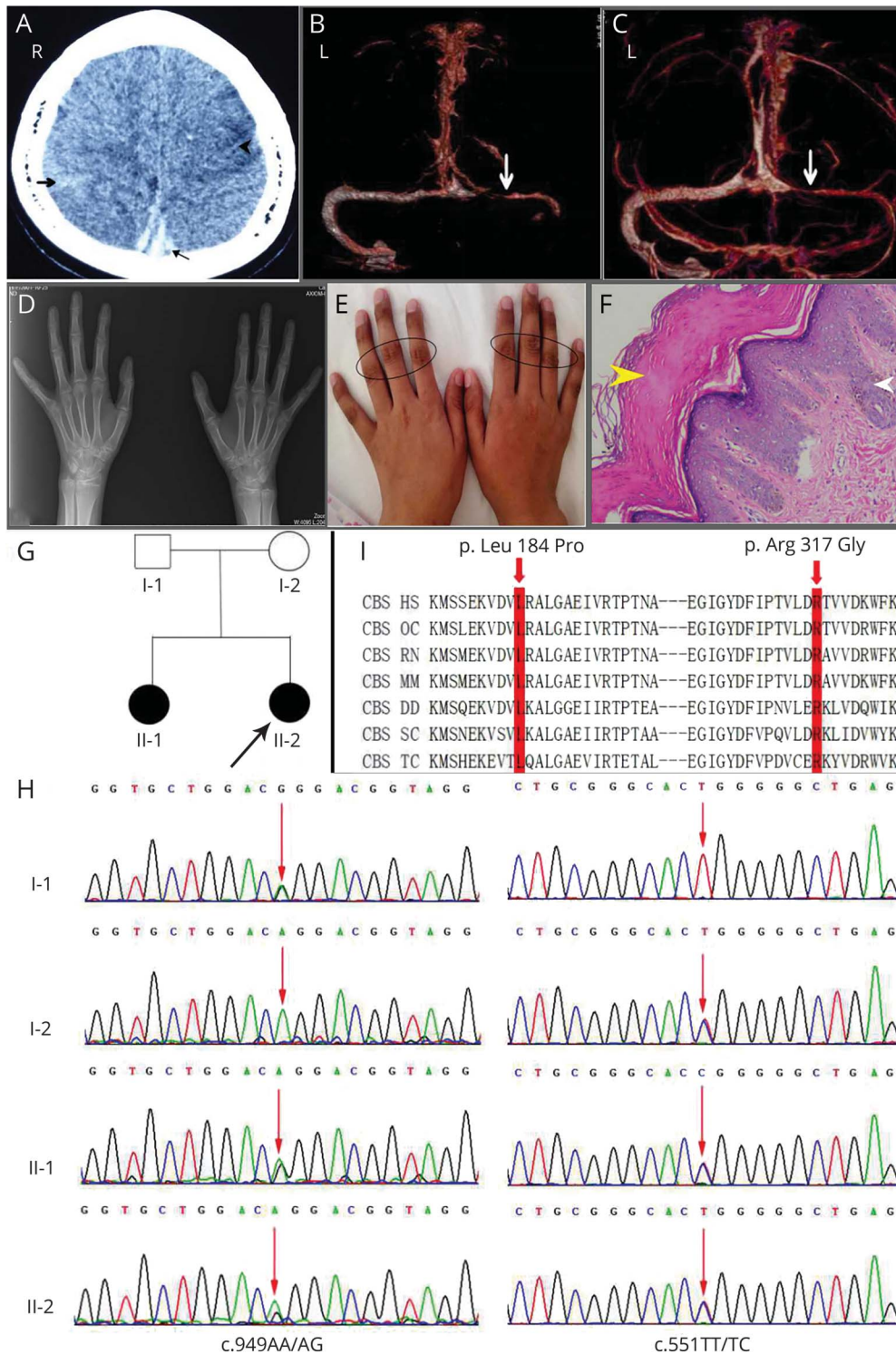
From the Department of Neurology, Xiangya Hospital, Central South University, Hunan, China.

Go to [Neurology.org/N](https://www.neurology.org/N) for full disclosures. Funding information and disclosures deemed relevant by the authors, if any, are provided at the end of the article.

Copyright © 2019 American Academy of Neurology

Copyright © 2019 American Academy of Neurology. Unauthorized reproduction of this article is prohibited.

Figure 1 Images of the reported case



(A) Brain CT shows cerebral infarction (triangle), subarachnoid hemorrhage (bold arrow), and thrombus of superior sagittal sinus (thin arrow). (B) CT venography (CTV) reveals cerebral venous sinus thrombosis (CVST) with filling defect of the right sigmoid sinus and right lateral sinuses (white arrow). (C) CTV after a month of treatment; the right sigmoid sinus and right lateral sinuses unobstructed but narrowed (white arrow). (D) X-ray suggests that joint space of bilateral wrist was narrowed. (E) The patient's long fingers. The circles show hyperpigmentation of skin, especially in the interphalangeal joints. (F) Histopathologic study of the patient's slightly darker skin reveals hyperkeratosis (yellow arrowhead) and verrucous hyperplasia in the basal layer of the epidermis (white arrowhead) (magnified 10 × 10 times under the microscope). (G) Pedigree of the family with homocystinuria. (H) Gene direct sequencing identified 2 novel compound heterozygous mutations: c.551T>C (p.L184P) and c.949A>G (p.R317G) (indicated by the red arrow). I-1: Heterozygous mutations of c.949A>G, the c.551 TT is normal; I-2: heterozygous mutations of c.551T>C, the c.949AA is normal; II-1, II-2: compound heterozygous mutations of c.551T>C and c.949A>G. (I) Orthologous protein sequence alignment of cystathionine β-synthase from different species. The mutated residue showing conservation is shaded in red. Red shaded amino acids proteins show that the 2 novel missense mutations occurred at highly conserved positions in these species. DD = *Dictyostelium discoideum*; HS = *Homo sapiens*; MM = *Mus musculus*; OC = *Oryctolagus cuniculus*; RN = *Rattus norvegicus*, splice isoform III; SC = *Saccharomyces cerevisiae*; TC = *Trypanosoma cruzi*.

Section 2

The primary cause for CVST is usually hypercoagulability due to acquired and genetic risks (table 1).¹ The patient had no evidence of common risks in table 1 such as infection, vitamin deficiency, abnormal protein C or protein S, estrogen-related factors, or others. However, she did have high level of plasma total homocysteine (Hcy) (149.40 $\mu\text{mol/L}$, normal $<15 \mu\text{mol/L}$).

Hcy causes approximately 4.5% of cases of CVST.² It is a nonessential but indispensable sulfur-containing amino acid in humans. Hcy levels in the bloodstream can rise in 3 different ways³: (1) protein structure modifications; (2) oxidative stress induction; and (3) excitotoxicity. Hyperhomocysteinemia (HHcy) can lead to CVST and thromboembolism⁴ by causing prothrombotic conditions, endothelial dysfunction, and impaired thrombolysis. HHcy can also result in multisystem damage⁵ (table 2) by the 3 main pathways mentioned above.³

Table 1 Causes of cerebral venous sinus thrombosis

Acquired risks	Genetic risks
Connective tissue disease	The prothrombin G20210A mutation
Hematologic system diseases	Factor V Leiden gene mutations
Infections	Protein C, protein S, and antithrombin III deficiencies
Cancer	Genes associated with homocysteine metabolism
Pregnancy and puerperium	Others
Surgery, trauma, and other mechanical precipitants	Unidentified
Exogenous hormones	
Drug-associated conditions	
Acquired HHcy	
Unidentified	

Abbreviation: HHcy = hyperhomocysteinemia.

Table 2 Multiple target organs or systems damage caused by hyperhomocysteinemia reported in the literature and the 2 patients

Target organs/ systems	Clinical characteristics reported in the literature	II-1 (older sister)	II-2 (proband)
Eye	Ectopia lentis, exotropia, or severe myopia	Congenital binocular ectopia lentis, impaired vision	Congenital binocular ectopia lentis, exotropia, impaired vision
Skeleton	Dolichostenomelia and arachnodactyly, osteoporosis and higher risk of fractures, bone deformities	Long fingers, kyphoscoliosis	Long fingers, the physiologic curvature of thoracic vertebra straightened, narrowed joint space of bilateral wrist, osteoporosis, decreased BMD (values -3.3)
Skin (not common)	Light skin and brittle red to blond hair, malar flush	Not found	Hyperpigmentation, especially in the interphalangeal joints, histopathologic study revealed hyperpigmentation, hyperkeratosis, verrucous hyperplasia in the basal layer of the epidermis
CNS	Intellectual disability, psychiatric and behavioral problems, seizures, and extrapyramidal sign	Psychological and behavioral abnormalities, irascibility, intellectual disability, ataxia, unstable gait	Intellectual disability, scored 70 on WISC-IV, 25 of 30 on MMSE, 17 of 30 on MoCA, psychological and behavioral abnormalities, low self-learning ability
Vascular system	Venous or arterial thromboembolism	Not found	Cerebral venous sinus thrombosis
Others	Congenital defects including congenital heart defect and neural tube defect	Not found	EMG, ECG, cardiac color ultrasound, peripheral artery and peripheral venous examinations all normal

Abbreviations: BMD = bone mineral density (value below -2.5 means higher risk of fractures); MMSE = Mini-Mental State Examination; MoCA = Montreal Cognitive Assessment; WISC-IV = Wechsler Intelligence Scale for Children, 4th edition.

In this case, the patient had CVST and multisystem dysfunction due to HHcy (table 2), including ocular anomalies, skeletal system deformities (figure 1, D), skin diseases (figure 1, E and F), and CNS abnormalities.

Questions for consideration:

1. What are the common causes of HHcy?
2. How can we confirm the root cause of HHcy in our patient?

GO TO SECTION 3

Section 3

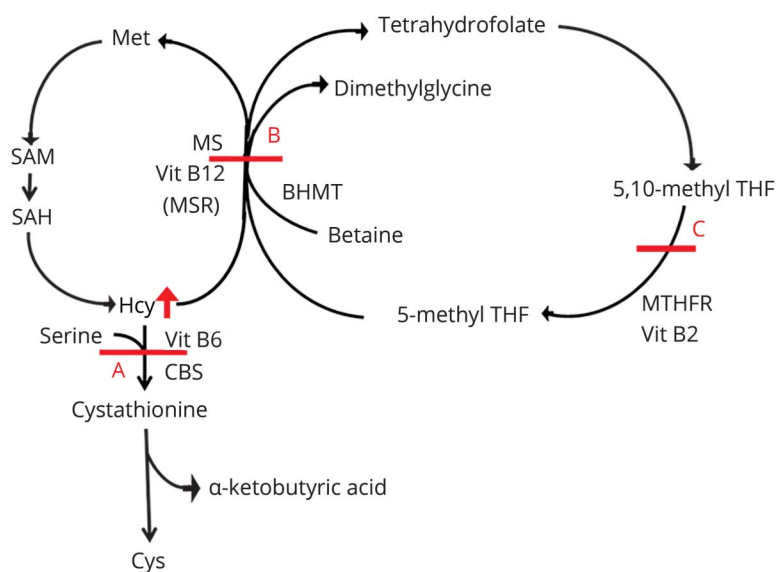
The common causes for HHcy can be divided into exogenous factors such as overintake of cysteine (Cys) or methionine (Met) or dietary deficiencies of vitamins B₆, B₁₂, or folate⁶ (figure 2). Exogenous factors of HHcy were considered unlikely—there was no history of dietary restrictions or overuse of vitamins. However, the patient's older sister (II-1 in the pedigree of figure 1G) also had multiple medical problems (table 2). Thus, the patient's HHcy may have been due to inherited factors, which tend to be a considerable cause of HHcy.

For our patient, we first screened for common genetic defects and biochemical abnormalities. Investigations revealed elevated plasma Met (437.77 μmol/L) without a normal level of methylmalonic acid on plasma aminoacid chromatography. These results were consistent with cystathionine

β-synthase (CBS) and methylenetetrahydrofolate reductase (MTHFR) deficiency⁶ (table 3).

To confirm the diagnosis,⁷ an experimental study was conducted using all exons of CBS and MTHFR genes in the pedigree (figure 1, G). We found novel compound heterozygous mutations of the CBS gene, c.551T>C (p.leucine 184 proline) and c.949A>G (p.arginine 317 glycine) (figure 1, H), which were coseparated and predicted as damaged and possibly damaged according to SIFT (sift.jcvi.org/) and PolyPhen (genetics.bwh.harvard.edu/pph2/). Interestingly, the 2 novel mutations occurred at highly conserved positions across different species (figure 1, I). To our knowledge, this is the first time this has been reported in the literature, including from the National Heart Blood and Lung Institute Exome Sequencing Project, 1000 Genomes Project, or the Single Nucleotide Polymorphism Database, and 50 healthy controls from

Figure 2 The biochemical metabolism of homocysteine (Hcy)



(A) Hcy and serine can transfer to cystathionine, and the reactions are catalyzed by vitamin B₆ and cystathionine β-synthase (CBS) resynthesis. (B) Remethylation to methionine of Hcy pathways. Vitamin B₁₂, betaine, and betaine homocysteine methyltransferase (BHMT) are independent. (C) In the cycle of methylenetetrahydrofolate (THF), vitamin B₂ and methylenetetrahydrofolate reductase (MTHFR) are indispensable. Cys = cysteine; Met = methionine; MS = methionine synthase; MSR = methionine synthase reductase; SAM = S-adenosyl methionine; SAH = S-adenosyl homocysteine.

Table 3 Different genes/proteins deficiency causing different variations of organic acids

Genes deficiency	Protein	Hcy (normal 15 μmol/L)	Met (normal 50 μmol/L)	MMA (normal < 4 μmol/L)
Methionine synthase	MS	↑	↓	—
Methionine synthase reductase	MSR	↑	↓	—
Cystathionine β-synthase	CBS	↑	↑	—
Methylenetetrahydrofolate reductase	MTHFR	↑	↑	—
Genes deficiency associated with cobalamin (MMACHC, ¹ MMADHC, ² ABCD4, ³ HCFC1 ⁴)	Protein associated with cobalamin	↑	—	↑

Abbreviations: ABCD4 = ATP-binding cassette-D4; HCFC1 = host cell factor c-1; MMACHC = methylmalonic acid homocystinuria type C protein; MMADHC = methylmalonic acid homocystinuria type D protein.

China origin (supplemental information, doi.org/10.5061/dryad.6cc5h8f).

Whole-exome sequencing bioinformatics was performed and confirmed that there were no other potential associated genes mutation in this pedigree. Therefore, these results indicate that the compound heterozygous mutations of CBS gene,

c.551T>C and c.949A>G, which have not been previously reported, had a strong relationship with homocystinuria in this pedigree.

Question for consideration:

1. What is the next step in management? How should one treat the CVST? How should one treat the HHcy?

GO TO SECTION 4

Section 4

For CVST, low-molecular-weight heparin was given to the patient followed by oral anticoagulants.² For HHcy, the current treatment strategies primarily focus on correcting the biochemical abnormalities with supplementation of vitamin B₆ (100–200 mg/d), folate (5 mg/d), and vitamin B₁₂ (5 mg/d), along with a Met and Cys restricted diet.⁸ Betaine is another possible treatment for these patients as it provides an alternate remethylation pathway to convert excess Hcy to Met (figure 2), especially in patients who could not achieve target levels of Hcy by other means.⁸

One month later, the CTV image showed that the previously obstructed sinuses were unobstructed but narrowed (figure 1, C). Three months later, the patient attended school, as her learning ability and behavior had improved. After a year, the patient had no further thrombotic events and a normal tHcy. In addition, the patient was counseled about birth control and avoiding estrogen-containing contraceptives, which may increase risk of thrombosis including CVST.¹ If the patient were to have a future pregnancy, prophylactic anticoagulation with low-molecular-weight heparin would be recommended postpartum and during the third trimester to reduce the risk of thromboembolism.⁸

Discussion

We report a case of CVST due to homocystinuria. Homocystinuria due to CBS deficiency (OMIM #236200) is a rare disorder of sulfur amino acid metabolism, with elevated plasma concentrations of tHcy and Met and increased excretion of Hcy in urine.⁹ So far, at least 164 mutations in CBS have been reported (cbs.lf1.cuni.cz/index.php). In our case, novel compound heterozygous pathogenic mutations of CBS, c.551T>C and c.949A>G, led to HHcy causing CVST and multiple system dysfunction, skin hyperpigmentation, and straightened vertebra.

The case expands the phenotypes and mutation spectrum of CBS resulting in homocystinuria. This discovery is helpful in presymptomatic molecular diagnosis, prenatal diagnosis, management of patients with homocystinuria, and genetic counseling of families. The treatment management and corresponding prognosis indicate that early diagnosis, early prevention, and early treatment are beneficial to prognosis. Gene detection technique is of great value to diagnose disease and to find the new gene mutation in clinical genopathy and it should be widely used in clinical practice.

This case also highlights that (1) for CVST in young patients without common risk factors, HHcy is a possible cause; and (2) for patients with HHcy, once exogenous factors of HHcy are ruled out, genetic testing should be done, especially if there is evidence of multiorgan dysfunction or a strong family history.

Author contributions

Lijun Xiao: study design, acquisition of clinical data, analysis of data, drafting the manuscript. Wenping Gu: study concept and design, analysis of data, revising the manuscript. Bin Jiao: statistical analysis, drafting the manuscript. Yunhai Liu: acquisition of clinical data, study supervision. Xiaosu Yang: study concept and design, analysis of data.

Acknowledgment

JiFeng Guo, MD, PhD (Xiangya Hospital) provided general advice or guidance and reviewed the manuscript. Jun Yin, MD, PhD (Xiangya Hospital) and Long Luo, MD (Xiangya Hospital) offered technical help. Rui Yang, MD, PhD (Xiangya Hospital) reviewed the manuscript.

Study funding

No targeted funding reported.

Disclosure

L. Xiao, W. Gu, and B. Jiao report no disclosures relevant to the manuscript. Y. Liu received funding from China Ministries of Health. X. Yang received honoraria from the Department of Science and Technology of Hunan province. Go to Neurology.org/N for full disclosures.

References

1. Behrouzi R, Punter M. Diagnosis and management of cerebral venous thrombosis. *Clin Med* 2018;18:75–79.
2. Saposnik G, Barinagarrementeria F, Brown RD, et al. Diagnosis and management of cerebral venous thrombosis. *Stroke* 2011;42:1158–1192.
3. Kumar A, Palfrey HA, Pathak R, et al. The metabolism and significance of homocysteine in nutrition and health. *Nutr Metab* 2017;14:78.
4. Lauw MN, Barco S, Coutinho JM, et al. Cerebral venous thrombosis and thrombophilia: a systematic review and meta-analysis. *Semin Thromb Hemost* 2013;39:913–927.
5. Karaca M, Hismi B, Ozgul RK, et al. High prevalence of cerebral venous sinus thrombosis (CVST) as presentation of cystathionine beta-synthase deficiency in childhood: molecular and clinical findings of Turkish probands. *Gene* 2014;534:197–203.
6. Nazki FH, Sameer AS, Ganaie BA. Folate: metabolism, genes, polymorphisms and the associated diseases. *Gene* 2014;533:11–20.
7. Jiao B, Guo J, Wang Y, et al. C9orf72 mutation is rare in Alzheimer's disease, Parkinson's disease, and essential tremor in China. *Front Cell Neurosci* 2013;7:164.
8. Kumar T, Sharma GS, Singh LR. Homocystinuria: therapeutic approach. *Clinica Chim Acta* 2016;458:55–62.
9. Brenton DP, Dow CJ, James JJ, et al. Homocystinuria and Marfan's syndrome: a comparison. *J Bone Joint Surg Br* 1972;54:277–298.

Neurology®

Clinical Reasoning: A 14-year-old girl with headache, seizures, and confusion

Lijun Xiao, Wenping Gu, Bin Jiao, et al.

Neurology 2019;92:e161-e167

DOI 10.1212/WNL.0000000000006726

This information is current as of January 7, 2019

Updated Information & Services	including high resolution figures, can be found at: http://n.neurology.org/content/92/2/e161.full
References	This article cites 9 articles, 2 of which you can access for free at: http://n.neurology.org/content/92/2/e161.full#ref-list-1
Subspecialty Collections	This article, along with others on similar topics, appears in the following collection(s): Cerebral venous thrombosis http://n.neurology.org/cgi/collection/cerebral_venous_thrombosis Metabolic disease (inherited) http://n.neurology.org/cgi/collection/metabolic_disease_inherited Organic acid http://n.neurology.org/cgi/collection/organic_acid
Permissions & Licensing	Information about reproducing this article in parts (figures, tables) or in its entirety can be found online at: http://www.neurology.org/about/about_the_journal#permissions
Reprints	Information about ordering reprints can be found online: http://n.neurology.org/subscribers/advertise

Neurology® is the official journal of the American Academy of Neurology. Published continuously since 1951, it is now a weekly with 48 issues per year. Copyright © 2019 American Academy of Neurology. All rights reserved. Print ISSN: 0028-3878. Online ISSN: 1526-632X.

