

Reversible Cerebral Vasoconstriction Syndrome after Administering Etanercept during Puerperium

Daisuke Hara, PhD, MD, Saki Nukui, MD, Takahiro Shimizu, PhD, MD, Hisanao Akiyama, PhD, MD, and Yasuhiro Hasegawa, PhD, MD

Our objective is to clarify relationship between reversible cerebral vasoconstriction syndrome and administering etanercept during puerperium. Several lines of evidence have suggested tumor necrosis factor (TNF) as a mediator of vascular dysfunction associated with estrogen deficiency. A 32-year-old woman resumed etanercept (25 mg/week), a TNF inhibitor, which had been discontinued during pregnancy, because of the deterioration of rheumatoid arthritis. She was admitted to our hospital with upper right quadrant blindness and mild right hemiparesis accompanied by pulsating left occipital pain, which had appeared 4 hours after restarting etanercept (25 mg/week). Magnetic resonance imaging and angiography revealed acute left hippocampal infarction with multiple segmental stenoses of the main intracranial arteries. Reversible cerebral vasoconstriction syndrome was diagnosed based on improvement of the multiple stenoses on magnetic resonance angiography on hospital day 17. A causal relationship was considered to exist between TNF inhibition by etanercept and multiple cerebral vasoconstrictions with brain infarct in this puerperant.

Key Words: Reversible cerebral vasoconstriction syndrome—cerebral infarction—puerperium—etanercept—rheumatoid arthritis

© 2018 National Stroke Association. Published by Elsevier Inc. All rights reserved.

Case Report

The patient in this case was a 32-year-old woman with a medical history of rheumatoid arthritis for which she had started treatment with methotrexate 7 years earlier, and migraine. A year before this presentation, methotrexate (6 mg/week) had been changed to etanercept (25 mg/week), a tumor necrosis factor inhibitor (TNFi). Three months later,

all drugs were discontinued when she became pregnant, and she restarted etanercept (25 mg/week) 2 months after giving birth. Four hours after restarting etanercept, she experienced sudden appearance of upper right quarter blindness and mild right hemiparesis accompanied by pulsating left occipital pain, and was admitted to our hospital. Upon arrival, blood pressure, heart rate, and body temperature were 160/90 mm Hg, 98 beats/minute, and 36.4°C, respectively. Blood tests showed: rheumatoid factor was high (119 IU/mL), and no other abnormalities. Magnetic resonance (MR) imaging and MR angiography revealed acute left hippocampal infarction with multiple segmental stenoses of the main intracranial arteries (Fig 1, A-E), and continuous intravenous heparin (400 unit/hour) was administered. On hospital day 2, as the scope of visual disorder expanded, MR imaging revealed hemorrhage at the acute left hippocampal infarction and changes in the locations of multiple segmental stenoses on MR angiography as compared with findings on admission (Fig 1, F). Administration of heparin was therefore discontinued. Cerebrospinal fluid test on hospital day 5 showed no

From the Department of Internal Medicine, Division of Neurology, St. Marianna University of School of Medicine, Yokohama City Seibu Hospital, Yokohama, Kanagawa, Japan.

Received November 2, 2018; revision received November 28, 2018; accepted December 16, 2018.

Address correspondence to Daisuke Hara, PhD, MD, Department of Internal Medicine, Division of Neurology, St. Marianna University School of Medicine, Yokohama City Seibu Hospital, 1197-1, Yashi, Asahi, Yokohama, Kanagawa 241-0811, Japan.

E-mail: spw29zq9@marianna-u.ac.jp.

1052-3057/\$ - see front matter

© 2018 National Stroke Association. Published by Elsevier Inc. All rights reserved.

<https://doi.org/10.1016/j.jstrokecerebrovasdis.2018.12.012>

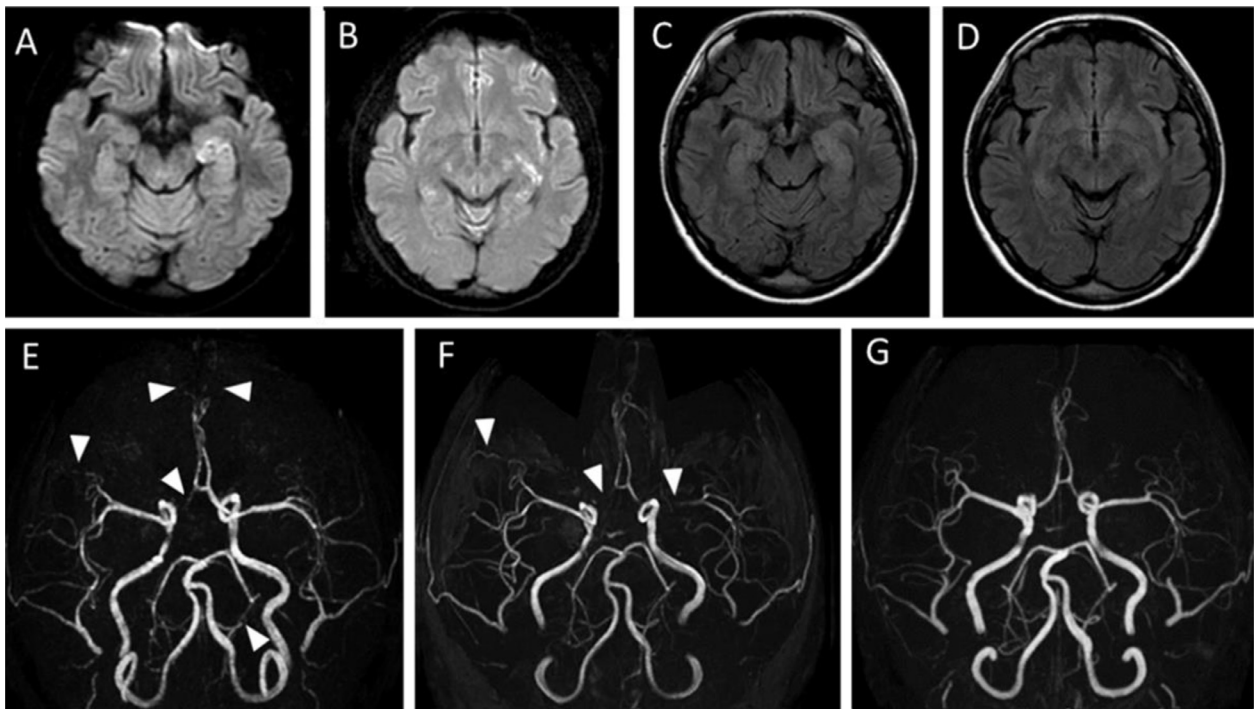


Figure 1. (A-D) MRI of the head (diffusion-weighted images: A, B; FLAIR images: C, D) on admission reveals cerebral infarction in the left hippocampus. (E-H) Magnetic resonance angiography (MRA) reveals reversible multiple vasoconstriction (white arrowhead) (E: day 1, F: day 2, G: day 17 from day of admission). Abbreviation: MRI, magnetic resonance imaging.

abnormal finding, and MR angiography on hospital day 17 revealed improvements in the multiple stenoses (Fig 1, G), confirming reversible cerebral vasoconstriction syndrome (RCVS). The patient was discharged to home on hospital day 19.

Discussion

In this case, RCVS developed immediately after resuming administration of etanercept with estrogen deficiency. Pregnancy, puerperium, and female sex are known risk factors for the onset of RCVS,¹ and are considered to cause RCVS accompanied by changes in estrogen concentrations.^{2,3} Kastrup and Christoph hypothesized that TNFi may increase blood brain barrier permeability through a mechanism of interfering the creatine transporter.⁴ Arenas reported that a decrease in serum bioactive TNF- α following TNFi use results in decreased consumption of nitric oxide, increased modulation of vascular function, and that TNF- α could represent a mediator of vascular dysfunction associated with estrogen deficiency.⁵ In this case, the possibility that the same mechanisms caused RCVS was considered, TNFi administration with estrogen deficiency may increase vascular

reactivity to a greater extent than usual. Accumulation of similar cases is necessary to elucidate the relationship between TNFi administration and RCVS with estrogen deficiency.

References

1. Miller TR, Shivashankar R, Mossa-Basha M, et al. Reversible cerebral vasoconstriction syndrome, part 1: epidemiology, pathogenesis, and clinical course. *AJNR Am J Neuroradiol* 2015;36:1392-1399.
2. Soo Y, Singhal AB, Leung T, et al. Reversible cerebral vasoconstriction syndrome with posterior leukoencephalopathy after oral contraceptive pills. *Cephalalgia* 2010;30:42-45.
3. Freilinger T, Schmidt C, Duering M, et al. Reversible cerebral vasoconstriction syndrome associated with hormone therapy for intrauterine insemination. *Cephalalgia* 2010;30:1127-1132.
4. Kastrup O, Diener HC. TNF-antagonist etanercept induced reversible posterior leukoencephalopathy syndrome. *J Neurol* 2008;255:452-453.
5. Arenas IA. Chronic tumor necrosis factor-alpha inhibition enhances NO modulation of vascular function in estrogen-deficient rats. *Hypertension* 2005;46:76-81.