



# The effect of dopamine for focal hand dystonia after stroke

Bomi Sul<sup>1</sup> · Joon Sung Kim<sup>1</sup> · Bo Young Hong<sup>1</sup> · Seong Hoon Lim<sup>1</sup>

Received: 4 October 2018 / Accepted: 4 January 2019  
© Fondazione Società Italiana di Neurologia 2019

Dear Editor,

Abnormal movements after cerebrovascular diseases are rare manifestations; however, the symptoms can be devastating for the patients. The most common post-stroke abnormal movement disorder is reported as dystonia, which can involve the contralateral face, arm, or leg, and most cases involved a structural lesion in the basal ganglia, most commonly in the putamen [1]. Medical therapy is known to be not very effective; however, a small dosage of dopamine can be a safe option of treatment while activating and restoring the function of the striatum [2].

A 42-year-old, right-handed man presented with clumsiness of his left hand for the last several months. He demonstrated painful cramping of his left hand while trying to make a fist (Video 1). He confessed that he had experienced mild dysarthria 6 months ago, but it soon disappeared. At that point, he was diagnosed by cerebral infarction and has been taken antiplatelet therapy. After then, clumsiness and painful cramping of the left hand followed, which exacerbated over the period. He was referred to the neuro-rehabilitation clinic for hand clumsiness and pain. There was no evidence of cognitive deficit or behavioral change. Upper motor neuron signs were absent, but only mild weakness in the left hand with muscle strength of grade 4 on the Medical Research Council scale. The results of sensory examination were unremarkable. Hand function test yielded longer processing time in his left side for single-hand activities, including moving objects and flipping cards. The abnormal high signal intensity was not founded at diffusion-weighted image. T2-weighted magnetic

resonance imaging (MRI) of his brain demonstrated high signal intensity in the right head of caudate nucleus and putamen (Fig. 1, axial images on the top and coronal images at the bottom). The patient was prescribed with 0.5 mg of pramipexole, a dopamine agonist of the non-ergoline class, twice a day. After 2 weeks, the patient returned with substantial improvement in symptoms (Video 2).

Secondary movement disorders are reported to develop in 1–4% patients after stroke, mainly affecting deep structures such as basal ganglia and thalamus [1]. Dystonia, characterized by sustained or repetitive muscle contractions resulting in abnormal, often frustrating, movements or postures, was the most common type among the post-stroke movement disorders [1]. The majority of cases of post-stroke dystonia had a latency measured in several months, whereas most other post-stroke movement disorders manifested within the first 7 days [3]. The lesion of the thalamus and basal ganglia was frequently associated with secondary contralateral upper limb dystonia [4]. Muscle co-contraction and failure of reciprocal inhibition are core features of dystonia, and such phenomenon arises from the imbalance between the synergistic action of the excitatory direct basal ganglia pathway and the net inhibitory indirect basal ganglia pathway [5]. The abnormal functioning of the basal ganglia-thalamus-cortical network induced by focal stroke would cause contralateral upper limb dystonia [4, 5].

Medical therapy has been regarded as not effective in most cases of post-stroke dystonia [2]. The most common medications are trihexyphenidyl (anti-cholinergic agent), benzodiazepines (diazepam, clonazepam), baclofen, levodopa, carbamazepine, ethopropazine, and valproic acid. Trihexyphenidyl and benzodiazepines are frequently reported as the most effective among them; however, most patients required several medication trials, and combination therapy was more effective than single-drug therapy [2]. Unfortunately, the most common side effects were also brought from the most effective ones, benzodiazepines and anti-cholinergic drugs. Side effects such as sedation, dizziness, confusion, cognitive decline, and memory loss discouraged the patients to discontinue the medications [2].

---

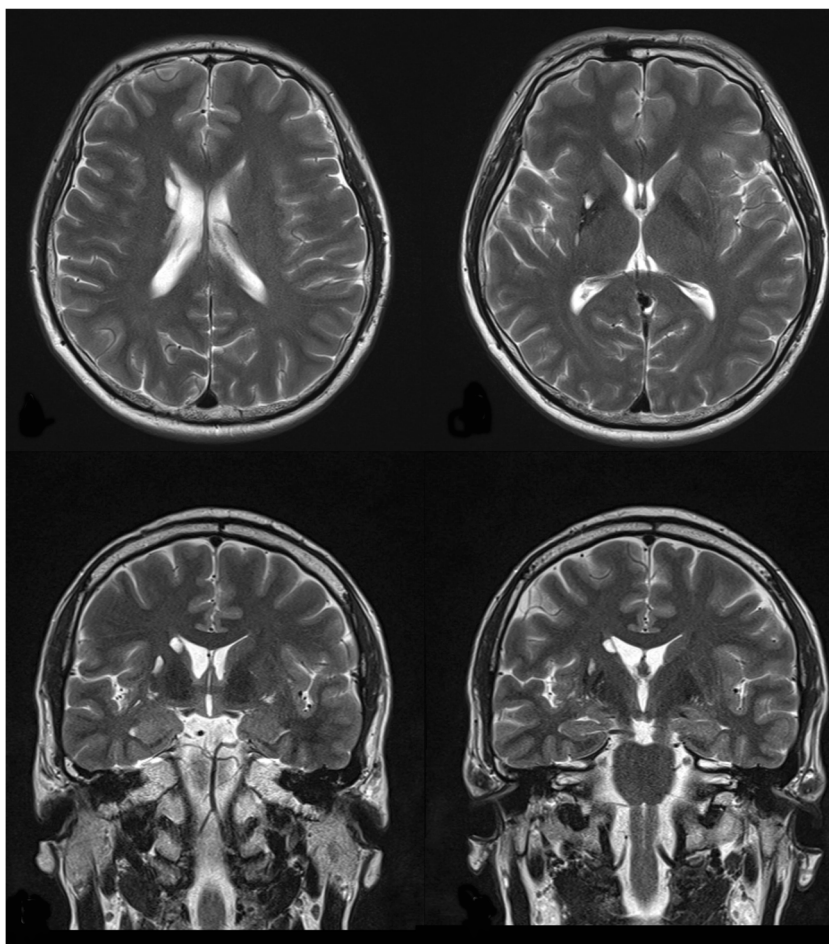
**Electronic supplementary material** The online version of this article (<https://doi.org/10.1007/s10072-019-3705-2>) contains supplementary material, which is available to authorized users.

---

✉ Seong Hoon Lim  
seonghoon@catholic.ac.kr

<sup>1</sup> Department of Rehabilitation Medicine, St. Vincent's Hospital, College of Medicine, The Catholic University of Korea, Seoul, Republic of Korea

**Fig. 1** The brain T2-weighted magnetic resonance imaging (MRI) of the patient. Upper images are axial images, and Bottom shows coronal images. The MRI of his brain demonstrated high signal intensity in the right head of caudate nucleus and putamen



For our 42-year-old young man, who was active and capable of carrying out his daily life activities by himself, a small dosage of dopamine was considered in the first place. It was a relatively safe trial regarding potential side effects of the more common medications such as anti-cholinergic agent or benzodiazepine, and it finally led to successful mediation of basal ganglia pathways and restoration of its function.

**Acknowledgements** The authors would like to acknowledge Hee Seung Sim for editing the video clips used in this article despite his battle with Duchene muscular dystrophy.

**Publisher's note** Springer Nature remains neutral with regard to jurisdictional claims in published maps and institutional affiliations.

## References

1. Gupta N, Pandey S (2018) Post-thalamic stroke movement disorders: a systemic review. *Eur Neurol* 79:303–314. <https://doi.org/10.1159/000490070>
2. Chuang C, Fahn S, Frucht SJ (2002) The natural history and treatment of acquired hemidystonia: report of 33 cases and review of the literature. *J Neurol Neurosurg Psychiatry* 72:59–67
3. Suri R, Rodriguez-Porcel F, Donohue K, Jesse E, Lovera L, Dwivedi AK, Espay AJ (2018) Post-stroke movement disorders: the clinical, neuroanatomic, and demographic portrait of 284 published cases. *J Stroke Cerebrovasc Dis* 27(9):2388–2397. <https://doi.org/10.1016/j.jstrokecerebrovasdis.2018.04.028>
4. Simonyan K, Cho H, Sichani AH, Rubien-Thomas E, Hallett M (2017) The direct basal ganglia pathway is hyperfunctional in focal dystonia. *Brain* 140:3179–3190. <https://doi.org/10.1093/brain/awx305>
5. Liuzzi D, Gigante AF, Leo A, Defazio G (2016) The anatomical basis of upper limb dystonia: lesson from secondary cases. *Neurol Sci* 37:1393–1398. <https://doi.org/10.1007/s10072-016-2598-6>