

# Rare presentation of iron deficiency anaemia with cerebral venous sinus thrombosis in a middle-aged woman

Amna Bibi,<sup>1</sup> Chathuri Liyanapthirana,<sup>2</sup> Sajjad Khan<sup>1</sup>

<sup>1</sup>Department of General Medicine, East Sussex Healthcare NHS Trust, Saint Leonards-on-Sea, UK

<sup>2</sup>Department of Stroke, Eastbourne District General Hospital, Eastbourne, UK

## Correspondence to

Dr Amna Bibi,  
amnadale@hotmail.com

Accepted 21 December 2018

## SUMMARY

This is a case of a female patient presented with a mild headache associated with recurrent episodes of nausea and vomiting, confusion and right-sided hemiparesis, diagnosed of haemorrhagic venous infarction from the thrombosis of left transverse and sigmoid sinus and probably the left vein of Labbe. She had severe microcytic hypochromic anaemia due to iron deficiency, without any other risk factors for cerebral venous thrombosis such as trauma history, infections, coagulation disorders or autoimmune diseases. She had a good prognosis after iron supplementation and anticoagulation therapy.

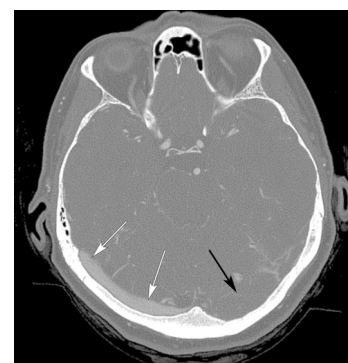## BACKGROUND

Cerebral venous thrombosis (CVT) is a relatively an uncommon cause of stroke, contributing <1%,<sup>1</sup> and the annual incidence is approximately 3 to 4 cases per million.<sup>2</sup>

It is three times more common among women than men.<sup>3</sup> Asian and Middle Eastern countries have a relatively higher incidence of CVT than in other lands.<sup>4</sup>

It is multifactorial with several predisposing conditions. Patients usually present with non-specific symptoms such as seizures, headache, confusion, abnormal vision, vomiting, drowsiness and lethargy, make it difficult to diagnose.<sup>5</sup>

The risk factors include inherited hypercoagulable states, trauma, infection, dehydration, pregnancy and puerperium, neoplastic invasion of cerebral venous sinuses, haematological disorders and use of oral contraceptive (OC) pills. Although iron deficiency anaemia (IDA) has been reported as a cause of CVT in several paediatric cases, this association is extremely rare. To our knowledge,



**Figure 2** Brain CT venogram showing extensive filling defect left transverse sinus (black arrow). Normal right transverse sinus (white arrows).

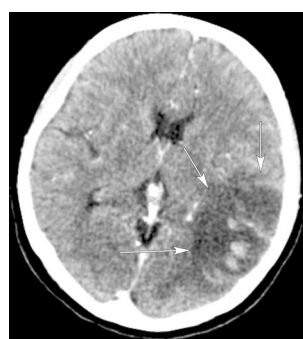
IDA-associated CVT in adults has been rarely reported.

## CASE PRESENTATION

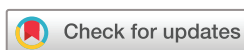A 63-year-old woman was admitted with sudden onset of headache, confusion, right hemiparesis and global aphasia. CT and subsequent CT venogram revealed left lateral temporal lobe venous infarction with haemorrhage and thrombosis of the left transverse sinus, sigmoid sinus, jugular bulb and the left vein of Labbe (figures 1–3).

The patient is a white British, with no family history of significance. There was no history of coagulation abnormality, recent trauma, autoimmune disease, hormonal substitution and gastrointestinal (GI) surgery. The only medication she took was over-the-counter paracetamol on an as required basis.

The laboratory tests revealed severe hypochromic microcytic anaemia with an initial haemoglobin value of 66 g/L (normal range: 125–165), a mean corpuscular volume of 57.8 fl (normal range: 80–100) and haematocrit of 0.227 (0.37–0.47) (table 1). Serum ferritin concentration was 7 µg/L (n=13–150). One study has shown that the most potent test for the diagnosis of IDA is the measurement of serum ferritin level.<sup>6</sup> No B<sub>12</sub> vitamin or folate deficiency was found (table 2). Screening for coagulopathy was normal (table 2), including factor II, factor V (Leyden), activated protein C resistance and antiphospholipid antibodies. Protein C, protein S and antithrombin III were not interpretable because of early vitamin K antagonists therapy. Autoimmune profile and homocysteine levels were normal. Tissue transglutaminase antibodies were

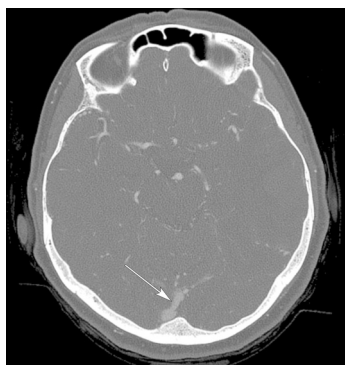


**Figure 1** Brain CT showing large posterior parietal and supratemporal venous infarct with haemorrhage (white arrows).



© BMJ Publishing Group Limited 2019. No commercial re-use. See rights and permissions. Published by BMJ.

**To cite:** Bibi A, Liyanapthirana C, Khan S. *BMJ Case Rep* 2019;**12**:e225851. doi:10.1136/bcr-2018-225851



**Figure 3** Brain CT venogram showing extensive filling defect left sigmoid sinus. Normal right sigmoid sinus (white arrow).

negative. Urine analysis did not show any blood. Upper and lower GI endoscopies, thoracoabdominal and pelvic CT were performed and failed to detect any malignant disease, source of active bleeding or pelvic vein thrombosis.

### TREATMENT

The patient was treated by blood transfusion with packed red blood cells with target haemoglobin above 8 g/L, oral iron supplementation with ferrous sulfate 200 mg three times per day.

According to international guidelines, heparin is the basic treatment for CVT, irrespective of the presence of venous haemorrhagic infarct,<sup>5 7</sup> with a good outcome.<sup>8 9</sup> Therefore, our patient was started promptly on anticoagulation, initially infusion of unfractionated heparin, followed by oral warfarin for a total duration of 6 months. We did not start patient on non-vitamin K antagonist oral anticoagulants (NOACs) since there are no randomised trials that have examined their safety and efficacy in patients with CVT.

### OUTCOME AND FOLLOW-UP

The patient's right hemiparesis gradually improved, as well as her global aphasia. The patient was discharged 1 month after the onset. The anaemia gradually improved with a haemoglobin value of 13.5 g/L on discharge, 6 weeks after the onset. Our assumption regarding the origin of the anaemia was a vegetarian diet without a proper iron substitution.

### DISCUSSION

CVT is an uncommon condition and needs careful approach and consideration due to its potential morbidity.<sup>10</sup> Because of its variable causes and predisposing conditions, delay in diagnosis is common. In one multicentre prospective study, 13.4% of patients had residual symptoms resulting in dependency, with a mortality rate of 8.3%.<sup>11</sup> Predisposing conditions for CVT are

**Table 2** Blood tests results

| Tests               | Admission | Discharge | Normal range |
|---------------------|-----------|-----------|--------------|
| INR                 | 0.9       | 2.7       | 0.8–1.2      |
| APTT <sub>r</sub>   | 0.76      | –         |              |
| Ferritin            | 7         | 40        | 13–150       |
| Folate              | 6.1       | –         | 3.9–26.8     |
| Vit B <sub>12</sub> | 232       | –         | 197–771      |

APTT<sub>r</sub>, Activated Partial Thromboplastin Time; INR, International Normalization Ratio; Vit B12, Vitamin B12.

prior medical conditions (eg, thrombophilias, antiphospholipid syndrome, malignancy and inflammatory bowel disease), transient events (eg, surgery, pregnancy, puerperium, dehydration, infection and head trauma) and medications (eg, OCs, exogenous hormones and substance abuse).<sup>5</sup>

OCs result in a considerable increase in the risk of CVT in women of reproductive age and this risk is further increased when there is an associated prothrombotic condition.<sup>12</sup> However, there are studies showing that the use of OC resulted in the rise in the serum levels of ferritin and haemoglobin. The possible explanation is that the use of OC results in a reduced loss of menstrual blood.<sup>13</sup>

CVT in association with IDA is rare in adults, and there are only a few reported cases of CVT in association with IDA.<sup>14–17</sup> However, one case–control study has shown a prevalence of 27% and a much stronger association.<sup>18</sup> As compared with women, anaemia is more likely to cause CVT in men. The reason may be the discrepancy in the absolute incidence of CVT, which is two and half times higher in women.<sup>19</sup> Also, men are more likely to have other risk factors causing anaemia such as recent surgery or infections.<sup>3</sup> It was also suggested that in women, the use of OC could be the reason for the lower frequency of anaemia with CVT.<sup>20 21</sup> However, a case–control study has shown that this is not a credible explanation.<sup>18</sup>

Some studies have shown a complication of pulmonary embolisms including fatal saddle embolism, resulting from the dislodging of emboli from the thrombosed superior sagittal sinus, with an overall incidence of 11.3% and a mortality rate of 95.6%.<sup>22 23</sup> In one case report, a patient had both pulmonary embolism and CVT in association with IDA and has advocated a steady association between IDA and occurrence of CVT.<sup>23</sup>

The exact mechanism for thrombosis in IDA is not known. The three elements of Triad of Virchow leading to thrombosis are: hypercoagulability, interrupted blood flow (stasis or turbulence) and damage to the vessel wall. In IDA, hypercoagulability and venous stasis play a major role in the formation of a thrombus.<sup>24</sup>

The possible mechanisms by which IDA is suggested to cause thrombosis are: first, as iron is an important regulator of thrombopoiesis,<sup>25</sup> low iron levels disinhibit megakaryocyte activity,<sup>26</sup> which provokes secondary thrombocytosis, thus leading to a hypercoagulable state.<sup>27</sup> However, more often the platelet count remains below  $700 \times 10^3/\text{mm}^3$ .<sup>28</sup> Erythropoietin levels rise in IDA. Both thrombopoietin and erythropoietin have shown an analogy in an amino acid sequence, therefore, an increase in erythropoietin may result in an increase in platelet production.<sup>29</sup> Few studies have also reported that in secondary thrombocytosis, IL-6 levels were increased and, that, may be playing a pathogenic part in causing secondary thrombocytosis.<sup>30</sup> Some studies have also shown that IDA results in qualitative platelet abnormalities due to an increase in oxidant stress, and may augment aggregation of platelets.<sup>31</sup>

**Table 1** Blood tests results

| Tests     | Admission | Discharge | Normal range |
|-----------|-----------|-----------|--------------|
| Hb        | 6.1       | 13.5      | 12.5–16.5    |
| MCV       | 58        | 76.1      | 80–100       |
| HCT       | 0.227     | 0.439     | 0.37–0.47    |
| Platelets | 560       | 457       | 150–400      |
| WCC       | 7.91      | 4.61      | 4.0–11.0     |
| RDW       | 17.6      | 17.6      | 11.8–14.8    |

HB, Haemoglobin; HCT, Haematocrit; MCV, Mean Corpuscular Volume; RDW, Red cell Distribution Width; WCC, White Cell Count.

Another study has reported a comparatively normal platelet count in a third of patients with IDA, and thrombocytosis just a contributing element for thrombosis.<sup>32</sup>

Second, microcytosis alters red cells deformability, which increases viscosity and possibly the risk of venous thrombosis.<sup>15</sup> Third, low serum ferritin levels result in an increase in plasma concentration of coagulation factor VIII, hence increasing thrombosis risk.<sup>33</sup> Finally, anaemic hypoxia may occur as the oxygen-carrying capacity of erythrocytes decreases, especially in situations with increased metabolic demands in the brain and cause ischaemic damage in the area of the brain supplied by the terminal arteries. All these conditions lead to turbulent blood flow, causing platelets to come more frequently in contact with the endothelial lining.<sup>34</sup>

A study has shown that the treatment of CVT with anticoagulants is safe and may protect from further cerebral venous infarcts, worsening of neurological symptoms and pulmonary embolism.<sup>35</sup> Pulmonary embolism was one of the major causes of death in patients with CVT.<sup>22</sup> According to the international guidelines, heparin is the keystone of the CVT treatment with good results.<sup>5 8 9</sup> The safety profile of low-molecular-weight heparin is better than unfractionated heparin, however, unfractionated heparin is preferred when the patient is for urgent neurosurgical intervention and hence, a prompt reversal of anticoagulation is required.<sup>36 37</sup> The two types of endovascular treatments (ET) for CVT<sup>38</sup> are mechanical thrombectomy and intrasinus thrombolysis; however, there are no major prospective or randomised trials on the efficacy and safety of ET; therefore, this treatment method is not in common practice. A small number of patients may develop herniation of subfalx or transtentorium, and hence, merit quick neurosurgical intervention in the form of decompressive surgery (DS). Uncontrolled studies have shown good results of DS;<sup>39–42</sup> however, there are no randomised trials on the outcome of DS. NOACs, when compared with warfarin, have shown about 50% reductions in the relative risk of intracranial bleeds.<sup>43 44</sup> However, apart from two minor case series,<sup>45 46</sup> no randomised trial has examined the safety and efficacy of NOACs in patients with CVT.

## Learning points

- Iron deficiency anaemia (IDA) can cause cerebral venous thrombosis (CVT).
- When cerebral infarction occurs, anticoagulation therapy with iron supplementation must be done immediately.
- Treatment for IDA may be an important strategy to prevent CVT and subsequent cerebral infarction.

**Contributors** AB: conception and design of the case report, data collection, drafting the article, critical revision of the article and final approval of the version published. CL: critical revision of the article and final approval of the version published. SK: data collection.

**Funding** The authors have not declared a specific grant for this research from any funding agency in the public, commercial or not-for-profit sectors.

**Competing interests** None declared.

**Patient consent** Obtained.

## REFERENCES

- 1 Masuhr F, Mehraein S, Einhäupl K. Cerebral venous and sinus thrombosis. *J Neurol* 2004;251:11–23.
- 2 Stam J. Thrombosis of the cerebral veins and sinuses. *N Engl J Med* 2005;352:1791–8.
- 3 Coutinho JM, Ferro JM, Canhã P, et al. Cerebral venous and sinus thrombosis in women. *Stroke* 2009;40:2356–61.
- 4 Siddiqui FM, Kamal AK. Incidence and epidemiology of cerebral venous thrombosis. *J Pak Med Assoc* 2006;56:485–7.
- 5 Saposnik G, Barinagarrementeria F, Brown RD, et al. Diagnosis and management of cerebral venous thrombosis: a statement for healthcare professionals from the American Heart Association/American Stroke Association. *Stroke* 2011;42:1158–92.
- 6 Guyatt GH, Oxman AD, Ali M, et al. Laboratory diagnosis of iron-deficiency anemia: an overview. *J Gen Intern Med* 1992;7:145–53.
- 7 Tait C, Baglin T, Watson H, et al. Guidelines on the investigation and management of venous thrombosis at unusual sites. *Br J Haematol* 2012;159:28–38.
- 8 de Bruijn SF, Stam J. Randomized, placebo-controlled trial of anticoagulant treatment with low-molecular-weight heparin for cerebral sinus thrombosis. *Stroke* 1999;30:484–8.
- 9 Einhäupl KM, Villringer A, Meister W, et al. Heparin treatment in sinus venous thrombosis. *Lancet* 1991;338:597–600.
- 10 Bousser MG, Ferro JM. Cerebral venous thrombosis: an update. *Lancet Neurol* 2007;6:162–70.
- 11 Ferro JM, Canhã P, Stam J, et al. Prognosis of cerebral vein and dural sinus thrombosis: results of the International Study on Cerebral Vein and Dural Sinus Thrombosis (ISCVT). *Stroke* 2004;35:664–70.
- 12 Dentali F, Crowther M, Ageno W. Thrombophilic abnormalities, oral contraceptives, and risk of cerebral vein thrombosis: a meta-analysis. *Blood* 2006;107:2766–73.
- 13 Yeasmin T, Haque MS, Amin MR. Iron status in women using oral contraceptives. *Bangladesh J Physiol Pharmacol* 2010;26:25–9.
- 14 Aoki N, Sakai T. Cerebral sinus thrombosis in patients with severe iron deficiency anaemia due to myoma uteri. *Acta Neurochir* 1989;97(3–4):131–4.
- 15 Balci K, Utku U, Asil T, et al. Deep cerebral vein thrombosis associated with iron deficiency anaemia in adults. *J Clin Neurosci* 2007;14:181–4.
- 16 Ogata T, Kamouchi M, Kitazono T, et al. Cerebral venous thrombosis associated with iron deficiency anemia. *J Stroke Cerebrovasc Dis* 2008;17:426–8.
- 17 Huang PH, Su JJ, Lin PH. Iron deficiency anemia - a rare etiology of sinus thrombosis in adults. *Acta Neurol Taiwan* 2010;19:125–30.
- 18 Coutinho JM, Zuurbier SM, Gaartman AE, et al. Association between anemia and cerebral venous thrombosis: Case-control study. *Stroke* 2015;46:2735–40.
- 19 Coutinho JM, Zuurbier SM, Aramideh M, et al. The incidence of cerebral venous thrombosis: a cross-sectional study. *Stroke* 2012;43:3375–7.
- 20 Mooij PN, Thomas CM, Doesburg WH, et al. The effects of oral contraceptives and multivitamin supplementation on serum ferritin and hematological parameters. *Int J Clin Pharmacol Ther Toxicol* 1992;30:57–62.
- 21 Grace E, Emans SJ, Drum DE. Hematologic abnormalities in adolescents who take oral contraceptive pills. *J Pediatr* 1982;101:771–4.
- 22 Diaz JM, Schiffman JS, Urban ES, et al. Superior sagittal sinus thrombosis and pulmonary embolism: a syndrome rediscovered. *Acta Neurol Scand* 1992;86(4):390–6.
- 23 Nicastro N, Schneider A, Leemann B. Iron-deficiency anemia as a rare cause of cerebral venous thrombosis and pulmonary embolism. *Case Rep Med* 2012;2012:1–3.
- 24 Ho BL, Huang P, Khor GT, et al. Simultaneous thrombosis of cerebral artery and venous sinus. *Acta Neurol Taiwan* 2008;17:112–6.
- 25 Franchini M, Targher G, Montagnana M, et al. Iron and thrombosis. *Ann Hematol* 2008;87(3):167–73.
- 26 Habis A, Hobson WL, Greenberg R. Cerebral sinovenous thrombosis in a toddler with iron deficiency anemia. *Pediatr Emerg Care* 2010;26(11):848–51.
- 27 Beguin Y. Erythropoietin and platelet production. *Haematologica* 1999;84(6):541–7.
- 28 Sanchez S, Ewton A. Essential thrombocythemia: a review of diagnostic and pathologic features. *Arch Pathol Lab Med* 2006;130:1144–50.
- 29 Bilic E, Bilic E. Amino acid sequence homology of thrombopoietin and erythropoietin may explain thrombocytosis in children with iron deficiency anemia. *J Pediatr Hematol Oncol* 2003;25:675–6.
- 30 Tefferi A, Ho TC, Ahmann GJ, et al. Plasma interleukin-6 and C-reactive protein levels in reactive versus clonal thrombocytosis. *Am J Med* 1994;97:374–8.
- 31 Tekin D, Yavuzer S, Tekin M, et al. Possible effects of antioxidant status on increased platelet aggregation in childhood iron-deficiency anemia. *Pediatr Int* 2001;43:74–7.
- 32 Keung YK, Owen J. Iron deficiency and thrombosis: literature review. *Clin Appl Thromb Hemost* 2004;10:387–91.
- 33 Livesey JA, Manning RA, Meek JH, et al. Low serum iron levels are associated with elevated plasma levels of coagulation factor VIII and pulmonary emboli/deep venous thromboses in replicate cohorts of patients with hereditary haemorrhagic telangiectasia. *Thorax* 2012;67:328–33.
- 34 Hartfield DS, Lowry NJ, Keene DL, et al. Iron deficiency: a cause of stroke in infants and children. *Pediatr Neurol* 1997;16(1):50–3.
- 35 Coutinho JM, de Bruijn SFTM, deVeber G, et al. Anticoagulation for cerebral venous sinus thrombosis. *Stroke* 2012;43:41–2.
- 36 Coutinho JM, Ferro JM, Canhã P, et al. Unfractionated or low-molecular weight heparin for the treatment of cerebral venous thrombosis. *Stroke* 2010;41:2575–80.
- 37 Misra UK, Kalita J, Chandra S, et al. Low molecular weight heparin versus unfractionated heparin in cerebral venous sinus thrombosis: a randomized controlled trial. *Eur J Neurol* 2012;19:1030–6.

- 38 Scott JA, Pascuzzi RM, Hall PV, *et al.* Treatment of dural sinus thrombosis with local urokinase infusion. Case report. *J Neurosurg* 1988;68:284–7.
- 39 Stefini R, Latronico N, Cornali C, *et al.* Emergent decompressive craniectomy in patients with fixed dilated pupils due to cerebral venous and dural sinus thrombosis: report of three cases. *Neurosurgery* 1999;45:626–30.
- 40 Coutinho JM, Majoie CB, Coert BA, *et al.* Decompressive hemicraniectomy in cerebral sinus thrombosis: consecutive case series and review of the literature. *Stroke* 2009;40:2233–5.
- 41 Ferro JM, Crassard I, Coutinho JM, *et al.* Decompressive surgery in cerebrovenous thrombosis: a multicenter registry and a systematic review of individual patient data. *Stroke* 2011;42:2825–31.
- 42 Théaudin M, Crassard I, Bresson D, *et al.* Should decompressive surgery be performed in malignant cerebral venous thrombosis?: a series of 12 patients. *Stroke* 2010;41:727–31.
- 43 Chatterjee S, Sardar P, Biondi-Zoccai G, *et al.* New oral anticoagulants and the risk of intracranial hemorrhage: traditional and Bayesian meta-analysis and mixed treatment comparison of randomized trials of new oral anticoagulants in atrial fibrillation. *JAMA Neurol* 2013;70:1486–90.
- 44 van Es N, Coppens M, Schulman S, *et al.* Direct oral anticoagulants compared with vitamin K antagonists for acute venous thromboembolism: evidence from phase 3 trials. *Blood* 2014;124:1968–75.
- 45 Geisbüsch C, Richter D, Herweh C, *et al.* Novel factor xa inhibitor for the treatment of cerebral venous and sinus thrombosis: first experience in 7 patients. *Stroke* 2014;45:2469–71.
- 46 Mendonça MD, Barbosa R, Cruz-e-Silva V, *et al.* Oral direct thrombin inhibitor as an alternative in the management of cerebral venous thrombosis: a series of 15 patients. *Int J Stroke* 2015;10:1115–8.

Copyright 2018 BMJ Publishing Group. All rights reserved. For permission to reuse any of this content visit <https://www.bmj.com/company/products-services/rights-and-licensing/permissions/>  
BMJ Case Report Fellows may re-use this article for personal use and teaching without any further permission.

Become a Fellow of BMJ Case Reports today and you can:

- Submit as many cases as you like
- Enjoy fast sympathetic peer review and rapid publication of accepted articles
- Access all the published articles
- Re-use any of the published material for personal use and teaching without further permission

For information on Institutional Fellowships contact [consortiasales@bmjgroup.com](mailto:consortiasales@bmjgroup.com)

Visit [casereports.bmj.com](http://casereports.bmj.com) for more articles like this and to become a Fellow