

CASE REPORT

Behavioural changes as the first manifestation of a silent frontal lobe stroke

Rafael García Carretero,¹ Blanca-Nieves Beamonte-Vela,¹
Jose-David Silvano-Cocinero,¹ Ana Alvarez-Mendez²

¹Internal Medicine, Hospital Universitario de Mostoles, Mostoles, Spain

²Intensive Care Medicine, Hospital Universitario de Mostoles, Mostoles, Spain

Correspondence to

Dr Rafael García Carretero, rgcarretero@salud.madrid.org

Accepted 18 December 2018

SUMMARY

A 67-year-old man was admitted to our hospital after his relatives found him to have severe personality and behavioural changes. His behaviour was inappropriate and uninhibited. The patient reported no symptoms and he showed poor insight into his own behaviour. Neuroimaging showed an orbitofrontal lesion, due to an infarction of the anterior cerebral artery. The patient was diagnosed with frontal lobe syndrome.

BACKGROUND

Frontal behavioural syndromes caused by strokes are rarely reported, it therefore remains unclear whether a frontal lobe infarction is actually silent or asymptomatic.¹ The frontal lobe, due to its size, is commonly involved in strokes. Most strokes are caused by ischaemic or haemorrhagic involvement of the middle cerebral artery, and clinical manifestations are therefore mainly due to injury to the precentral gyrus (pre-Rolandic area), which is a motor cortex.

However, strokes due to involvement of the anterior cerebral artery confined to the prefrontal cortex have been designated as silent or asymptomatic, but whether they are truly asymptomatic is not clear, since psychiatric symptoms, personality and behavioural changes must be considered as neurological manifestations.¹

Clinical manifestation of frontal lobe involvement depends on the size of the lesion, side (left or right), depth and type of injury. These personality changes in the frontal lobe can be hard to recognise because of their subacute onset. The clinical spectrum can be wide: from impulsiveness and disinhibition, to apathy, abulia or amotivational state.²

CASE PRESENTATION

A 67-year-old man was admitted to our hospital after his relatives found him to have changes in his personality for the last 10–15 days. He had been a responsible, mild-mannered man, who worked as a bank manager. For the past 2 weeks, he had been showing behavioural changes: he was rude when eating food; he did not wait until his relatives were at the table; he did not always use a knife and fork; he used foul language while eating; he sometimes used inappropriate sexual words when addressing his relatives; his wife said he showed inappropriate sexual behaviour, such as masturbation without shame while she was present. However, he showed

no concern regarding these changes. Aggression or verbal abuse were not present as behavioural symptoms.

He had hypertension and type 2 diabetes mellitus, and was on ramipril 2.5 mg daily and metformin 1 g twice a day.

On physical examination, his temperature was 36.2°C, he had a heart rate of 78 bpm, blood pressure of 143/84 mm Hg and oxygen saturation of 97% on room air. On auscultation, heart sounds and lungs were normal. On neurological examination, the patient did not show any focal or lateralising neurological signs.

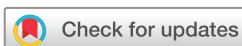INVESTIGATIONS

Laboratory tests were normal, with a white cell count of $6.7 \times 10^9/L$, haemoglobin 14.1 g/L and platelets $179 \times 10^9/L$. Kidney and liver panels were also normal. The chest X-ray showed no acute process. However, the brain CT scan showed a right frontal cortical-subcortical hypodensity area ($5.5 \times 2 \times 6$ cm), with no mass effect and no abnormal enhancement after intravenous contrast administration (figure 1A). As the lesion could have resembled a non-aggressive brain tumour, a brain MRI was performed. The MRI (figure 1, slides B–D) showed a right frontal cortical-subcortical hyperintensity in T2 and hypointensity in T1. These radiological findings led us to establish the diagnosis of subacute anterior cerebral artery stroke.

OUTCOME AND FOLLOW-UP

Echocardiography, carotid ultrasound, 24 hours Holter monitoring and electroencephalogram were also performed, but they did not find any abnormalities. We started aspirin 100 mg daily and atorvastatin 20 mg daily.

Our patient remained in the admissions ward for 1 week to complete the work-up. During his stay, the patient got better and his neurological symptoms improved. As a plausible hypothesis, we think the patient started recovering some days before he was admitted. It sounds reasonable, since the onset was subacute. His relatives said he once again became nice, judicious, prudent, thoughtful and well-mannered. He was discharged and was scheduled for a follow-up 3 months later. Generally speaking, he continued to be the person he was before the stroke, but he was never aware of his changes, and his family said he had problems in interpreting others' moods.



© BMJ Publishing Group Limited 2019. No commercial re-use. See rights and permissions. Published by BMJ.

To cite: García Carretero R, Beamonte-Vela B-N, Silvano-Cocinero J-D, et al. *BMJ Case Rep* 2019;**12**:e227617. doi:10.1136/bcr-2018-227617

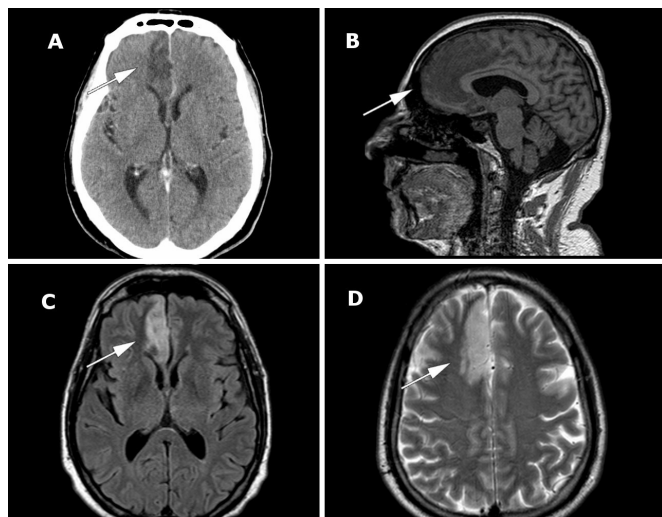


Figure 1 Neuroimaging (brain CT scan and MRI) of the frontal lobe. Slide A shows a right frontal cortical–subcortical hypodense area (arrow); this lesion causes no mass effect and no abnormal enhancement after intravenous contrast administration. Slide B (T1-weighted MRI) shows a hypodense lesion in a sagittal plane of the wide frontal lobe lesion (arrow). Slides C (fluid-attenuated inversion recovery) and D (T2-weighted turbo spin-echo) show a right frontal cortical–subcortical hyperintensity (axial plane, arrows pointing the lesion).

DISCUSSION

Mental changes after frontal lobe injury have been reported since the 1940s. It is well known that higher mental functions are affected after frontal lobe damage.³ Human behaviour is involved, and emotions, attention, interest and will are therefore affected. Patients with so-called frontal lobe syndrome can have a complete change in personality as an expression of the above-mentioned damage. Size, extension and side of the lesion are essential in developing certain symptoms.^{1,4}

Diffuse neurodegenerative diseases, as well as focal lesions such as stroke, head trauma, neoplasm and bacterial abscess formation, can cause personality changes when the frontal lobe is involved, by compromising the frontal cortical and subcortical structures.⁴

The most common denomination of frontal lobe syndromes is ‘frontal lobe personality’. Clinical manifestations of these syndromes, in which mood, behaviour and cognition are involved, include not only disinhibition and impulsiveness, but also apathy and abulia.⁴

There are several ways to classify frontal lobe syndrome, in an attempt to develop a clinical-topographic correspondence. Patients with orbitofrontal syndrome show impulsiveness, fearlessness, abnormal sexual behaviour, hyperactivity and disregard for others’ emotions. Patients with anterior cingulate syndrome are apathetic and aboulia, and they become quiet. Patients with dorsolateral prefrontal cortex syndrome tend to be less organised and lack the ability to plan (the so-called executive dysfunction). However, if the lesion involves the subcortical circuitry, patients can have combined syndromes. Therefore, clinical manifestations can sometimes be heterogeneous, since the frontal lobe disorder may be caused by a wide cortical lesion or interruption of the frontal-subcortical circuitry.⁴ However, predicting symptoms based on neuroanatomic injuries can be challenging, and patients with a lesion in the frontal lobe might not develop personality or behavioural changes.^{4,5} It is worth noting that lateralisation is important due to the functional differences between both cerebral hemispheres, as some clinicopathological

correlations can be set. Therefore, behavioural changes correlate with the involved arterial domain. If left anterior cerebral artery is involved, amotivational and apathetic features may arise. On the contrary, delayed response deficits with impulsivity, social improprieties, deficient social pragmatics, social anarchy and emotional regulation deficits may arise on stroke of the right anterior cerebral artery.^{6–9}

Probably due to the above-mentioned reasons (low incidence of stroke in the frontal lobe, heterogeneous clinical presentation, difficulties in predicting symptoms and outcome), frontal behavioural syndromes due to stroke are uncommon in the medical literature and have been rarely reported, when compared with other diseases (such as abscesses and brain tumours).⁵

Some instruments have been developed in order to measure personality, in an attempt to compare premorbid traits of personality versus current changes, but these tools have proven not to be useful for assessing real-life predictions.⁴

Therapy is not easy to initiate, as identification and assessment of these frontal syndromes can be difficult. Furthermore, patients often have no insight into the disorder, and cannot identify situations in which their behaviour is inappropriate. This leads to a failure to respond to reinforcers trying to modify emotional responses.¹⁰

Learning points

- ▶ Stroke is characterised by an acute onset of neurological symptoms, which are usually motor-related. However, personality changes such as impulsiveness and disinhibition can be explained by fronto-cortical damage.
- ▶ Frontal lobe personality includes emotional disorders or executive dysfunction, but the symptoms are uncommon and sometimes difficult to identify: abnormal emotional responses, jealousy, abnormal sense of humour, lack of empathy, apathy.
- ▶ Frontal lobe syndromes can be misdiagnosed and therefore left untreated. Clinicians should be aware when relatives are concerned about personality or behavioural changes in the patient, particularly when patients are unable to control emotions or experience emotional changes.
- ▶ Frontal strokes will remain silent only if clinicians are unable to identify characteristic symptoms.

Contributors RGC wrote the first draft. BNBV fixed spelling and grammar mistakes. JDSC edited the MRI images. AAM revised the final manuscript.

Funding The authors have not declared a specific grant for this research from any funding agency in the public, commercial or not-for-profit sectors.

Competing interests None declared.

Patient consent Obtained.

Provenance and peer review Not commissioned; externally peer reviewed.

REFERENCES

- 1 Nagaratnam N, Bou-Haidar P, Leung H. Confused and disturbed behavior in the elderly following silent frontal lobe infarction. *Am J Alzheimers Dis Other Dement* 2003;18:333–9.
- 2 Scheffer M, Monteiro JK, de Almeida RMM. Frontal stroke: Problem solving, decision making, impulsiveness, and depressive symptoms in men and women. *Psychol Neurosci* 2011;4:267–78.
- 3 Goldstein K. The mental changes due to frontal lobe damage. *J Psychol* 1944;17:187–208.
- 4 Chow TW. Personality in frontal lobe disorders. *Curr Psychiatry Rep* 2000;2:446–51.
- 5 Bogousslavsky J. Frontal stroke syndromes. *Eur Neurol* 1994;34:306–15.
- 6 Poletti M, Lucetti C, Logi C, et al. Cognitive correlates of negative symptoms in behavioral variant frontotemporal dementia: implications for the frontal lobe syndrome. *Neurol Sci* 2013;34:1893–6.

- 7 Berlin HA, Rolls ET, Kischka U. Impulsivity, time perception, emotion and reinforcement sensitivity in patients with orbitofrontal cortex lesions. *Brain* 2004;127:1108–26.
- 8 Rosen HJ, Wilson MR, Schauer GF, *et al.* Neuroanatomical correlates of impaired recognition of emotion in dementia. *Neuropsychologia* 2006;44:365–73.
- 9 Rankin KP, Gorno-Tempini ML, Allison SC, *et al.* Structural anatomy of empathy in neurodegenerative disease. *Brain* 2006;129:2945–56.
- 10 Rolls ET, Hornak J, Wade D, *et al.* Emotion-related learning in patients with social and emotional changes associated with frontal lobe damage. *J Neurol Neurosurg Psychiatry* 1994;57:1518–24.

Copyright 2019 BMJ Publishing Group. All rights reserved. For permission to reuse any of this content visit <https://www.bmj.com/company/products-services/rights-and-licensing/permissions/>
BMJ Case Report Fellows may re-use this article for personal use and teaching without any further permission.

Become a Fellow of BMJ Case Reports today and you can:

- ▶ Submit as many cases as you like
- ▶ Enjoy fast sympathetic peer review and rapid publication of accepted articles
- ▶ Access all the published articles
- ▶ Re-use any of the published material for personal use and teaching without further permission

For information on Institutional Fellowships contact consortiasales@bmjgroup.com

Visit casereports.bmj.com for more articles like this and to become a Fellow