

CASE REPORT

Acute ischaemic stroke-related choreoathetosis treated with arterial thrombectomy

Ali Muhammad,¹ Egidija Bielskute,² Paul C Guyler,³ Iris Q Grunwald¹

¹Department of Stroke Medicine, Southend University Hospital NHS Foundation Trust, Essex, UK

²Anaesthetics Department, Southend University Hospital NHS Foundation Trust, Westcliff-on-Sea, UK

³Department of Stroke Medicine, Southend University Hospital, Southend, UK

Correspondence to

Dr Ali Muhammad,
ali.muhammad@southend.nhs.uk

Accepted 3 December 2018

SUMMARY

A rare case of acute choreoathetosis after acute stroke is presented. This 66-years-old, right-handed Caucasian woman presented with weakness of her right arm and right leg with dysarthria, which resolved by the time she arrived in the emergency department. No obvious focal sign apart from the abnormal choreoathetoid movement of the right arm and leg and of the neck was present. Her medical history included atrial fibrillation without anticoagulation. CT head was nil acute (Alberta Stroke Program Early CT Score of 10). CT angiography of the carotids showed a hyperdense M2 segment of the left middle cerebral artery. Intravenous thrombolysis immediately followed by thrombectomy was decided. Using the Penumbra aspiration device (ACE 68) two clots were removed with two aspirations. A small distal clot remained but partial recanalisation (Thrombolysis in Myocardial Infarction/Thrombolysis in Cerebral Infarction 2b) was achieved. 30 seconds after restoring blood flow, the choreoathetoid movements ceased. The patient was brought to intensive care for further monitoring, which was uneventful.

BACKGROUND

Stroke can cause different types of movement disorders like hyperkinetic syndromes (hemiballism, hemichorea, unilateral asterixis, limb shaking, dystonia, tremor and myoclonus) and hypokinetic syndromes (especially vascular Parkinsonism). They can occur either acutely or as delayed manifestations.¹ Hyperkinetic movement disorders are uncommon in acute stroke (1%), according to a previous hospital-based study—the the most common types being hemichorea–hemiballism and hemidystonia.²

In the acute setting, stroke is usually perceived as a paucity of movement rather than an excess of it, therefore, acute stroke as a cause of acute-onset movement disorder may be easily overlooked.

CASE PRESENTATION

We report an interesting case of acute choreoathetosis as the presenting symptom of acute ischaemic stroke in a 66-year-old woman, with known atrial fibrillation without being anticoagulated. This 66-year-old right-handed woman came in with weakness of the right arm and right leg with some dysarthria, which resolved by the time she arrived in A&E, with only some heaviness remaining on her right side. NIHSS on examination at the emergency department was 0 as there was no obvious focal sign

apart from the abnormal movement of the right side (arm and leg) along with neck. The movement was involuntary, jerky, non-repetitive, semi-purposive, irregular and continuous with some writhing movements of the proximal left arm and left leg. The movement was deemed choreoathetoid.

INVESTIGATIONS

CT head did not show any established infarct with the Alberta Stroke Programme Early CT Score (ASPECTS) of 10, confirmed by the eASPECTS software (Brainomix, Oxford) (figure 1). CT angiography of the carotids along with its 3D reconstruction showing a hyperdense M2 segment of the left middle cerebral artery could suggest obstruction of the vessel (figures 2–4).

TREATMENT

Multidisciplinary team involving the stroke consultant, neuroradiologist and interventionist and intensive therapy unit (ITU) consultant decided on

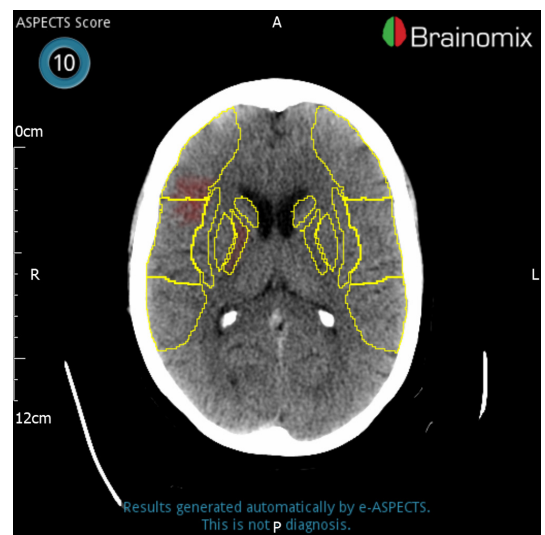
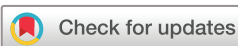

Figure 1 System generated Brainomix eASPECTS scoring did not flag any hypodensities above threshold. The ASPECTS is a 10-point quantitative topographic head CT scan score used to quantify early ischaemic change of acute stroke in patients with middle cerebral artery stroke. Segmental assessment of the middle cerebral artery vascular territory is made and one point is deducted from the initial score of 10 for every predefined region acutely involved. An ASPECTS ≤ 7 indicates a more severe stroke with worse functional outcome. ASPECTS, Alberta Stroke Programme Early CT Score.



© BMJ Publishing Group Limited 2019. No commercial re-use. See rights and permissions. Published by BMJ.

To cite: Muhammad A, Bielskute E, Guyler PC, et al. *BMJ Case Rep* 2019;**12**:e226035. doi:10.1136/bcr-2018-226035

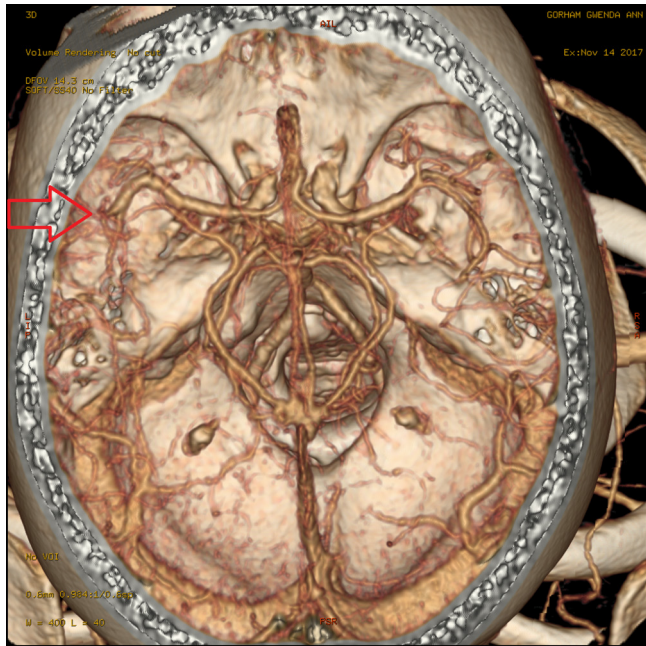


Figure 2 Static image of 4D reconstruction of CT angiogram showing occlusion of the left M2 branch (red arrow) and surrounding collaterals. Please note the section is above downwards (ie, left and right sides are transposed) for better visualisation of circle of Willis and its branches.

intravenous thrombolysis (as the patient had persistent neurological symptoms) to be immediately followed by thrombectomy using aspiration procedure considering the patients good baseline functioning (baseline modified Rankin Score was 2) as potential benefit of the procedure would outweigh the potential risk of bleeding in expert hand. Thrombolysis with intravenous tissue plasminogen activator (Alteplase) did not produce any noticeable improvement. An anaesthetic cover was immediately

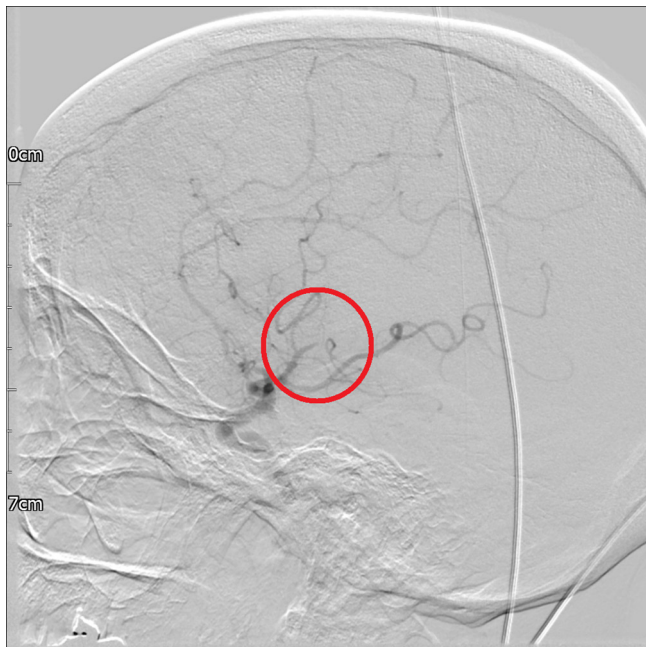


Figure 3 Image acquired from digital subtraction angiography: area (inside the red circle) demonstrating occlusion of the left M2 branch (notice the abrupt cut-off of flow).

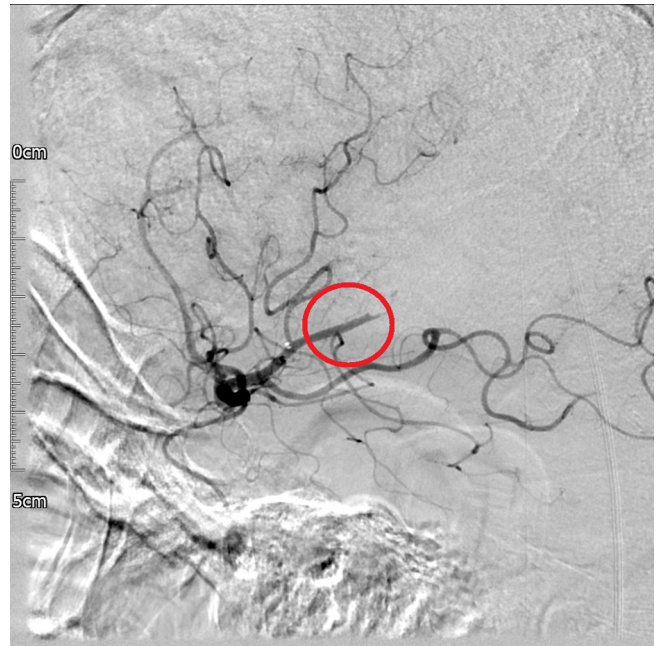


Figure 4 Image acquired from digital subtraction angiography: area (inside the red circle) demonstrating partial recanalisation (TIMI/TICI 2b) of the occluded left M2 branch, which was presumably responsible for supplying the part of the basal ganglia responsible for the choreoathetoid presentation. TIMI/TICI, Thrombolysis in Myocardial Infarction/Thrombolysis in Cerebral Infarction.

available. The anaesthetist team decided on using local anaesthesia as opposed to general anaesthesia.

The patient was compos mentis and she and her husband signed the consent form.

WHO Surgical Safety Checklist³ was performed before the procedure. Time from the decision to treat to arterial puncture was about 1:15 hours. Patient's head had to be passively immobilised to prevent choreoathetotic movements interfering with the procedure. Left-sided arteries were used as movement disorder continued on the right. Initially the left femoral artery was punctured with aseptic technique and a 5-French sheath was introduced. This was exchanged with a 6-French Neuron MAX 088, which was brought up via a Bern catheter and placed into the left internal carotid artery. The device was deployed within 24 min of arterial puncture. Digital subtraction angiography selective injections confirmed the M2 branch occlusion (figure 3). Aspiration was performed using a 3 Max Penumbra catheter (ACE 68, introduced with a Synchro 14 guidewire). With two aspirations, two pieces of clot could be removed. A small distal clot remained but it was expected that, over time, there would be autolysis and increased recanalisation.

Thrombolysis in Myocardial Infarction (TIMI) Score describes distal flow, perfusion and revascularisation before and following therapy and is now a standard for reporting reperfusion procedure efficacy.⁴ Another grading system is TICI (Thrombolysis in Cerebral Infarction) Perfusion categories, which offer a more uniform set of criteria for reporting outcomes involving intra-arterial thrombolytic agents, either alone or in combination with other therapies.⁵ Filling of the M2 branch was appreciated at the TIMI/TICI 2b level (figure 4) in the last series.

Partial flow through the affected vessel was restored within 11 min of the device being deployed. Haemostasis was achieved with an Angio-Seal Vascular Closure Device. The whole procedure took about 50 min since arterial puncture.

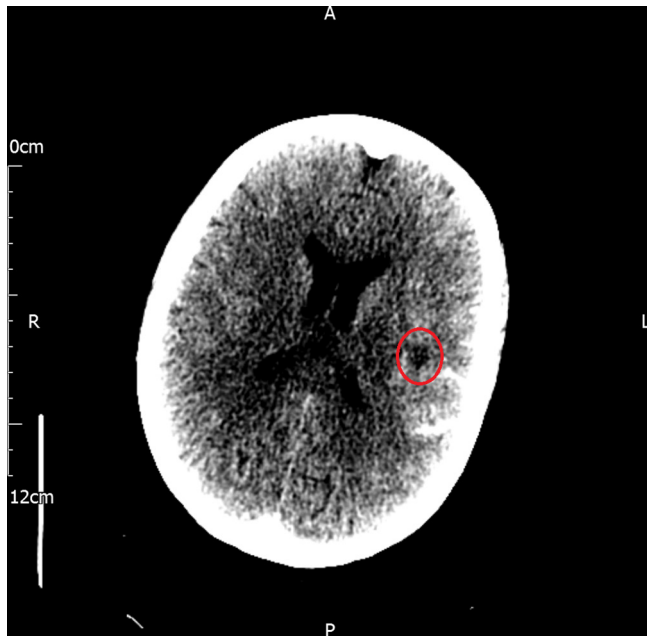


Figure 5 Small area of infarct (inside red circle) in the left parietal white matter saving a surrounding much larger area from infarct, some haemorrhagic imbibition was also seen. Without timely intervention, the area of infarct would presumably be much bigger with persistent disability.

OUTCOME AND FOLLOW-UP

The patient tolerated the procedure well. After around 30s of restoring the partial flow and removal of the second clot, choreoathetotic movements ceased to occur. She did not develop any limb weaknesses as assessed right after the procedure by the stroke consultant. The patient remained fully oriented, no dysphasia or dysarthria. Postprocedure instructions were noted. The patient was brought to the intensive care unit for further monitoring, which was uneventful.

CT head done >24 hours later showed only hypodensity in the adjacent frontal white matter, which kept with a small infarct (figure 5).

DISCUSSION

Middle or posterior cerebral artery territory small vessel disease supplying the basal ganglia can cause movement disorders. Haemorrhagic lesions usually may induce hyperkinetic movement disorders. Movement disorders caused by stroke usually resolves spontaneously over time.⁶

Chorea is a hyperkinetic movement disorder with involuntary brief, jerky, random and irregular contractions of muscle groups making the patient appear restless to the observer.⁷ Cause of chorea can be hereditary neurodegenerative diseases, follow structural damage to deep brain structures, or be associated with autoimmune disorders, neurotransmitter receptor blockade, metabolic derangement, or certain drugs and hormones.^{7 8} Damage or dysfunction of these structures causes excessive dopaminergic activity. Disruption of the indirect pathway causing loss of inhibition to globus pallidum leads to hyperkinetic movements.⁷

Hemichorea often occurs acutely or subacutely and unilaterally with contralateral striatal infarcts, proved by CT and/or MRI brain scan or on autopsy. Vascular disease affecting the basal ganglia and adjacent white matter is one of the important causes of sporadic chorea, although proven cases are not common.⁹

As it is often difficult to prove, acute-onset generalised chorea has been recognised as the result of acute stroke only rarely.^{9 10} Vascular choreas are rarely a progressive condition. Some studies show that chorea could have spontaneous regression in about half of the patients, but others may have persistent symptoms and need to be treated.^{11 12}

Usual territory involved is supplied by the middle or posterior cerebral artery territory, although the lateral lenticulostriate artery or thalamogeniculate artery is often involved. Thalamic and lentiform nucleus lesions are most common. Less often subthalamic nucleus (STN) is affected, which can rarely give rise to ipsilateral chorea. Frontal, parietal, insular and temporal cortical lesions in the middle cerebral artery territory can rarely give rise to hemichorea from interruption of excitatory connections from the cerebral cortex to the basal ganglia, which may result in striatal dysfunction. In a few cases, generalised vascular chorea was related to bilateral basal ganglia lesions.¹²

Experimentally, chorea can be seen with lesion or inactivation or lesion of the STN, disinhibition of the globus pallidus pars externa (GPe) or by administering dopaminergic agents to parkinsonian primates. The activity of globus pallidus interna (GPi) neurons is decreased in primate models and patients with vascular hemichorea or apomorphine-induced chorea. The tonic output from motor portions of the GPi and Substantia Nigra pars reticulata (SNr) in the motor cortex and several premotor areas regulates the overall amount of movement.¹²

Striatum and STN receive topographically organised input from the cerebral cortex, whereas GPi and SNr provide basal ganglia output to the thalamus and brainstem. The connections between the striatum and these output structures are organised into a monosynaptic inhibitory (g-aminobutyric acid (GABA) ergic) direct pathway and polysynaptic excitatory indirect pathway that includes the GPe and the STN. Striatal neurons that give rise to direct and indirect pathways receive cortical input. An additional input to striatal neurons of the direct pathway comes from the intralaminar nuclei of the thalamus (ie, the centromedian and parafascicular nuclei). The GPi and SNr neurons give rise to GABAergic projections, which tonically inhibit thalamocortical projection neurons in the ventral anterior, ventrolateral and intralaminar nuclei of the thalamus and brainstem neurons because of high discharge rate. Activation of striatal neurons that give rise to the direct pathway is thought to inhibit GPi and SNr, whereas activation of striatal neurons that give rise to the indirect pathway excites GPi and SNr. Therefore, reduced basal ganglia output can translate into increased movement (chorea) because of disinhibition of thalamocortical projection neurons due to vascular lesions in the GPi, putamen, STN or intralaminar thalamic nuclei. In addition, interruption of excitatory connections from the cerebral cortex to the basal ganglia may also result in functional derangement of the striatum.¹²

Chorea usually presents earlier as compared with most other movement disorders (mean 4.3 days poststroke in one series) in stroke. Contrary to traditional concepts, a lesion of the subthalamic nucleus is usually not found in cases of vascular hemichorea/hemiballism. Other reported sites of lesions include the caudate nucleus, putamen, thalamus, globus pallidus, corona radiata, subcortical white matter and cortex.¹³⁻¹⁵ Most strokes causing hemichorea/hemiballism involve lesions in a common functional network connected to the posterolateral putamen.¹⁶

Mechanical thrombectomy is safe and of proven efficacy with significant functional improvement, as compared with medical therapy alone, in proximal large-vessel occlusion and in absence of a large infarct on baseline imaging. Thrombectomy is

associated with a shift toward better outcomes across the entire spectrum of disability.

Clot retrieval was achieved within 6 hours of the onset of symptoms and there was an inadequate response to intravenous thrombolysis by the time of groin puncture, as evident by continued symptoms. In addition, the occlusion was proved to be in proximal M2 segment of the middle cerebral artery on CT angiography. As stated earlier, there were no major new ischaemic changes on plain CT. All of these fulfilled the criteria¹⁷ for the patient being suitable for mechanical clot retrieval/thrombectomy.

Widely available methods (CT and CT angiography) were used to confirm large-vessel occlusion in our case. With a clear time of onset and no established infarct on CT head and definite symptoms, the presence of salvageable tissues seemed logical and no need for CT perfusion scan deemed necessary at that moment. With expert neurointerventional skill, it was possible to advance an ACE 68, which is a larger diameter catheter, into a distal M2 branch, that enabled strong suction for aspiration. Rapid decision and agreement on a clear plan of action led to rapid intervention and successful outcome, with only minimal established lacunar damage later demonstrated on re-imaging with some haemorrhagic imbibition. Although the flow could only be restored partially, autolysis of the clot probably minimised damage despite the fact that patient had a major intracerebral artery occlusion.

As ischaemia to the basal ganglia ameliorated, her movement disorder ceased, indicating although partial, but successful restoration of flow to the relevant neuronal circuits. Using local anaesthesia instead of general anaesthesia proved useful, as cessation of abnormal movement demonstrated a real-time evidence of restoration of blood flow. Involuntary movements are rare ischaemic stroke complication, although Ischaemic and haemorrhagic stroke are the most common causes of non-genetic chorea in the hospital population. Isolated case reports of choreoathetosis due to MRI-positive lesion in the right posterior limb of internal capsule surrounded by the thalamus, subthalamic nucleus and globus pallidus with enhancement by Gd-DTPA (gadolinium-diethylenetriamine penta-acetic acid or gadopentetate dimeglumine and Magnevist—a type of contrast agent for MRI) has been described. Surface EMG finding of irregular grouped discharge in short duration and grouped discharge in long duration in the involved muscle groups are compatible with choreoathetosis.¹⁸ In another series, patients presented with monochorea, hemiballism-hemichorea, choreoathetosis with subsequent painful arm dystonia and hand tremor and asterixis with MRI showing sparing of the subthalamic nucleus. Transient dyskinesias occurred at any time in the course of infarction (as a warning sign, as an associated symptom or during recovery). This study suggests that transient dyskinesias are mainly related to thalamic ischaemic injury and small vessels disease is the main aetiology.¹⁹ In addition to choreoathetosis, dysnomia, ataxia, sensory impairment and severe gait imbalance resulting from an isolated left lentiform nucleus-posterior limb of internal capsule lacunar stroke have also been reported.²⁰

This is a rare presentation of acute ischaemic stroke, not presenting with hypokinetic disorders, rather with abnormal movement, where a basal ganglia branch was occluded. Despite the controversies regarding using local or general anaesthetics during such procedure, use of local anaesthetics proved to be useful in this case. This case report contributes evidence to support the efficacy of neurovascular thrombectomy in patients with anterior circulation stroke even when presenting with unusual clinical symptoms. Thrombectomy, when performed, is an option in small vessel occlusion.

Learning points

- ▶ Although rare, hyperkinetic movement disorders can occur in the initial presentation of acute stroke. Acute stroke should be an important differential diagnosis for acute-onset chorea or choreoathetosis.
- ▶ Thrombectomy, when suitable and possible, can provide quick symptomatic relief and minimise residual disability depending on the amount of brain tissue rescued in time.
- ▶ Managing a thrombectomy procedure with local anaesthetics can give real-time monitoring of a successful outcome.
- ▶ In the management of acute stroke, 'time is brain'. Therefore, quick, decisive action must be undertaken with a clear management protocol in place.

Acknowledgements The authors give special thanks to Professor Iris Q Grunwald who promptly reviewed the initial scan images and decided and subsequently performed the thrombectomy procedure for the patient depicted in our case report.

Contributors AM received the patient in Southend University Hospital Accident and Emergency and activated stroke pathway. IQG reviewed the scans and decided and performed thrombectomy for the patient. AM wrote the case report, to which EB and PCG helped and contributed.

Funding The authors have not declared a specific grant for this research from any funding agency in the public, commercial or not-for-profit sectors.

Competing interests None declared.

Patient consent Obtained.

Provenance and peer review Not commissioned; externally peer reviewed.

REFERENCES

- 1 Defebvre L, Krystkowiak P. Movement disorders and stroke. *Rev Neurol* 2016;172:483–7.
- 2 Ghika-Schmid F, Ghika J, Regli F, et al. Hyperkinetic movement disorders during and after acute stroke: the Lausanne Stroke Registry. *J Neurol Sci* 1997;146:109–16.
- 3 World Health Organization. WHO Surgical Safety Checklist [Internet]. 2018 <http://www.who.int/patientsafety/topics/safe-surgery/checklist/en/> (cited 12 Nov 2018).
- 4 TIMI Study Group. The Thrombolysis in Myocardial Infarction (TIMI) trial. Phase I findings. *N Engl J Med* 1985;312:932–6.
- 5 Higashida RT, Furlan AJ, Roberts H, et al. Trial design and reporting standards for intra-arterial cerebral thrombolysis for acute ischaemic stroke. *Stroke* 2003;34:e109–37.
- 6 Bansil S, Prakash N, Kaye J, et al. Movement disorders after stroke in adults: a review. *Tremor Other Hyperkinet Mov* 2012;2:tre-02-42-195-1.
- 7 Cardoso F, Seppi K, Mair KJ, et al. Seminar on choreas. *Lancet Neurol* 2006;5:589–602.
- 8 Lee MS, Marsden CD. Movement disorders following lesions of the thalamus or subthalamic region. *Mov Disord* 1994;9:493–507.
- 9 Bhatia KP, Lera G, Luthert PJ, et al. Vascular chorea: case report with pathology. *Mov Disord* 1994;9:447–50.
- 10 Sethi KD, Nichols FT, Yaghamai F. Generalized chorea due to basal ganglia lacunar infarcts. *Mov Disord* 1987;2:61–6.
- 11 Handley A, Medcalf P, Hellier K, et al. Movement disorders after stroke. *Age Ageing* 2009;38:260–6.
- 12 Zijlmans JC. Vascular chorea in adults and children. *Handb Clin Neurol* 2011;100:261–70.
- 13 Chung SJ, Im JH, Lee MC, et al. Hemichorea after stroke: clinical-radiological correlation. *J Neurol* 2004;251:725–9.
- 14 Postuma RB, Lang AE. Hemiballism: revisiting a classic disorder. *Lancet Neurol* 2003;2:661–8.
- 15 Alarcón F, Zijlmans JC, Dueñas G, et al. Post-stroke movement disorders: report of 56 patients. *J Neurol Neurosurg Psychiatry* 2004;75:1568–74.
- 16 Laganere S, Boes AD, Fox MD. Network localization of hemichorea-hemiballismus. *Neurology* 2016;86:2187–95.
- 17 Specialised Commissioning Team. *Mechanical thrombectomy for acute ischaemic stroke (all ages)* [Internet]. 1st ed: NHS England, 2018. Available from: <https://www.england.nhs.uk/publication/clinical-commissioning-policy-mechanical-thrombectomy-for-acute-ischaemic-stroke-all-ages/>. (cited 12 Nov 2018).
- 18 Ito T, Jijiwa M, Ando Y, et al. [A patient with choreoathetosis of the left upper extremity due to acute cerebral infarction]. *Rinsho Shinkeigaku* 2000;40:184–6.
- 19 Milandre L, Brosset C, Gabriel B, et al. [Transient involuntary movement disorders and thalamic infarction]. *Rev Neurol* 1993;149:402–6.
- 20 Galbreath AD, Goldstein LB. Dysnomia, ataxia, choreoathetosis, sensory impairment, and gait imbalance after lentiform nucleus stroke. *J Stroke Cerebrovasc Dis* 2009;18:494–6.

Copyright 2019 BMJ Publishing Group. All rights reserved. For permission to reuse any of this content visit <https://www.bmj.com/company/products-services/rights-and-licensing/permissions/>
BMJ Case Report Fellows may re-use this article for personal use and teaching without any further permission.

Become a Fellow of BMJ Case Reports today and you can:

- ▶ Submit as many cases as you like
- ▶ Enjoy fast sympathetic peer review and rapid publication of accepted articles
- ▶ Access all the published articles
- ▶ Re-use any of the published material for personal use and teaching without further permission

For information on Institutional Fellowships contact consortiasales@bmjgroup.com

Visit casereports.bmj.com for more articles like this and to become a Fellow