



# Intracranial stenting after tumor exeresis complicated by delayed kinking of the middle cerebral artery

Davide Simonato<sup>1</sup> · Joseph Domenico Gabrieli<sup>2</sup> · Giacomo Cester<sup>2</sup> · Alessandro Della Puppa<sup>3</sup> · Francesco Causin<sup>2</sup>

Received: 15 November 2018 / Accepted: 23 January 2019  
© Springer-Verlag GmbH Austria, part of Springer Nature 2019

## Abstract

During intracranial tumor resection, the delayed kinking of a major encased vessel has never been described in literature. We present a case which required urgent endovascular treatment performed through a stent positioning. A patient was hospitalized with symptomatic sphenoid meningioma in the left middle cranial fossa. Twelve days after surgery, right-sided hemiplegia and aphasia occurred. Digital subtraction arteriography revealed a kinking of the M1 segment of the left middle cerebral artery and diffuse vasospasm. At first, intra-arterial nimodipine has been administered, obtaining the remission of the vasospasm. Secondly, a stent was positioned to treat the kinking, achieving a complete flow restoration.

**Keywords** Kinking · Vasospasm · Skull-base · Delayed cerebral ischemia

## Introduction

Exeresis of skull-base tumors requires precise dissection in a region characterized by complex anatomical relationships which may be altered by the underlying pathology. As shown by this case, the pathological alteration of these relationships may cause delayed complications even in the setting of a technically uneventful surgery.

We show a case of sphenoid meningioma resection complicated by a delayed middle cerebral artery stroke, related to the kinking of the main arterial trunk that was previously encased and elongated by the lesion. Endovascular treatment was performed to reestablish vessel patency.

## Case presentation

A 70-year old man presented to our department with a symptomatic meningioma of the left sphenoid wing with worsening symptoms since 1 year ultimately causing severe hemiparesis of the right side and mixed aphasia.

Preoperative imaging showed a large extra-axial lesion of the left sphenoid wing dislocating the supraclinoid internal carotid artery (ICA) and middle cerebral artery (MCA) (Fig. 1a) and encasing the M1 segment, which appeared elongated (Fig. 1b).

Surgical exeresis was performed through a left fronto-pterional craniotomy and allowed complete gross removal of the lesion with preservation of the MCA branches including the arachnoid layer between the meningioma and the artery.

Surgery was clinically uneventful and subsequent clinical course revealed a slow gradual improvement of the symptoms with partial recovery of the hemiparesis and reduction of the aphasia; post-operative imaging confirmed complete gross removal of the lesion, absence of ischemic complications, and mild hemorrhagic staining of the surgical bed; histological analysis confirmed the presence of a meningioma (WHO grade II).

Twelve days after surgery, the patient unexpectedly developed a rapidly progressing right-sided hemiparesis and recurrence of aphasia; following bedside transcranial echo Doppler examination, which revealed MCA flow acceleration, MRI was urgently performed and documented the presence of a

This article is part of the Topical Collection on *Vascular Neurosurgery - Ischemia*

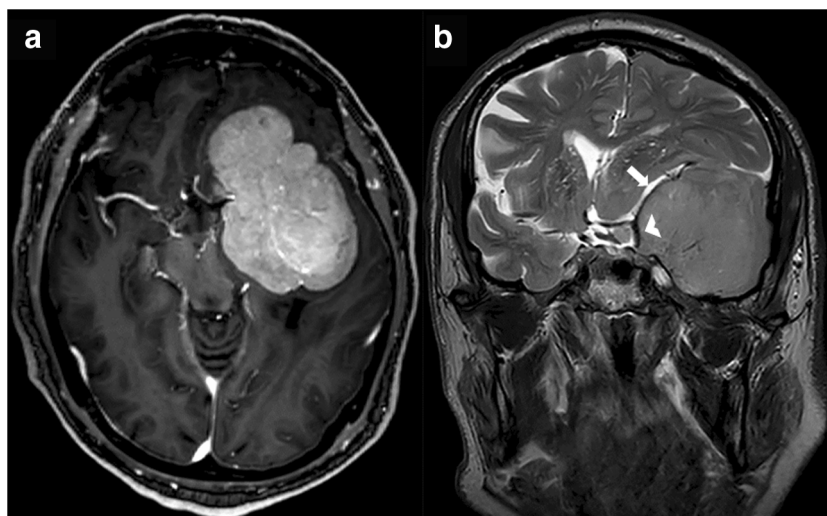
✉ Davide Simonato  
david.med4@gmail.com

<sup>1</sup> Institute of Radiology, University of Padua, Via Giustiniani 2, 35128 Padua, Italy

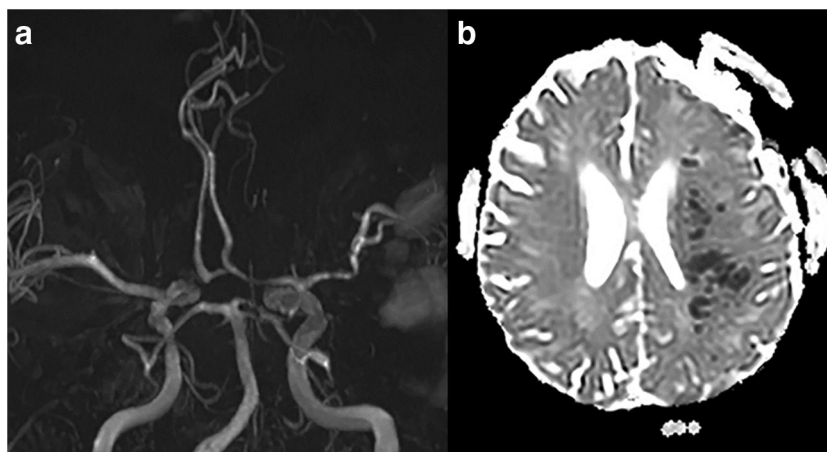
<sup>2</sup> Neuroradiology Unit, University Hospital of Padova, Padua, Italy

<sup>3</sup> Neurosurgery Unit, University Hospital of Padova, Padua, Italy

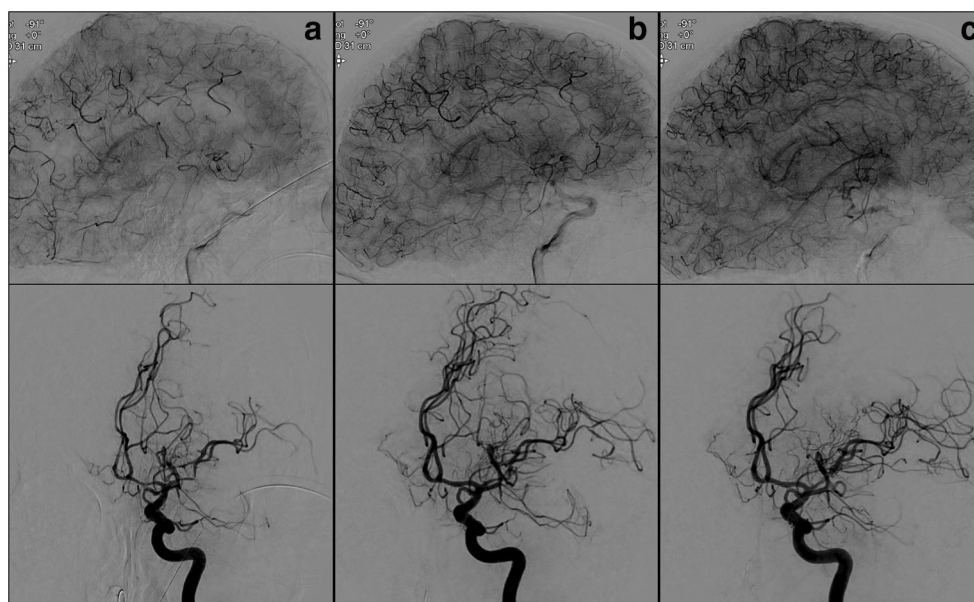
**Fig. 1** Preoperative MRI: axial enhanced-T1w sequences shows a large sphenoid wing meningioma (80 × 60 × 50 mm) on the left (a); in the coronal turbo spin echo sequences, the lesion seems to dislocate the supraclinoid ICA (arrowhead) and MCA (white arrow) (b)



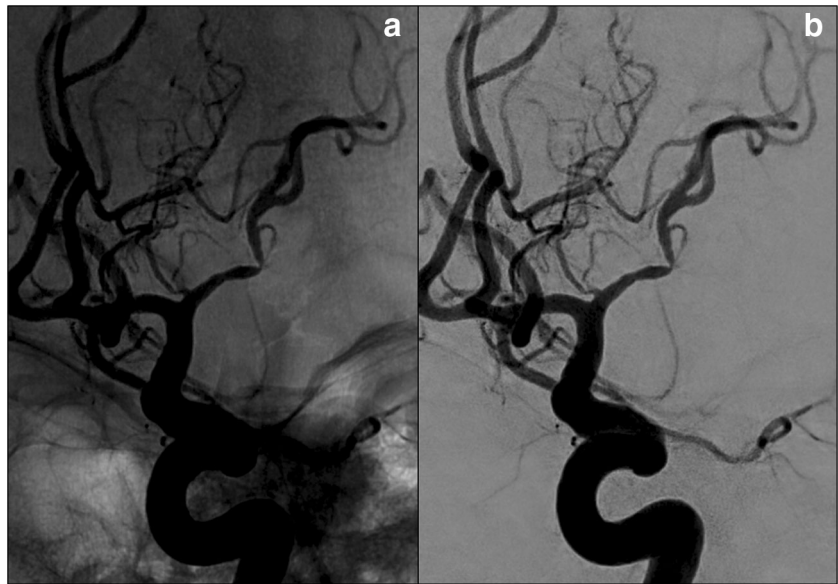
**Fig. 2** MRI after surgery: 3D Time-of-Flight sequences shows a vasospasm of the proximal segment of the anterior cerebral arteries (ACA) and the left middle cerebral artery (MCA) (a); apparent diffusion maps depict a recent watershed ischemia between the left ACA and MCA (b)



**Fig. 3** Digital subtraction angiography (DSA) before (a), after 24 h-intra-arterial bolus of nimodipine (b) and following acute stent release (c). The comparison outlines a gradual improvement of the brain parenchymography as well as a significant increase of the ACA and the left MCA calibers



**Fig. 4** Unsubtracted (a) and subtracted (b) digital angiograms after intra-arterial nimodipine administration show the persistence of the left M1 stenosis with kinking-like features



watershed ischemia (Fig. 2b) associated with an irregular stenosis of the M1 segment (Fig. 2a).

The patient was intubated for the worsening of psychomotor agitation and transferred to the angio suite where digital subtraction angiography (DSA) confirmed the presence of a moderate vasospasm of the left A1 and M1 segments and a vascular kink determining a severe focal stenosis of the distal M1 segment associated with a diffuse delay of the cerebral parenchymography of the MCA territory (Fig. 3a). Local intra-arterial treatment was performed via the injection of 1.6 mg/10 min of nimodipine and followed by systemic treatment with 2 mg/h intravenous drip. A second DSA performed at 24 h documented remission of the vasospasm and partial recovery of the brain parenchymography (Fig. 3b), however persistence of the vascular kink (Fig. 4) and residual delayed cerebral parenchymography in the fronto-opercular and fronto-parietal regions prompted us for further treatment.

A 6F guide catheter (Envoy, Codman Neurovascular, Raynham, MA, USA) was positioned in the left ICA and a coaxial microcatheter (SL10, Stryker Neurovascular, Fremont, CA, USA) was driven through the stenosis with the aid of a microguidewire 0.014 in. (Neuroscout standard®, Codman Neurovascular, Raynham, MA, USA); subsequently, the microcatheter was exchanged with a larger one (Headway® 21 MicroVention Inc. CA, USA) in order to deliver the stent (Solitaire™ AB 4–20, ev3 Neurovascular, Irvine, CA, USA) across the kinking (Fig. 5). Rectification and complete recanalisation of the artery were obtained as well as a further improvement of the parenchymography (Fig. 3c), thus the stent was permanently released (Fig. 6). Antiplatelet management followed our institutional protocol for acute stenting (0.4- $\mu$ g/kg/min loading dose of tirofiban for 30 min, followed by 0.10- $\mu$ g/kg/min and imbrication with 100 mg aspirin/day and 75 mg clopidogrel/day the following

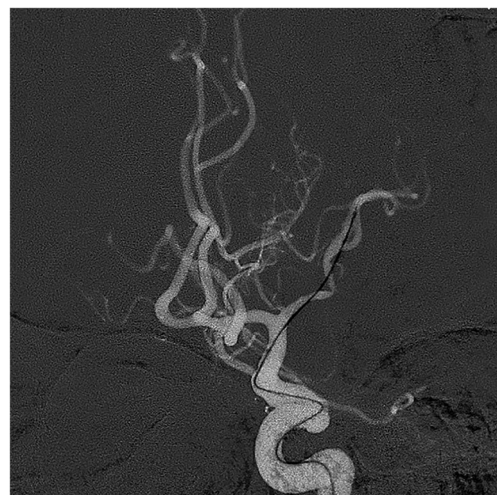day); subsequently dual antiplatelet therapy was maintained for 6 months followed by monoantiaggregation.

Post-operative imaging revealed stability of the known watershed ischemic lesions without appearance of new ischemic lesions; clinical course revealed persistence of right side hemiparesis and mild aphasia without new neurological deficits.

The patient was referred for professional rehabilitation; his modified Rankin Scale score at discharge was evaluated at 3.

## Discussion

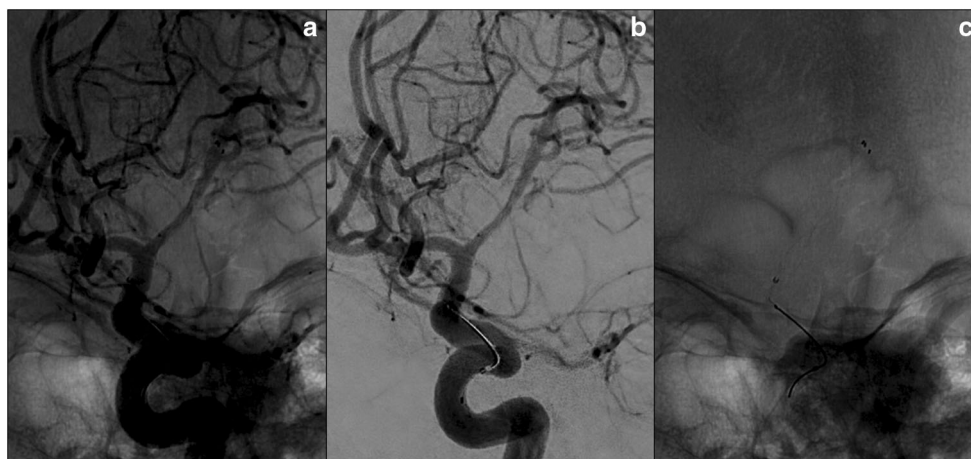Kinking of intracranial vessels is a very rare occurrence, mainly reported intraoperatively during neurovascular surgery such as aneurysm clipping [5].



**Fig. 5** Endovascular procedure. Roadmap images of the kink during the drive of the microwire and the microcatheter beyond the stenosis, in order to perform the stent-positioning



**Fig. 6** Unsubtracted (a) and subtracted (b) digital angiograms after the stenting procedure: the device was properly placed (c) from the origin of the left M1 segment to the proximal trait of the superior branch of MCA, solving the kinking



To our knowledge, this is the first report of a delayed symptomatic intracranial vascular kinking following intracranial surgery.

Interestingly, the arterial kink corresponded to the left M1 segment, which appeared to be elongated by the mass effect of the tumor. It is reasonable to hypothesize that chronic elongation may cause unwanted tortuosity (and eventual kinking) once the mass is removed and the artery restores to its original location.

A retrospective review of sphenoid wing meningiomas found the degree of vessel encasement to be predictive of postoperative ischemic complications and suggested that it could be related to intraoperative traction injuries induced by the adherence of the tumor to the arterial wall [4].

Our case suggests that also chronic elongation, which is likely more frequent in association with large, vessel-encasing lesions, may have pathological consequences that may explain at least some ischemic complications.

Concerning the timing of the occurrence of the ischemic complication, it should be noted that it appeared concurrently with vasospasm which is known to occur in approximately 1.9% of cases, following skull-base tumor surgery [3]; nevertheless, progressive healing processes in the surgical bed may also justify a delayed timing.

It is likely that the etiology of the stroke detailed in our case was mixed, since both the kinking and the vasospasm have a potential for flow reduction and since the infusion of nimodipine had a partial but incomplete effect on the recovery of cerebral parenchymography.

Treatment of vasospasm following tumor resection may be similar to that of post-SAH vasospasm; nevertheless, some authors caution that the vasoactive materials from the tumor could interfere with the drugs' efficacy [1, 2]. Treatments for intracranial vessel kinking have been proposed in the setting of intraoperative kinking during neurovascular surgery and include the placement of space-occupying prosthesis that restores the proper vessel geometry (5); not unlikely our treatment was aimed to restore the proper vascular geometry that, in this case, was obtained through the positioning of endovascular prosthesis.

Management of antiplatelet agents remains a concern in the post-operative period, thus risks should be weighted according to the expected benefits.

This case suggests that large skull-base lesions causing vessel elongation may cause delayed complications; knowledge of this occurrence among neurovascular specialists may help in patient care.

## Compliance with ethical standards

**Conflicts of interest** The authors declare that they have no conflict of interest.

**Ethical approval** All procedures performed in studies involving human participants were in accordance with the ethical standards of the institutional and/or national research committee and with the 1964 Helsinki declaration and its later amendments or comparable ethical standards.

**Informed consent** Informed consent was obtained from the individual participant included in the study.

**Publisher's note** Springer Nature remains neutral with regard to jurisdictional claims in published maps and institutional affiliations.

## References

- Alotaibi NM, Lanzino G (2013) Cerebral vasospasm following tumor resection. *J Neurointerv Surg* 5(5):413–418
- Aoki N, Oritano TC, al-Mefty O (1995) Vasospasm after resection of skull base tumors. *Acta Neurochir* 132(1–3):53–58
- Bejjani GK, Sekhar LN, Yost AM, Bank WO, Wright DC (1999) Vasospasm after cranial base tumor resection: pathogenesis, diagnosis, and therapy. *Surg Neurol* 52(6):577–583 discussion 583
- McCracken DJ, Higginbotham RA, Boulter JH, Liu Y, Wells JA, Halani SH et al (2017) Degree of vascular encasement in sphenoid wing meningiomas predicts postoperative ischemic complications. *Neurosurgery* 80(6):957–966
- Motoyama Y, Tanaka Y, Gurung P, Nakagawa I, Park Y-S, Nakase H (2016) A simple bracing technique to correct kinking of arterial branches to avoid ischemic sequelae during neurovascular surgery. *Surg Neurol Int* 7:8