

Case Report

MELAS syndrome with m.4450 G > A mutation in mitochondrial tRNA^{Met} gene

Mari Kuwajima^{a,1}, Masahide Goto^{a,1}, Koyuru Kurane^a, Hiroko Shimbo^b
Narumi Omika^a, Eriko F. Jimbo^a, Kazuhiro Muramatsu^a, Makiko Tajika^c
Masaru Shimura^c, Kei Murayama^c, Kenji Kurosawa^b, Takanori Yamagata^a,
Hitoshi Osaka^{a,*}

^a Department of Pediatrics, Jichi Medical University, Japan

^b Department of Genetics, Kanagawa Children's Medical Center, Yokohama, Kanagawa, Japan

^c Department of Metabolism, Chiba Children's Hospital, Japan

Received 27 November 2018; received in revised form 2 January 2019; accepted 22 January 2019

Abstract

Mutations in the mitochondrial tRNA^{Met} gene have been reported in only five patients to date, all of whom presented with muscle weakness and exercise intolerance as signs of myopathy. We herein report the case of a 12-year-old girl with focal epilepsy since the age of eight years. At age 11, the patient developed sudden visual disturbances and headaches accompanied by recurrent, stroke-like episodes with lactic acidosis (pH 7.279, lactic acid 11.6 mmol/L). The patient frequently developed a delirious state, exhibited regression of intellectual ability. Brain magnetic resonance imaging revealed high-intensity signals on T2-weighted images of the left occipital lobe. Mitochondrial gene analysis revealed a heteroplasmic m.4450G > A mutation in the mitochondrial tRNA^{Met}. The heteroplasmic rate of the m.4450G > A mutation in blood, skin, urinary sediment, hair, saliva, and nail samples were 20, 38, 59, 41, 27, and 35%, respectively. The patient's fibroblast showed an approximately 53% reduction in the oxygen consumption rate, compared to a control, and decreased complex I and IV activities. Stroke-like episodes, lactic acidosis, encephalopathy with brain magnetic resonance imaging findings, and declined mitochondrial function were consistent with mitochondrial myopathy, encephalopathy, lactic acidosis, and stroke-like episodes (MELAS) syndrome. To our knowledge, the findings associated with this first patient with MELAS syndrome harboring the m.4450G > A mutation in mitochondrial tRNA^{Met} expand the phenotypic spectrum of tRNA^{Met} gene.

© 2019 The Japanese Society of Child Neurology. Published by Elsevier B.V. All rights reserved.

Keywords: MELAS syndrome; Lactic acidosis; Encephalopathy; MT-TM; m.4450G > A

1. Introduction

Mitochondrial DNA (mtDNA) mutations are associated with various mitochondrial disorders; over 600

disease-associated mtDNA point mutations have been reported to date [1]. Mitochondrial myopathy, encephalopathy, lactic acidosis, and stroke-like episodes (MELAS) syndrome is one of the most frequent maternally inherited mitochondrial disorders [2]. Eighty percent of patients with MELAS syndrome have an A-to-G substitution at nucleotide 3243 in *MT-TL1* encoding tRNA^{Leu} in the mtDNA [3]. Rare mutations in other

* Corresponding author at: Department of Pediatrics, Jichi Medical University, 2411-1 Yakushiji, Shimotsuke, Tochigi 329-0498, Japan.

E-mail address: hosaka@jichi.ac.jp (H. Osaka).

¹ These authors contributed to this article equally.

mitochondrial genes reported to cause MELAS syndrome include *MT-TL2* encoding tRNA^{Leu(CUN)}, *MT-TK* encoding tRNA^{Lys}, *MT-TH* encoding tRNA^{His}, *MT-TQ* encoding tRNA^{Gln}, *MT-TF* encoding tRNA^{Phe}, *MT-TV* encoding tRNA^{Val}, *MT-ND1*, *MT-ND4*, *MT-ND5*, and *MT-ND6* encoding subunits of complex I; *MT-CO2* and *MT-CO3* encoding subunits of complex IV; and *MT-CYB* encoding a subunit of complex III [3]. Since point mutations in the mtDNA are associated with diverse phenotypes, genotype-phenotype correlations are imprecise. Individuals who carry the same mutation often have diverse disease presentations, and different mutations within the same tRNA gene can differ in both clinical symptoms and severity [4].

The five pathogenic mutations in *MT-TM* encoding tRNA^{Met} reported to date are m.4403G > A [5], m.4409T > C [6], m.4415A > G [7], m.4437C > T [8], and m.4450G > A [9]. Phenotypes of patients with *MT-TM* mutations were muscle weakness and exercise intolerance as signs of myopathy; however, none of the patients had the MELAS phenotypes. We herein describe the first patient with the m.4450G > A mutation in *MT-TM* who exhibited the MELAS phenotype, including stroke-like episodes, headache, epilepsy, and intellectual disability.

2. Case presentation

The patient was a 12-year-old girl born to noncon-sanguineous parents. Her maternal family members, including the mother, had no symptoms associated with mitochondrial diseases. Her delivery was uneventful, and her development and growth were normal until eight years of age, at which time she suffered from sudden visual disturbance and a cluster of generalized onset tonic-clonic seizures. She became unconscious and was admitted to our hospital. Although routine laboratory test results were normal, including serum lactate and pyruvic acid (1.8 and 0.09 mmol/L; normal range 0.4–1.8 and 0.003–0.1 mmol/L, respectively), lactate and pyruvic acid levels in the cerebrospinal fluid were elevated (7.2 and 0.3 mmol/L; normal range 1.5–2.3 and 0.07–0.09 mmol/L, respectively). Bilateral basal ganglia calcification was observed by brain computed tomography (Fig. 1A), but there were no abnormal brain magnetic resonance imaging (MRI) findings (Fig. 1B). Her academic achievement declined, and her intelligence quotient was assessed as 60 on the Wechsler intelligence scale for children-IV.

At the age of 11, the patient complained of blurry vision in left side and had lactic acidosis (pH 7.279, lactic acid 11.6 mmol/L). Brain MRI on T2-weighted images, fluid-attenuated inversion recovery, and diffusion-weighted imaging showed high-intensity signals at gyrus through cortex to subcortex in the left occipital lobe (Fig. 1C). These findings suggested

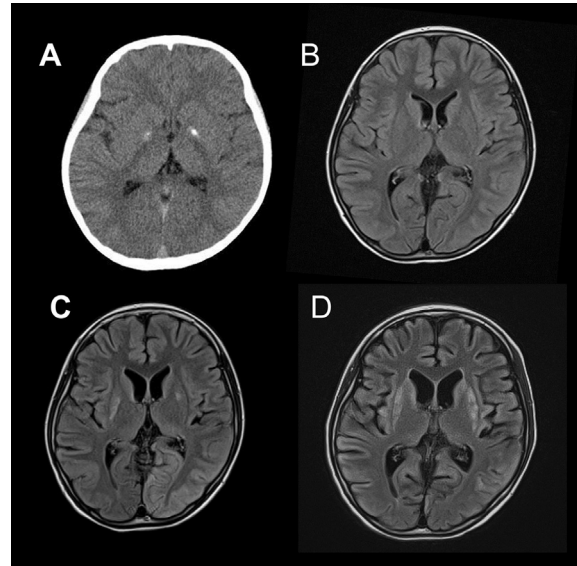


Fig. 1. Brain computed tomography (A) and fluid-attenuated inversion recovery magnetic resonance imaging (B–D) images of the patient. A) there was a high-intensity signal in the bilateral dorsal putamen, which is predominant on the left side at the eight years-old, B) there was no significant findings at the eight years-old, C) note left occipital lesion with high signal intensity, whose distribution does not conform to vascular territories at the 11 years-old, D) the putamen, caudate lesion, and cerebral cortex atrophy progressed at the 12 years-old.

stroke-like attacks, and then edaravone and L-arginine were infused. Two days later, despite persistent right homonymous hemianopsia, her visual acuity improved to counting fingers. Although consciousness was restored, there was occasional relapse of intermittent conjugate gaze deviation to the right. Electroencephalography revealed repetitive 5-Hz sharp waves in the left occipital areas (Supple. Fig. 1). At the time of her hospital discharge on day 14, the right homonymous hemianopsia had disappeared, and her eyesight improved; however, her vocabulary and comprehension levels were worse than before admission.

At the age of 12, the patient frequently developed a delirious state, exhibited regression of intellectual ability, and suffered from frequent headaches. Focal epilepsy was treated with carbamazepine and levetiracetam. Muscle weakness, short stature, cardiac dysfunction, hearing loss, or peripheral neuropathy was not observed. Brain MRI showed the putamen and caudate lesion and the progression of cerebral atrophy (Fig. 1D).

Stroke-like episodes, lactic acidosis, and encephalopathy with brain MRI findings were consistent with MELAS syndrome. After informed consent was obtained from the patient and her family and linkable anonymizing, mitochondrial whole genome sequencing was performed, which revealed 44 benign or non-pathogenic polymorphism. The study was approved by the ethics committee of Jichi Medical

University and Kanagawa Children's Medical Center. Among these polymorphisms, only the m.4450 G > A mutation was identified as a possible pathogenic mutation in tRNA^{Met}. The other 43 single nucleotide polymorphisms (SNPs) were reported as benign or non-pathogenic variants [1] (Supple. Table 1). The Sanger sequencing for *MT-TM* were performed using PCR products from linear range of PCR cycle. Heteroplasmic rate of the m.4450G > A mutation were semi-quantitatively calculated by the comparison for chromatographic areas; blood, skin, urinary sediment, hair, saliva, and nail samples were 20, 38, 59, 41, 27, and 35%, respectively (Fig. 2). The heteroplasmic rate were confirmed by a ratio of the read number with this mutation over the total read number by MySeq (Illumina, San Diego, CA, USA). The oxygen consumption rate, measured with an extracellular flux analyzer (Seahorse XF96; Agilent, Santa Clara, CA, USA), revealed a 53% reduction in the respiration rate of the patient fibroblasts compared to the control. Analysis of the cultured fibroblasts for respiratory chain enzyme activity levels revealed decreased complex I and IV activities (16.0 and 8.0% of the control; Supple. Table 2).

3. Discussion

We presented the first case of a patient with MELAS harboring the pathogenic m.4450G > A mutation in mitochondrial tRNA^{Met} from several tissues. She exhibited declined mitochondrial function; reduced oxygen consumption rate, and diminished respiratory chain complex enzyme activity levels. The mitochondrial whole genome sequencing detected m.4450G > A mutation as the only possible pathogenic mutation among the 44 identified SNPs (MITOMAP). Highest mutation rate of 59% was observed in the urinary sediment [10]. Invasive muscle biopsy was not performed because the patient had no muscle weakness or exercise intolerance.

To our knowledge, mutations in the *MT-TM* gene encoding tRNA^{Met} were reported in five cases to date [5–9] (Table 1). Except for the current patient, all patients with a mutation in the *MT-TM* gene had myopathy but not a neurological phenotype. Muscle biopsies showed mostly mitochondrial abnormalities, but COX-negative fibers were present in some cases. The biochemical consequences of the mutations also differed among the reported cases. Patient 3 [7] (Table 1) with two mutations in the *MT-TM* and COX III genes, had muscle weakness, lactic acidosis, and autoimmune polyendocrinopathy type 2. Because two mutations co-existed, the clinical relevance of either mutation could not be determined. It is possible that patient 4 [8] could have developed the MELAS phenotype, eventually because of the presence of epilepsy and hearing disability. Patient 5 [9] with the m.4450G > A mutation, the same mutation harbored by the current patient, had myopathy but no neurological phenotype. The only features patient 5 and the current patient had in common were mild intellectual disability and reduced complex I and IV activity levels. The mutation load of patient 5 was 67% in muscle samples, and the single-fiber PCR using COX-negative fiber ratio was >90%, suggesting a strong muscle phenotype and the pathogenicity by the m.4450G > A mutation. The current patient with the m.4450G > A mutation load of 59% in urinary sediment at the most manifested the MELAS phenotype but did not exhibit myopathy or other organ dysfunctions. This may be explained by threshold effects in different organ and we speculate that the mutational load was high in the affected central nervous system lesions in the current patient [11]. Moreover, the m.4450G > A mutation was previously described in a patient with splenic lymphoma [12] who did not have muscle or neurological symptoms, and the potential link between the m.4450G > A mutation and lymphoid proliferation remains unclear.

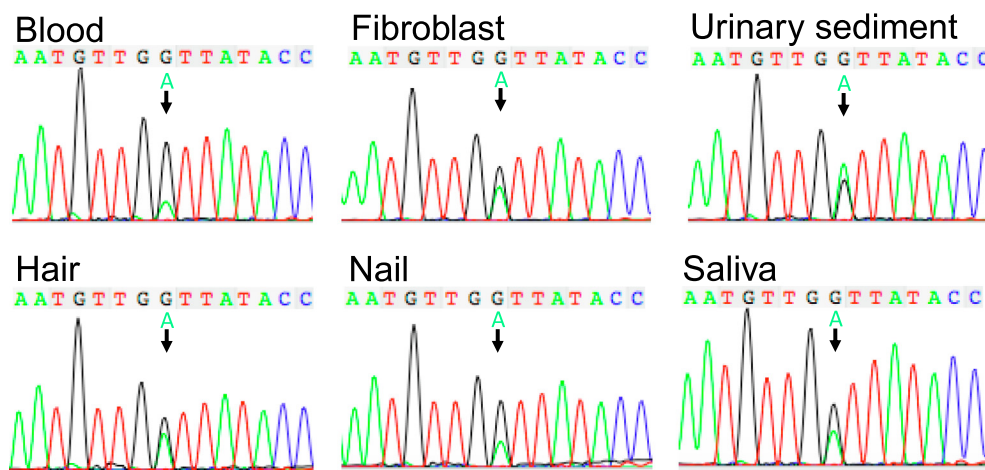


Fig. 2. Direct sequencing of *MT-TM* gene. A sequencing chromatogram of the *MT-TM* gene shows the heteroplasmic m.4450G > A mutation in the control sample and in the blood, fibroblast of skin, urinary sediment, hair, nail, and saliva from the patient.

Table 1
Reported patients with mutations in the *MT-TM* gene encoding tRNA^{Met}.

Cases	1	2	3	4	5	The present case
References	Peverelli et al. [5]	Vissing et al. [6]	Bortot et al. [7]	Tang et al. [8]	Born et al. [9]	
Base change (<i>MT-TM</i>)	m.4403G > A	m.4409 T > C	m.4415A > G m.9972A > G in COX III gene	m.4437C > T	m.4450G > A	m.4450G > A
<i>Clinical features</i>						
Onset (years), sex	56, female	10, girl	10, NA	13, girl	10, girl	8, girl
Muscle weakness	Yes	Yes	Yes	Yes	Yes	No
Epilepsy	No	No	No	Yes	No	Yes
Stroke-like episode	No	No	No	No	No	Yes
Intellectual disability	No	No	No	No	Yes	Yes
Others	NA	Short stature	Autoimmune polyendocrine syndrome 2	Hearing loss	NA	NA
<i>Laboratory data</i>						
Creatine kinase (U/L)	600–700	NA	Normal	NA	Normal	38
Lactic acid (mmol/L)	0.5	1.9	11.4	Lactic acidosis	5.3	11.6
Brain MRI	Moderate global cortical atrophy	Normal	Normal	NA	Normal	High-intensity signal in left occipital lobe
<i>Respiratory chain enzyme activity level</i>						
Complex I	Slightly decreased	NA	1.15 (3.09 + 1.15)	NA	0.02 (0.19–0.54)	16%
Complex II	Normal	NA	0.05 (0.07 + 0.02)	NA	0.34 (0.24–0.50)	54%
Complex III	Normal	NA	0.02 (0.05 + 0.02)	NA	0.53 (0.72–2.14)	66%
Complex IV	Normal	NA	0.02 (0.2 + 0.1)	23%	0.1 (2.2–5.0)	8%
Citrate synthase	Mildly increase	NA	27.9 (14.48 + 3.86)	NA	1002 (127–477)	66%
<i>Muscle biopsy</i>						
Ragged-red fiber	Yes	Yes	Yes	NA	NA	NA
COX-negative	40% variable	50%	93%	NA	90%	NA
<i>Mutation load</i>						
Muscle	63%	77%	99%	NA	67%	NA
Blood	NA	8%	0%	Homoplasmy	NA	20%
Skin	NA	NA	2%	NA	10%	38%
Urinary sediment	NA	NA	5%	NA	NA	59%
Hair	NA	0%	0%	NA	NA	41%
Saliva	NA	NA	NA	NA	NA	35%
Nail	NA	NA	NA	NA	NA	27%

MRI, magnetic resonance imaging; COX, cytochrome *c* oxidase; NA, not available.

In conclusion, we reported one patient with MELAS phenotype and the m.4450G > A mutation in the *MT-*TM** gene appears to be associated with the MELAS phenotype.

Acknowledgements

This work was supported by JSPS KAKENHI grant, number 15552768-56006973, to H.O. and by the Project for Health Research on Infants, Children, Adolescents, and Young Adults grant from the Agency of Medical Research and Development to T.Y.

Appendix A. Supplementary data

Supplementary data to this article can be found online at <https://doi.org/10.1016/j.braindev.2019.01.006>.

References

- [1] Refer to “MITOMAP A human mitochondrial genome database”: <https://www.mitomap.org/MITOMAP>. Accessed Nov, 2018.
- [2] Pavlakis SG, Phillips PC, DiMauro S, De Vivo DC, Rowland LP. Mitochondrial myopathy, encephalopathy, lactic acidosis, and stroke-like episodes: a distinctive clinical syndrome. *Ann Neurol* 1984;16(Suppl 1):481–8.
- [3] El-Hattab AW, Adesina AM, Jones J, Scaglia F. MELAS syndrome: clinical manifestations, pathogenesis, and treatment options. *Mol Genet Metab* 2015;116:4–12.
- [4] Greaves LC, Reeve AK, Taylor RW, Turnbull DM. Mitochondrial DNA and disease. *J Pathol* 2012;226:274–86.
- [5] Peverelli L, Gold CA, Naini AB, Tanji K, Akman HO, Hirano M, et al. Mitochondrial myopathy with dystrophic features due to a novel mutation in the *MTTM* gene. *Muscle Nerve* 2014;50:292–5.
- [6] Vissing J, Salamon MB, Arlien-Soborg P, Norby S, Manta P, DiMauro S, et al. A new mitochondrial tRNA(Met) gene mutation in a patient with dystrophic muscle and exercise intolerance. *Neurology* 1998;50:1875–8.
- [7] Bortot B, Barbi E, Biffi S, Angelini C, Faleschini E, Severini GM, et al. Two novel cosegregating mutations in tRNAMet and COX III, in a patient with exercise intolerance and autoimmune polyendocrinopathy. *Mitochondrion* 2009;9:123–9.
- [8] Tang S, Wang J, Zhang W, Li F, Landsverk M, Cui H, et al. Transition to next generation analysis of the whole mitochondrial genome: a summary of molecular defects. *Hum Mutat* 2013;34:882–93.
- [9] Born AP, Duno M, Rafiq J, Risom L, Wibrand F, Ostergaard E, et al. A mitochondrial tRNA(Met) mutation causing developmental delay, exercise intolerance and limb girdle phenotype with onset in early childhood. *Eur J Paediatr Neurol* 2015;19:69–71.
- [10] Whittaker RG, Blackwood JK, Alston CL, Blakely EL, Elson JL, McFarland R, et al. Urine heteroplasmy is the best predictor of clinical outcome in the m.3243A>G mtDNA mutation. *Neurology* 2009;10:568–9.
- [11] Rossignol R, Faustin B, Rocher C, Malgat M, Mazat JP, Letellier T. Mitochondrial threshold effects. *Biochem J* 2003;370:751–62.
- [12] Lomès A, Bories D, Girodon E, Frachon P, Ngo MM, Breton-Gorius J, et al. The first pathogenic mitochondrial methionine tRNA point mutation is discovered in splenic lymphoma. *Hum Mut* 1998(Suppl 1):175–83.