

Multifocal Stroke From Ozone Gas Emboli

Paul R. Freund, MD, Laila Alshafai, MD, Edward A. Margolin, MD

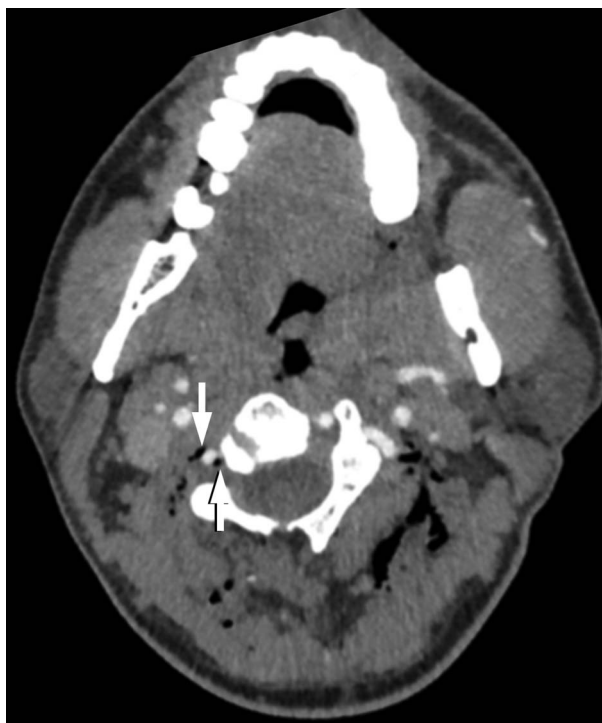

FIG. 1. Axial computed tomographic angiogram demonstrates multiple foci of gas in the paravertebral soft tissue. There are 2 foci of gas (arrows) adjacent to the right vertebral artery.

Abstract: A 34-year-old man with chronic neck pain was treated with regular cervical paravertebral ozone injections. After his last injection, he experienced a syncopal episode and, upon awakening, was found to have ataxia, aphasia, hemiparesis, and left sixth nerve palsy. Computed tomographic angiography demonstrated intra-arterial gas in the right vertebral artery; multiple posterior circulation infarcts were seen on brain MRI. This case illustrates the potential dangers of paravertebral injections of ozone.

Journal of Neuro-Ophthalmology 2019;39:518–519

doi: 10.1097/WNO.0000000000000754

© 2019 by North American Neuro-Ophthalmology Society

Department of Ophthalmology and Vision Sciences (PRF, EAM), University of Toronto, Toronto, Canada; and; and Department of Medical Imaging (LA), University of Toronto, Toronto, Canada.

The authors report no conflicts of interest.

Address correspondence to Paul R. Freund, MD, 801 Eglinton Avenue W, Suite 301, Toronto, Ontario M5N 1E3, Canada; E-mail: pfreund@ualberta.ca

A 34-year-old man with cervical radiculopathy had been receiving intramuscular ozone injections into his right arm and cervical paravertebral spaces for chronic pain. He was previously treated with C6–C7 anterior cervical decompression and fusion but continued to suffer from pain. As a result, he sought alternative therapies and had undergone 13 treatments with ozone injections, during which he received approximately 15 injections of ozone per visit. At his most recent visit, he lost consciousness immediately after the last paravertebral injection of ozone and, on regaining consciousness, had dysarthria, aphasia, right-sided weakness, and horizontal diplopia. Urgent computed tomography and computed tomographic angiography of the brain and neck demonstrated intra-arterial air within the right vertebral artery and multiple foci of gas throughout the fascial planes in the posterior neck (Fig. 1). Brain MRI demonstrated multiple punctate foci of restricted diffusion involving numerous structures supplied by the posterior circulation (Fig. 2).

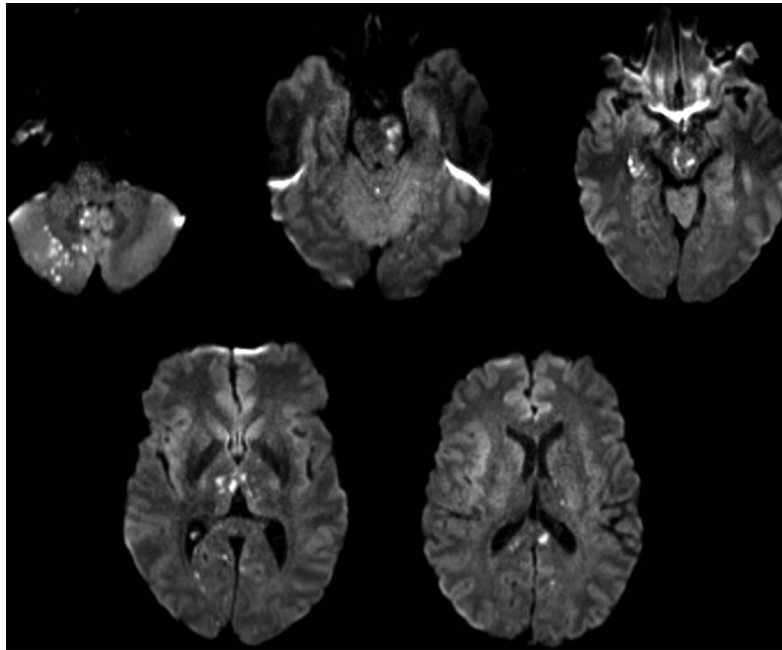


FIG. 2. Diffusion-weighted imaging reveals multiple punctate foci of restricted diffusion involving both cerebellar hemispheres greater on the right, the cerebellar vermis, the left pons, the midbrain, thalami, and occipital lobes.

Neurological examination demonstrated right hemiparesis, right-sided sensory impairment, left-sided ataxia, dysarthria, dysphagia, left sixth nerve palsy with mild left seventh nerve palsy, and cognitive impairment. He was treated with hyperbaric oxygen therapy and physical therapy. Six months later, there was significant clinical improvement for all neurologic deficits.

Prolotherapy is an alternative treatment modality consisting of injections of nonpharmacologic agents, such as ozone gas, for the treatment of chronic pain. Oxygen-ozone gas injections are proposed to generate anti-inflammatory effects, activate neutrophils and cytokine production to enhance the innate immune system, and increase perfusion by activating endothelial nitric oxide pathways causing vasodilation (1).

Ozone autohemotransfusion and intradiscal injections have been implicated in case reports of preretinal hemorrhages, vertebrobasilar strokes, and acute death (2–7). Arterial gas emboli can cause significant morbidity and mortality with intra-arterial gas volumes as little as 2 mL (8). Neuro-ophthalmologists should be aware of this treatment modality for chronic pain since it can cause significant morbidity and present with neuro-ophthalmic manifestations.

REFERENCES

1. **Bocci VA.** Scientific and medical aspects of ozone therapy. State of the art. *Riv Ital di Ossigeno-Ozonoterapia*. 2006;5:93–104.
2. **Marchetti D,** La Monaca G. An unexpected death during oxygen-ozone therapy. *Am J Forensic Med Pathol*. 2000;21:144–147.
3. **Giudice GL,** Valdi F, Gismondi M, Prosdocimo G, De Belvis V. Acute bilateral vitreo-retinal hemorrhages following oxygen-ozone therapy for lumbar disk herniation. *Am J Ophthalmol*. 2004;138:175–177.
4. **Corea F,** Amici S, Murgia N, Tambasco N. A case of vertebrobasilar stroke during oxygen-ozone therapy. *J Stroke Cerebrovasc Dis*. 2004;13:259–261.
5. **Rolán DV,** Lopez MM, Cuberas-Borrós G, Cuñat JL, Hervás JV, Vilamajó AM, Escudero D. Neurological symptoms following exposure to ozone. *J Neurol*. 2012;259:2740–2742.
6. **Avci S,** Büyükcamlı F, Demir ÖF, Özkan S. Anton syndrome during oxygen-ozone therapy. *Am J Emerg Med*. 2015;33:856.e1–856.e2.
7. **Vaiano A,** Valente C, De Benedetti G, Caramello G. Transient cortical blindness after intradiscal oxygen-ozone therapy. *Indian J Ophthalmol*. 2016;64:944.
8. **Judge C,** Mello S, Bradley D, Harbison J. A systematic review of the causes and management of ischaemic stroke caused by nontissue emboli. *Stroke Res Treat*. 2017;2017:7565702.