

# Recovery of an injured corticospinal tract via an unusual pathway in a stroke patient

## Case report

Sung Ho Jang, MD<sup>a</sup>, Chul Hoon Chang, MD<sup>b</sup>, Young Jin Jung, MD<sup>b</sup>, You Sung Seo, PhD<sup>a,\*</sup>

### Abstract

**Rationale:** A few mechanisms of recovery from an injured corticospinal tract (CST) in stroke patients have been reported: recovery of an injured CST through (1) normal CST pathway, (2) peri-lesional reorganization, and (3) shifting of the cortical origin area of an injured CST from the other areas to the primary motor cortex. However, it has not been clearly elucidated so far.

**Patient concerns:** A 57-year-old male patient presented with complete weakness of the right extremities due to an intracerebral hemorrhage (ICH) in the left basal ganglia. At three weeks after onset, the patient showed severe weakness of his right upper and lower extremities (Motricity Index [MI]: 28/100, finger extensor: 0/5). At 6 months after onset, his weakness showed some recovery, however, right finger extensor did not show any recovery (MI: 51/100, finger extensor: 0/5). At 9 months after onset, weakness showed significant recovery, particularly right finger extensor (MI: 64/100, right finger extensor: 3/5) and similar motor function persisted until 11 months after onset (MI: 67/100, right finger extensor: 3/5).

**Diagnoses:** The patient was diagnosed as the right hemiplegia due to ICH in the left corona radiata and basal ganglia.

**Interventions:** Clinical assessment, transcranial magnetic stimulation (TMS), and diffusion tensor tractography (DTT) were performed at 1, 6, 9, and 11 months after onset.

**Outcomes:** Discontinuation of the left CST at the midbrain level was observed on 1-month DTT and the corona radiata on 6-month DTT. However, on 9-month DTT, we observed a CST branch originating from the left posterior parietal cortex and then connecting to the main trunk to the CST at the thalamic level and thickened on 11-month DTT. On 1-month TMS, no MEP was evoked from the left hemisphere; on 6-month TMS study, MEPs were obtained at a right hand muscle (latency: 22.8 ms, amplitude: 130  $\mu$ V) and its amplitude was increased as 300  $\mu$ V with similar latencies on 9- and 11-month TMS studies.

**Lessons:** Recovery of an injured CST via an unusual pathway was demonstrated in a hemiparetic patient with ICH, using DTT and TMS. We believe that our results suggest that precise evaluation for an injured CST using TMS and DTT might be necessary, particularly in young patients, even after 6 months from onset even though the stroke patients show clinical characteristics of severe injury of the affected CST.

**Abbreviations:** CST = corticospinal tract, DTT = diffusion tensor tractography, ET = excitatory threshold, ICH = intracerebral hemorrhage, MEP = motor-evoked potential, MI = Motricity Index, TMS = transcranial magnetic stimulation.

**Keywords:** corticospinal tract, diffusion tensor tractography, stroke, transcranial magnetic stimulation

Editor: N/A.

Financial disclosure statements have been obtained, and no conflicts of interest have been reported by the authors or by any individuals in control of the content of this article.

This work was supported by the Medical Research Center Program (2015R1A5A2009124) through the National Research Foundation of Korea (NRF) funded by the Ministry of Science, ICT and Future Planning.

<sup>a</sup> Department of Physical Medicine and Rehabilitation, <sup>b</sup> Department of Neurosurgery, College of Medicine, Yeungnam University, Republic of Korea.

\* Correspondence: You Sung Seo, Department of Physical Medicine and Rehabilitation, College of Medicine, Yeungnam University 317-1, Daemyungdong, Namku, Taegu, 705-717, Republic of Korea (e-mail: yousung1008@daum.net).

Copyright © 2019 the Author(s). Published by Wolters Kluwer Health, Inc. This is an open access article distributed under the terms of the Creative Commons Attribution-Non Commercial-No Derivatives License 4.0 (CCBY-NC-ND), where it is permissible to download and share the work provided it is properly cited. The work cannot be changed in any way or used commercially without permission from the journal.

Medicine (2019) 98:7(e14307)

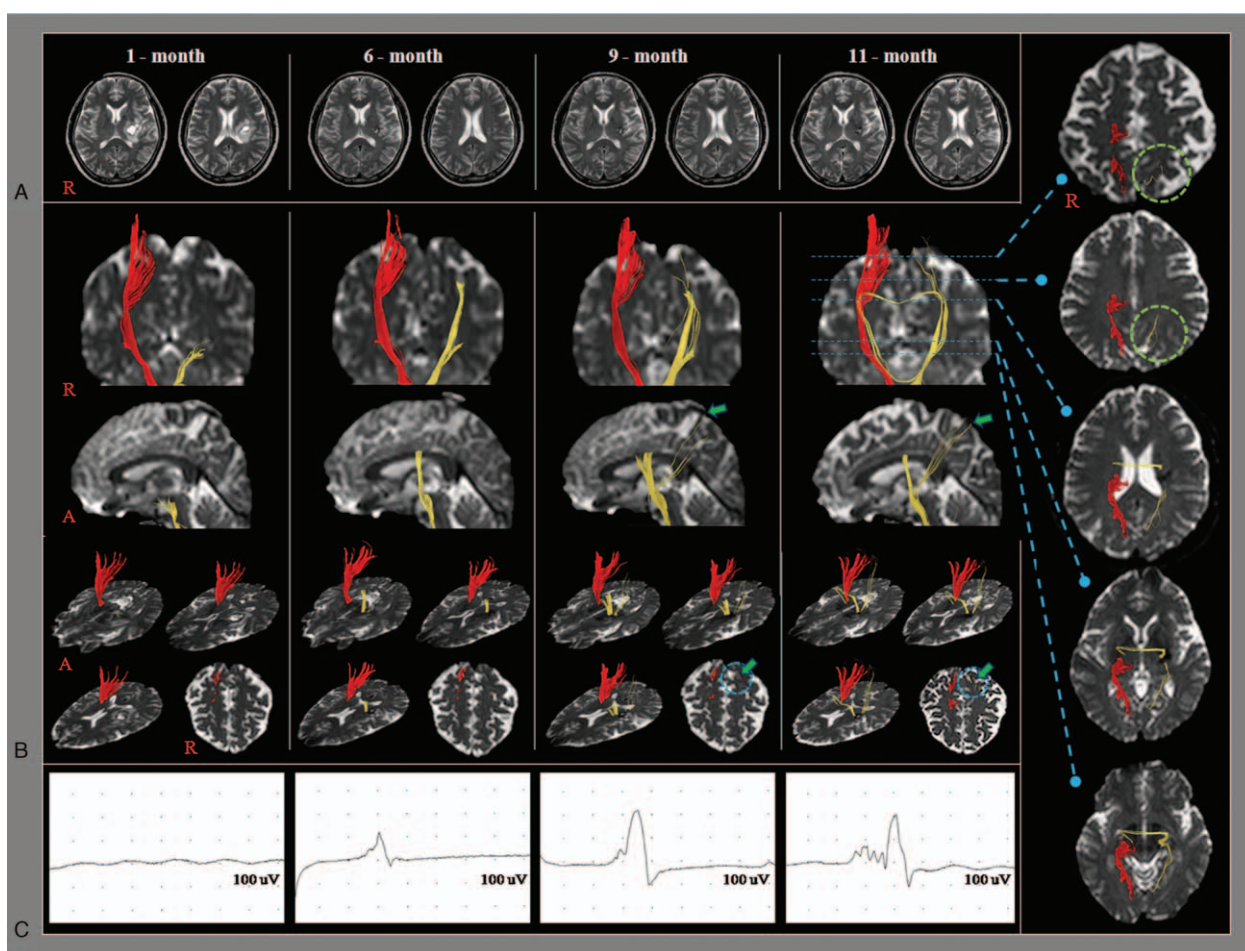
Received: 23 July 2018 / Received in final form: 3 January 2019 / Accepted: 9 January 2019

<http://dx.doi.org/10.1097/MD.0000000000014307>

## 1. Introduction

The corticospinal tract (CST) is the major neural tract for motor function in the human brain.<sup>[1,2]</sup> The CST is essential for good motor recovery in stroke patients, therefore clarification of the recovery mechanism of an injured CST in stroke patients is clinically important.<sup>[1-3]</sup> A few mechanisms of recovery from an injured CST in stroke patients have been reported: recovery of an injured CST through (1) normal CST pathway, (2) peri-lesional reorganization, and (3) shifting of the cortical origin area of an injured CST from the other areas to the primary motor cortex.<sup>[4-7]</sup> However, it has not been clearly elucidated so far.

Diffusion tensor tractography (DTT) and transcranial magnetic stimulation (TMS) have commonly been used for evaluation of the state of an injured CST.<sup>[8,9]</sup> DTT provides a three-dimensional evaluation of the integrity and pathway of the injured CST.<sup>[9]</sup> However, DTT can produce false negative results throughout the white matter due to crossing fibers.<sup>[10]</sup> By contrast, TMS can distinguish between the CST and non-CST, and estimated amount of the CST by analyzing the characteristics of the motor-evoked potential (MEP).<sup>[8]</sup> However, TMS also has



**Figure 1.** (A) T2-weighted images showing leukomalactic lesions in the left corona radiata and basal ganglia. (B) Results of diffusion tensor tractography (DTT). Discontinuation of the left CST at the midbrain level is observed on 1-month DTT and the corona radiata on 6-month DTT. However, on 9-month DTT, a CST branch originating from the left posterior parietal cortex (circle) and then connecting to the main trunk to the CST at the thalamic level is observed and this branch is thickened on 11-month DTT. (C) Results of transcranial magnetic stimulation (TMS). On 1-month TMS, no motor evoked potential (MEP) is evoked from the left hemisphere. On 6-month TMS study, MEP is obtained from the right abductor pollicis brevis muscle during stimulation of the left hemisphere with 100% of maximal output (the shortest latency; latency: 22.8 ms, amplitude: 130  $\mu$ V) and its amplitude is increased as 300  $\mu$ V with similar latencies (23.4 ms, 23.2 ms) on 9- and 11-month TMS studies.

limitations including poor spatial resolution and the possibility of a false negative result due to excessive high threshold following stroke.<sup>[8]</sup> As a result, combined use of DTT and TMS can enable more precise evaluation of an injured CST.

In this study, we report on a patient with intracerebral hemorrhage (ICH) who showed recovery of the injured CST via an unusual CST pathway, which was demonstrated using DTT and TMS.

**2. Case report**

A 57-year-old, right-handed male patient presented with complete weakness of the right upper and lower extremities due to an ICH in the left corona radiata and basal ganglia (Fig. 1A). At three weeks after onset, he was transferred to the rehabilitation department for rehabilitation after conservative management for the ICH at the department of neurosurgery of a university hospital. The patient showed severe weakness of his right upper and lower extremities (Motricity Index [MI]: 28/100, and the finger extensor: 0/5)<sup>[11,12]</sup> (Table 1). He participated in a comprehensive rehabilitative management program, including movement therapy, neurotrophic drugs (pramipexole: 1 mg,

amantadine: 300 mg, ropinirole: 2 mg, and levodopa: 750 mg), and neuromuscular electrical stimulation therapy of the right finger extensors and ankle dorsiflexors.<sup>[13,14]</sup> He was transferred to a local rehabilitation hospital after 1 month’s rehabilitation and continued comprehensive rehabilitative therapy until 6

**Table 1**  
Changes of motor function in the patient.

	Duration from onset	Onset	1 month	6 months	9 months	11 months
MRC	Shoulder abductor	0	2 <sup>-</sup>	2 <sup>+</sup>	3 <sup>-</sup>	3
	Elbow flexor	0	2 <sup>-</sup>	3	3 <sup>+</sup>	3 <sup>+</sup>
	Finger flexor	0	0	0	3	3
	Finger extensor	0	0	0	3	3
	Hip flexor	0	3	4 <sup>-</sup>	4	4
	Knee extensor	0	3	4	4 <sup>+</sup>	4 <sup>+</sup>
	Ankle dorsiflexor	0	0	4	4 <sup>+</sup>	4 <sup>+</sup>
	MI	Upper extremity	0	19	33	54
Lower extremity		0	37	68	74	74
Total		0	28	51	64	67

MI = Motricity Index, MRC = Medical Research Council.

months after onset. At 6 months after onset, his motor weakness showed some recovery, however, his right finger extensor did not show any recovery (MI: 51/100, and the finger extensor: 0/5). After 6-month evaluation for the CST using DTT and TMS, he was re-admitted to the rehabilitation department of the same university hospital. He underwent more intensive rehabilitation for facilitation of the injured left CST including repetitive transcranial magnetic stimulation therapy (rTMS [MAGPRO, Medtronic Functional Diagnostics, Skovlunde, Denmark]: pre-central knob, frequency of 10Hz, intensity of 80% motor threshold, and a total of 160 pulses for 8 min, and seven sessions per week),<sup>[15]</sup> increment of neurotrophic drugs (increased doses: pramipexole: 1 mg and ropinirole: 2 mg), and muscle wash for relieving spasticity of the right finger extensors because his right finger flexors showed severe spasticity as 2<sup>+</sup> on the Modified Ashworth Scale.<sup>[16]</sup> As a result, at 9 months after onset, his motor weakness showed significant recovery, particularly his right finger extensor (MI: 64/100, and the right finger extensor: 3/5) and similar motor function persisted until 11 months after onset (MI: 67/100, and the right finger extensor: 3/5). The patient provided signed, informed consent and our institutional review board approved the study protocol.

### 2.1. Diffusion tensor imaging and transcranial magnetic stimulation

DTI data were acquired four times (1 month, 6 months, 9 months, and 11 months after onset) using a sensitivity-encoding head coil on a 1.5-T Philips Gyroscan Intera (Hoffman-LaRoche Ltd, Best, The Netherlands) with single-shot echo-planar imaging and navigator echo. Imaging parameters were as follows: acquisition matrix=96×96; reconstructed to matrix=192×192 matrix; field of view=240×240 mm<sup>2</sup>; TR=10,398 ms; TE=72 ms; parallel imaging reduction factor=2; EPI factor=59; *b*=1000 s/mm<sup>2</sup>; and a slice thickness of 2.5 mm. Fiber tracking was performed using the fiber assignment continuous tracking (FACT) algorithm implemented within the DTI task card software (Philips Extended MR Work Space 2.6.3). Each DTI replication was intra-registered to the baseline “b0” images to correct for residual eddy-current image distortions and head motion effect, using a diffusion registration package (Philips Medical Systems). For reconstruction of the CST, the first region of interest (ROI) was placed on the upper pons (portion of anterior blue color) on the color map with an axial image. The second ROI was placed on the mid pons (portion of anterior blue color) on the color map with an axial image. The termination criteria used for fiber tracking were FA < 0.1, angle < 27°.<sup>[9]</sup>

Discontinuation of the left CST at the midbrain level was observed on 1-month DTT and the corona radiata on 6-month DTT. However, on 9-month DTT, we observed a CST branch originating from the left posterior parietal cortex and then connecting to the main trunk to the CST at the thalamic level and this branch was thickened on 11-month DTT (Fig. 1B).

TMS was also performed four times (1 month, 6 months, 9 months, and 11 months after onset) using a Magstim Novamatrix 200 magnetic stimulator with a 9-cm mean diameter circular coil (Novamatrix Inc., USA). Cortical stimulation was performed with the coil held tangentially over the vertex. The left hemisphere was stimulated by a counterclockwise current, and the right hemisphere was stimulated by a clockwise current. Motor-evoked potentials (MEPs) were obtained from both abductor pollicis brevis muscles in a relaxed state. The excitatory threshold (ET) was defined as the minimum stimulus required to elicit an

MEP with a peak-to-peak amplitude of 50 μV or greater in two out of four attempts. Stimulation intensity was set at the ET plus 20% of the maximum stimulator output.

On 1-month TMS, no MEP was evoked from the left hemisphere, even though stimulation intensity was increased to 100% of maximal output. By contrast, on 6-month TMS study, MEPs were obtained at the right abductor pollicis brevis muscle during stimulation of the left hemisphere with 100% of maximal output (the MEP of shortest latency; latency: 22.8 ms, amplitude: 130 μV) and its amplitude was increased as 300 μV with similar latencies (23.4 ms, 23.2 ms) on 9- and 11-month TMS studies (Fig. 1C).

### 3. Discussion

In this study, we followed up DTT and TMS for an injured CST in a patient with ICH who showed recovery of the injured CST via an unusual pathway. We believe that the injured left CST recovery was based on the evidences of motor recovery of the right finger extensor, and the characteristics of the MEP on the right hand muscle:

- (1) although the CST is involved in the motor control of all muscles of the extremities, previous studies have reported that the affected finger extensor is the most representative indicator of recovery of an injured CST,<sup>[1,2,17]</sup> and
- (2) the latency of a MEP can discriminate whether the MEP originated from the CST because the latency of the MEP indicates the fastest velocity of a neural tract.<sup>[8]</sup>

We believe that this patient had the following characteristics that differed from the motor recovery of usual hemiparetic stroke patients:

- (1) the injured left CST recovery was occurred via an unusual motor pathway originating from the posterior parietal cortex connected to the CST at the thalamic level. This appeared to be attributed to the variety of the cerebral origin of the CST originating from the fronto-parietal cortices, including the primary motor cortex, the secondary motor area, and the somatosensory cortex,<sup>[18]</sup>
- (2) most of the motor recovery in stroke patients occurs within 6 months after onset.<sup>[19,20]</sup> However, this patient showed significant motor recovery of the right finger extensor by the more active rehabilitation since 6 months after onset when we found the evidence of the minimally recovered left CST on the 6-month MEP even though the patient's motor function coincided with a severe injury of the affected CST,<sup>[1,2,17]</sup> and
- (3) more precise evaluation of the injured left CST by combined study using DTT and TMS; on 6-month evaluation, we observed the injured left CST on TMS even though DTT showed discontinuation of the injured left CST; in contrast, on 9- and 11-month DTT, we confirmed the three-dimensional configuration of a branch from the left posterior parietal cortex connected to the main trunk of the left CST at the thalamic level.

In conclusion, recovery of an injured CST via an unusual pathway (from the posterior parietal cortex) was demonstrated in a hemiparetic patient with ICH, using DTT and TMS. We believe that our results suggest the following take home message: precise evaluation for an injured CST using TMS and DTT might be necessary, particularly in young patients, even after 6 months from onset even though the stroke patients show clinical characteristics of severe injury of the affected CST.

## Author contributions

**Data curation:** Sung Ho Jang, Young Jin Jung.

**Investigation:** Chul Hoon Chang.

**Writing – original draft:** You Sung Seo.

## References

- [1] Cho HM, Choi BY, Chang CH, et al. The clinical characteristics of motor function in chronic hemiparetic stroke patients with complete corticospinal tract injury. *NeuroRehabilitation* 2012;31:207–13.
- [2] Jang SH, Kim K, Kim SH, et al. The relation between motor function of stroke patients and diffusion tensor imaging findings for the corticospinal tract. *Neurosci Lett* 2014;572:1–6.
- [3] Jang SH. The corticospinal tract from the viewpoint of brain rehabilitation. *J Rehabil Med* 2014;46:193–9.
- [4] Jang SH, Byun WM, Han BS, et al. Recovery of a partially damaged corticospinal tract in a patient with intracerebral hemorrhage: a diffusion tensor image study. *Restor Neurol Neurosci* 2006;24:25–9.
- [5] Kwon HG, Jang SH. Significance of rehabilitative management during the critical period for motor recovery in intracerebral hemorrhage: a case report. *J Rehabil Med* 2012;44:280–4.
- [6] Yeo SS, Jang SH. A change in injured corticospinal tract originating from the premotor cortex to the primary motor cortex in a patient with intracerebral hemorrhage. *Neural Regen Res* 2012;7:939–42.
- [7] Rong D, Zhang M, Ma Q, et al. Corticospinal tract change during motor recovery in patients with medulla infarct: a diffusion tensor imaging study. *Biomed Res Int* 2014;2014:524096doi: 10.1155/2014/524096. Epub 2014 May 25.
- [8] Rossini PM, Burke D, Chen R, et al. Non-invasive electrical and magnetic stimulation of the brain, spinal cord, roots and peripheral nerves: basic principles and procedures for routine clinical and research application. An updated report from an I.F.C.N. committee. *Clin Neurophysiol* 2015;126:1071–107.
- [9] Kunimatsu A, Aoki S, Masutani Y, et al. Three-dimensional white matter tractography by diffusion tensor imaging in ischaemic stroke involving the corticospinal tract. *Neuroradiology* 2003;45:532–5.
- [10] Yamada K, Sakai K, Akazawa K, et al. MR tractography: a review of its clinical applications. *Magn Reson Med Sci* 2009;8:165–74.
- [11] Tiffin J, Asher EJ. The purdue pegboard; norms and studies of reliability and validity. *J Appl Psychol* 1948;32:234–47.
- [12] Massy-Westropp NM, Gill TK, Taylor AW, et al. Hand grip strength: age and gender stratified normative data in a population-based study. *BMC Res Notes* 2011;4:127.
- [13] Demeurisse G, Demol O, Robaye E. Motor evaluation in vascular hemiplegia. *Eur Neurol* 1980;19:382–9.
- [14] Scheidtmann K, Fries W, Müller F, et al. Effect of levodopa in combination with physiotherapy on functional motor recovery after stroke: a prospective, randomised, double-blind study. *Lancet* 2001; 358:787–90.
- [15] Kim YH, You SH, Ko MH, et al. Repetitive transcranial magnetic stimulation-induced corticomotor excitability and associated motor skill acquisition in chronic stroke. *Stroke* 2006;37:1471–6.
- [16] Carpenter EB, Seitz DG. Intramuscular alcohol as an aid in management of spastic cerebral palsy. *Dev Med Child Neurol* 1980; 22:497–501.
- [17] Nijland RH, van Wegen EE, Harmeling-van der Wel BC, et al. Presence of finger extension and shoulder abduction within 72 hours after stroke predicts functional recovery: early prediction of functional outcome after stroke: the epos cohort study. *Stroke* 2010;41:745–50.
- [18] Seo JP, Jang SH. Different characteristics of the corticospinal tract according to the cerebral origin: DTI study. *AJNR Am J Neuroradiol* 2013;34:1359–63.
- [19] Kelly-Hayes M, Wolf PA, Kase CS, et al. Time course of functional recovery after stroke: The Framingham study. *Neurorehabil Neural Repair* 1989;3:65–70.
- [20] Jørgensen HS, Nakayama H, Raaschou HO, et al. Outcome and time course of recovery in stroke. Part II: Time course of recovery. The Copenhagen Stroke Study. *Arch Phys Med Rehabil* 1995;76:406–12.