

## Spontaneous Angiographic Disappearance of an Intracranial Arteriovenous Malformation

Paul A. Gibb, Richard W. Gullan & Nindi Sandhu

To cite this article: Paul A. Gibb, Richard W. Gullan & Nindi Sandhu (1988) Spontaneous Angiographic Disappearance of an Intracranial Arteriovenous Malformation, British Journal of Neurosurgery, 2:4, 529-533, DOI: [10.3109/02688698809029610](https://doi.org/10.3109/02688698809029610)

To link to this article: <http://dx.doi.org/10.3109/02688698809029610>



Published online: 06 Jul 2009.



Submit your article to this journal [↗](#)



Article views: 2



View related articles [↗](#)

**SHORT REPORT**

**Spontaneous Angiographic Disappearance of an Intracranial Arteriovenous Malformation**

PAUL A. GIBB, RICHARD W. GULLAN & NINDI SANDHU

*South East Thames Regional Neurosurgical Unit, Brook General Hospital, Shooters Hill Road, Woolwich, SE18 4LW, United Kingdom*

**Abstract**

A deep right hemisphere AVM was demonstrated by angiography in an 8-year-old girl soon after her presentation with a subarachnoid haemorrhage. Eight years later the AVM was no longer visible on angiography. During the interval she had been completely asymptomatic and had received no treatment. There was no residual neurological deficit or epilepsy. A similar case has previously been described and is discussed briefly along with other cases of complete AVM regression.

**Key words:** *Arteriovenous malformation.*

**Case Report**

In 1979 a previously healthy 8-year-old girl was referred to this unit after waking from sleep screaming and complaining of severe headache, nausea and vomiting. On examination she was irritable and restless but would obey simple commands. She had marked meningism and bilateral extensor plantar responses. There were no other neurological signs. A lumbar puncture performed at the referring hospital revealed uniformly blood-stained CSF, and a CT scan in our unit showed extensive subarachnoid blood with no evidence of an intracerebral haematoma.

Bilateral carotid angiography 18 h after the haemorrhage demonstrated a deep right hemisphere ganglionic AVM, supplied mainly by enlarged lenticulostriate arteries, with a small component from the distal anterior cerebral arteries. The malformation drained into the right basal vein, the superior sagittal sinus and the vein of Galen. (Fig. 1a,b,c).

She made a slow recovery complicated by transient mild hydrocephalus and was discharged 1 month after admission with no residual neurological deficit.

In 1987, with the advent of greater availability of stereotactic radiosurgery in the United Kingdom, she was readmitted for repeat angiography to reassess the malformation. She was now 15 years old and had been completely well since her previous admission with no headaches, convulsions or neurological deficit. She smoked 10 cigarettes a day and was not taking the oral contraceptive pill. Routine haematological investigations were normal. To our surprise repeat angiography failed to demonstrate the AVM. (Fig. 2a,b,c).

**Discussion**

Regression of arteriovenous malformations is an extremely rare phenomenon. We have identified 27 cases of AVM regression which

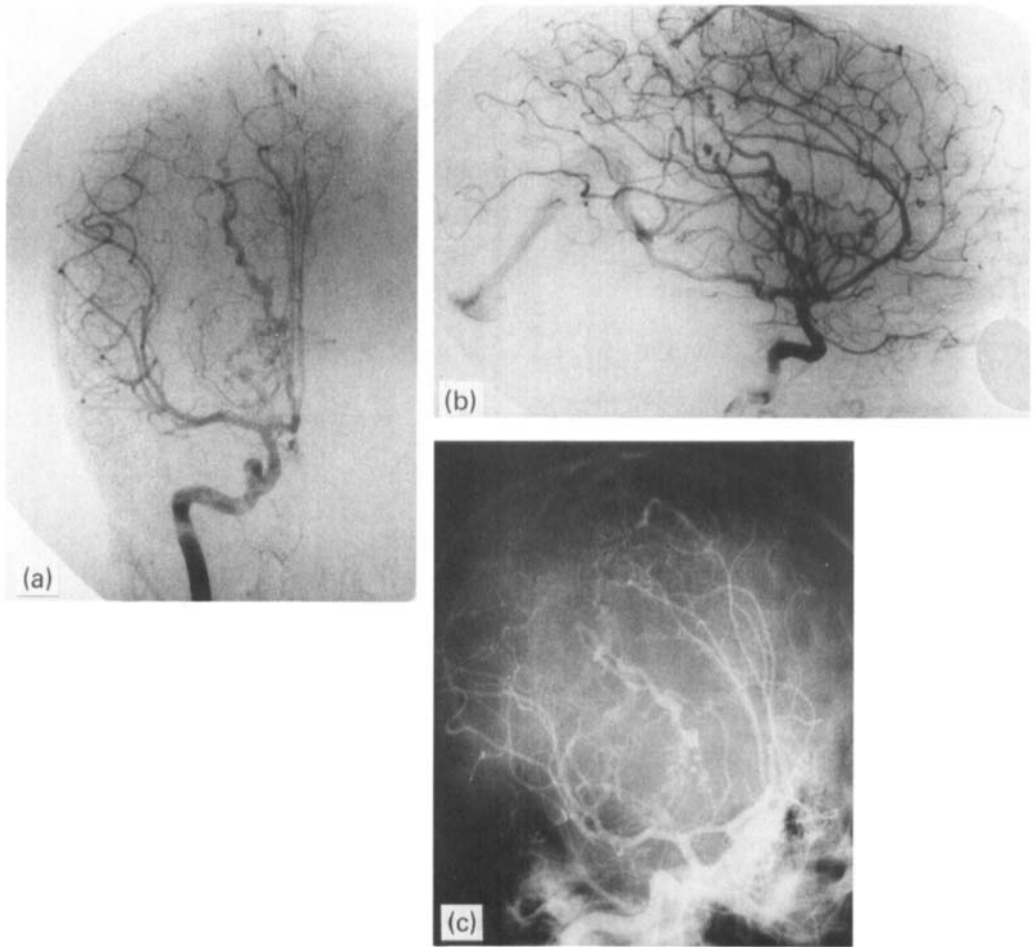


FIG. 1.a,b,c. AP, lateral and oblique projections of right internal carotid angiogram (1979), demonstrating a deep ganglionic AVM, supplied mainly by enlarged lenticulostriate arteries. There is a small component from the distal anterior cerebral arteries. The malformation shunts early through hypertrophied and tortuous vessels into the large right basal vein, superior saggital sinus and vein of Galen.

are reviewed in this article. In five cases incomplete resolution occurred<sup>1-5</sup>, and in four other cases there was incomplete angiographic documentation (i.e. thrombosed AVM discovered at operation)<sup>6-9</sup>. Table I summarises the remaining 18 cases in which complete regression of an AVM has been demonstrated angiographically.

The patients were grouped according to events occurring between the positive and negative angiograms that could possibly be related to disappearance of the AVM. Six patients had undergone surgery at presentation including partial excision of the AVM<sup>10,11</sup>, clot

aspiration<sup>12</sup>, shunting<sup>13,14</sup>, and aspiration of an associated arachnoid cyst<sup>15</sup>. In two patients there was clinical and radiographic evidence of rebleeding prior to re-angiography<sup>16</sup>.

Five patients developed new or increasing neurological deficit or epilepsy prompting investigation<sup>2,8,10,17</sup>. Two patients underwent re-angiography after episodes of severe headache (associated with unconsciousness in one) without clinical or radiographic evidence of rebleeding<sup>18,19</sup>. In the remaining three cases re-angiography was not precipitated by any acute event, and there had been no deterioration in the clinical condition of the patients between

TABLE I. Case reports of complete AVM disappearance, grouped as described in the text according to events occurring between presentation and reangiography

Age	Sex	Presentation Group <sup>a</sup>	AVM Site	Depth <sup>b</sup>	Treatment	Age	Representation Group	Resolution <sup>b</sup>	Reference
<b>Group 1: Surgical Intervention</b>									
42	M	Haemorrhage	R Parietal	Superficial	Partial excision	47	Deficit	Complete Discovered thrombosed Complete	10
33	F	Haemorrhage	L Frontal	Deep	Partial excision	42	Other	Complete	11
40	M	Deficit	L Parietal	Deep	Aspiration of clot	47	Deficit	Complete	12
33	M	Other	L Frontal	Deep	Shunt	54	Deficit	Complete	13
4/12	F	Other	L P Fossa	Deep	VP Shunt + Evacuation of Subdural	1	Deficit Epilepsy	Complete	14
2/12	F	Deficit	R Parietal + Arachnoid cyst	Deep	Evacuation of cyst	3	Other	Complete CT subdural	15
<b>Group 2: Second Haemorrhage</b>									
56	M	Deficit	L Parietal	?	—	65	Haemorrhage	Complete	16
40	F	Epilepsy	R Parietal	Superficial	—	55	Haemorrhage Epilepsy	Complete CT low density	16
<b>Group 3: New or increasing Neurological Deficit or Epilepsy</b>									
34	F	Deficit	R Parietal	Deep	—	38	Deficit	Complete	8
54	F	Deficit	L Temporal	Deep	—	59	Deficit	Complete	10
15	F	Deficit	L Temporal	Deep	—	18	Deficit	Complete CT Astrocytoma	2
35	F	Haemorrhage	R Parietal	Deep	—	40	Epilepsy	Complete CT low density	2
54	F	Haemorrhage	L Parietal (previous partial excision)	Superficial	—	62	Epilepsy	Complete	17
<b>Group 4: Severe Headache</b>									
34	F	Haemorrhage (recurrent)	L Parietal	Superficial	—	37	Other	Complete	18
46	M	Other	R Parietal + R MCA	Superficial Aneurysm	—	59	Other	Complete CT Aneurysm	19
<b>Group 5: No change—Persistent Neurological Deficit or Epilepsy</b>									
41	M	Epilepsy	L Parietal + L MCA	Superficial Aneurysm	—	48	Epilepsy	Complete CT enhancing lesion	16
11	F	Haemorrhage	L Parietal	Deep	—	22	Deficit	Complete CT low density	20
<b>Group 6: No change—Asymptomatic Patient</b>									
15	M	Haemorrhage	R Parietal	Superficial	—	16	Asymptomatic	Complete CT normal	16

<sup>a</sup>Symptom complex group at presentation/representation after Crawford<sup>21</sup>:

1 Haemorrhage ± epilepsy ± neurological deficit

2 Epilepsy ± neurological deficit

<sup>b</sup>Angiographic appearance.

3 Neurological deficit

4 Other

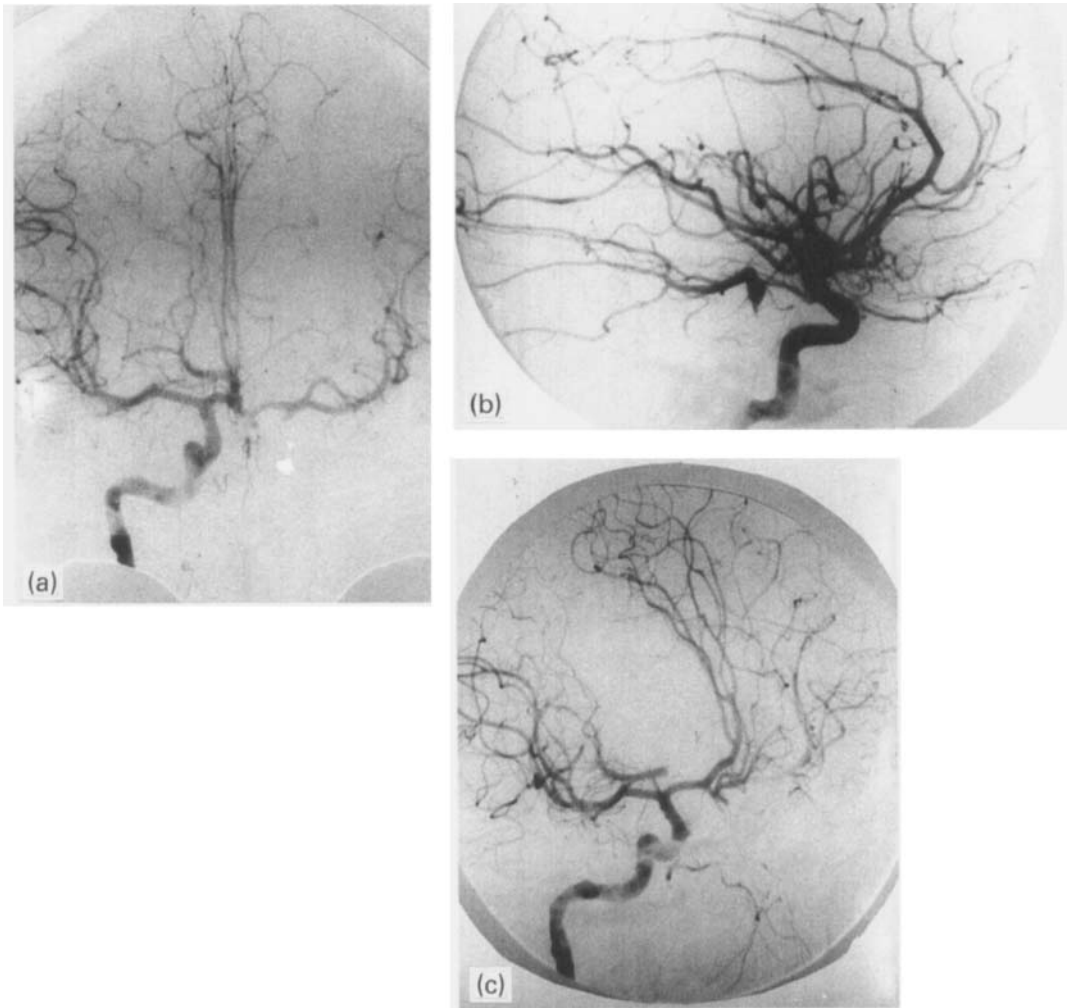


FIG. 2.a,b,c. AP, lateral and oblique projections of the right internal carotid angiogram (1987), demonstrating normal intracranial circulation. The previously demonstrated AVM was not opacified on the early or late phases of the study.

angiograms. Two of these patients had suffered from persistent epilepsy and hemiparesis following presentation and angiography was performed prior to attempting surgical treatment<sup>16,20</sup>. The remaining patient<sup>16</sup>, like our own, was unique in making a complete recovery from spontaneous haemorrhage, suffering neither neurological deficit nor epilepsy. In both cases re-angiography was performed electively prior to treatment in an apparently normal patient.

Pasqualin<sup>16</sup> described the case of a 15-year-old boy presenting with sudden unconsciousness and convulsions in whom a CT scan

revealed a small right parietal haematoma, and angiography demonstrated a small parietal AVM fed by the callosomarginal artery. One year later a preoperative angiogram was normal, as was contrast enhanced CT.

We did not feel that repeat scanning was indicated in our patient particularly in view of her age and parental anxiety over radiation exposure. However it is of interest that of eight patients in whom CT scans have been performed following spontaneous angiographic disappearance of their AVM, only one was normal, and this was in an asymptomatic patient without epilepsy or deficit<sup>16</sup>. A variety

of abnormalities were found, the most common being an area of low attenuation related to the site of the AVM. In one case an Astrocytoma was discovered<sup>2</sup>.

The case presented suggests that AVM's are truly capable of spontaneous resolution, and various mechanisms explaining the phenomenon of AVM regression have been proposed. In those in whom a surgical procedure has been undertaken it is possible that alterations in local haemodynamics contributed to the AVM thrombosis and subsequent regression<sup>19</sup>. Compression by intracerebral clot and associated oedema<sup>8</sup>, distortion after recurrent episodes of bleeding<sup>11</sup>, acute<sup>4</sup> and gradual thrombosis<sup>5,7</sup> and embolisation<sup>1</sup> have also been proposed as mechanisms for spontaneous regression. In Pasqualin's case<sup>16</sup> and our own thrombosis probably occurred gradually, precipitated initially by local mass effect and spasm and latterly by haemodynamic disturbances associated with gliosis. It is possible that the transient hydrocephalus occurring in our patient was a contributory factor. In both cases spontaneous regression occurred in a healthy patient with no deleterious effects.

### Acknowledgements

We would like to thank Mr J. R. Bartlett for permission to report this case, and Mr N. Norman for his assistance with the literature search.

*Address for correspondence:* Mr R. W. Gullan, South East Thames Regional Neurosurgical Unit, Brook General Hospital, Shooters Hill Road, Woolwich, SE18 4LW, U.K.

### References

- 1 Kushner J, Alexander E. Partial spontaneous regressive arteriovenous malformation. *J. Neurosurg* 1970; 32:360-6.
- 2 Omojola MF, Fox AJ, Vinuela FV, Drake CG.

- Spontaneous regression of intracranial arteriovenous malformations. *J Neurosurg* 1982; 57: 818-22.
- 3 Sasaki U, Itagaki T, Shimizu H, Takahashi M. Almost complete regression of cerebral arteriovenous malformation. *Neurol Surg (Tokyo)* 1976; 4:175-81.
- 4 Sukoff M, Barth B, Moran T. Spontaneous occlusion of a massive arteriovenous malformation. *Neuroradiology* 1972; 4:121-3.
- 5 Svien HJ, Perserico L. Regression in size of arteriovenous anomaly. *J Neurosurg* 1960; 17:493-6.
- 6 Castaigne P, Buge A, Pertuiset B, Laplane D, Corbin J. Angiome thrombose, radiologiquement exclu. *Bull Mem Soc Med Hop Paris* 1961; 77:923-30.
- 7 Dyck P. Spontaneous thrombosis of an arteriovenous malformation. *Neurosurgery* 1977; 1,3:287-90.
- 8 Eisenman JI, Alekoubides A, Pribram H. Spontaneous thrombosis of vascular malformations of the brain. *Acta Radiol* 1972; 13:77-85.
- 9 Norlen G. Arteriovenous aneurysms of the brain: Report of ten cases of total removal of the lesion. *J Neurosurg* 1949; 6:475-94.
- 10 Fischer G, Brunon J, Thierry A, Aimard G, Rochet M, Mansuy L. Thrombose au cours de l'evolution des aneurysms arterio-veineux cerebraux. *J Med Lyon* 1969; 50:613-25.
- 11 Lakke JPWF. Regression of an arteriovenous malformation of the brain. *J Neurol Sci* 1970; 11:489-96.
- 12 Levine J, Misko JC, Seres JL, Glenn Snodgrass R. Spontaneous angiographic disappearance of a cerebral arteriovenous malformation. *Arch Neurol* 1973; 28:195-6.
- 13 Hook O, Johanson C. Intracranial arteriovenous aneurysms. *Arch Neurol Psychiat* 1958; 80:39-54.
- 14 Mabe H, Furuse M. Spontaneous disappearance of a cerebral arteriovenous malformation in infancy. *J Neurosurg* 1977; 46:811-5.
- 15 Pascual-Castroviejo I, Pascual-Pascual J, Blazquez MG, Lopez-Martin V. Spontaneous occlusion of an intracranial arteriovenous malformation. *Child's Brain* 1977; 3:169-79.
- 16 Pasqualin A, Vivenza C, Rosta R, Scienza R, Da Pian R, Colangeli M. Spontaneous disappearance of intracranial arteriovenous malformations. *Acta Neurochir* 1985; 76:50-7.
- 17 Pecker J, Sabouraud O, Javalet A. Les thromboses spontanees des aneurysmes arterio-veineux cerebraux. *Neurochirurgie* 1961; 7:155-7.
- 18 Conforti P. Spontaneous disappearance of cerebral arteriovenous angioma. *J Neurosurg* 1971; 34:432-4.
- 19 Nehls DG, Pittman HW. Spontaneous regression of arteriovenous malformations. *Neurosurgery* 1982; 11,6:776-80.
- 20 Sartor K. Spontaneous closure of cerebral arteriovenous malformation demonstrated by angiography and computed tomography. *Neuroradiology* 1978; 15:95-8.
- 21 Crawford PM, West CR, Chadwick DW, Shaw MDM. Arteriovenous malformations of the brain: natural history in unoperated patients. *J Neurol Neurosurg Psych* 1986; 49:1-10.