



## Clinical letter

CADASIL presenting with focal and generalised epilepsy due to a novel *NOTCH3* mutationBenson S. Chen<sup>a,\*</sup>, James Cleland<sup>a</sup>, Richard I. King<sup>b</sup>, Neil E. Anderson<sup>a</sup><sup>a</sup> Department of Neurology, Auckland City Hospital, Private Bag 92024, Auckland 1142, New Zealand<sup>b</sup> Canterbury Health Laboratories, P O Box 151, Christchurch 8140, New Zealand

## ARTICLE INFO

## Keywords:

CADASIL

Epilepsy

Stroke

Genetic testing

*NOTCH3*

## 1. Introduction

Cerebral autosomal dominant arteriopathy with subcortical infarcts and leukoencephalopathy (CADASIL) is an autosomal dominant small vessel disease caused by mutations of the *NOTCH3* gene [1]. Clinical manifestations of CADASIL include headaches, recurrent ischaemic strokes, and progressive cognitive decline. Seizures are an uncommon symptom and were previously reported as occurring late in the disease course, after onset of stroke [1]. We report a CADASIL family with epilepsy as an early symptom due to a novel *NOTCH3* mutation.

## 1.1. Patient descriptions

## 1.1.1. Patient 1

The proband is a 61 year-old woman of European ancestry residing in New Zealand with a longstanding history of migraine headaches. In June 2009 she presented with convulsive status epilepticus, which terminated with midazolam. This was followed by one minute of focal myoclonic seizures involving her right side with impaired awareness. She commenced phenytoin but continued to have infrequent focal and generalised seizures. Her husband reported a one-year history of memory impairment and functional decline preceding the seizures.

An interictal EEG performed in 2009, while the patient was on phenytoin, was normal. MRI showed changes suggestive of a leukodystrophy (Fig. 1A). Serum lactate, CSF examination, and mitochondrial DNA analysis for mutations associated with myoclonic epilepsy with ragged red fibres syndrome (MERRF) and mitochondrial encephalomyopathy, lactic acidosis, and stroke-like episodes (MELAS)

were negative. Lysosomal enzyme activities were normal. Muscle biopsy showed a single cytochrome oxidase-negative muscle fibre of indeterminate significance.

In 2012 levetiracetam was commenced after she presented in status epilepticus. Her cognition continued to deteriorate and she moved into residential care.

## 1.1.2. Patient 2

The proband's daughter was diagnosed with epilepsy at age 12 years. She experienced generalised tonic-clonic seizures twice a year and was treated with sodium valproate. There was no history of myoclonic or absence seizures.

In 2009, at age 31 years, she presented with increasingly frequent seizures and began to experience daily brief 'blank spells'. These had features of typical absence seizures and were not associated with focal neurological symptoms. Lamotrigine was added. An EEG recorded while the patient was being treated with sodium valproate and lamotrigine was normal.

In 2014 she sustained serious dental injuries during a tonic-clonic seizure. In 2017 she presented with a flurry of seizures. Prior to the seizures she experienced dizziness and was witnessed to stare blankly for a few minutes. The seizures then evolved into bilateral tonic-clonic convulsions.

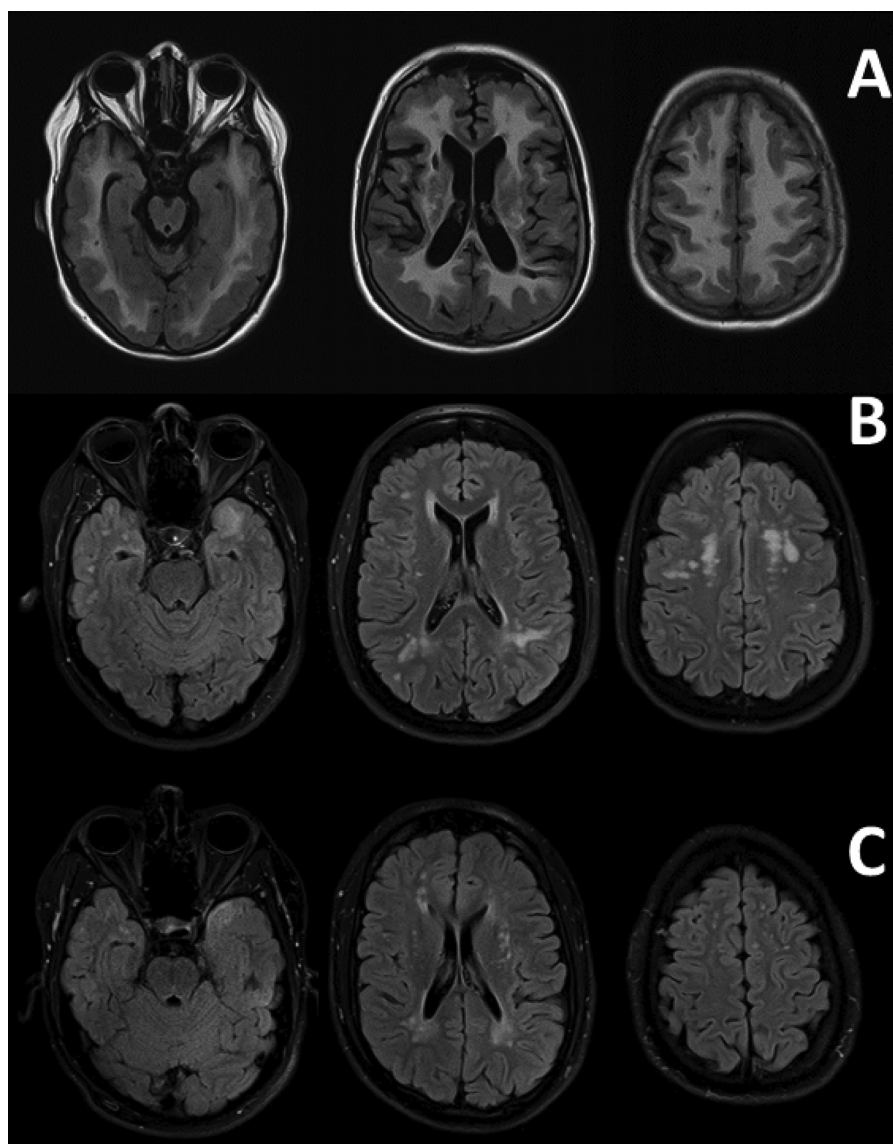
Progressive cognitive decline was noted. She scored 23/30 on the Montreal Cognitive Assessment (MoCA) at age 38 years. Her MRI showed extensive T2 hyperintensity in the white matter (Fig. 1B).

\* Corresponding author.

E-mail address: [bensonc@adhb.govt.nz](mailto:bensonc@adhb.govt.nz) (B.S. Chen).<https://doi.org/10.1016/j.seizure.2019.01.026>

Received 26 November 2018; Received in revised form 22 January 2019; Accepted 28 January 2019

1059-1311/ © 2019 British Epilepsy Association. Published by Elsevier Ltd. All rights reserved.



**Fig. 1.** MRI brain (FLAIR and T2 fat-suppressed sequences) of the proband (A), her daughter (B) and son (C), showing changes consistent with CADASIL including confluent white matter hyperintensities with involvement of the anterior temporal lobes. MRI were taken when the proband was aged 52, her daughter was 39, and son was 29 years old.

### 1.1.3. Patient 3

The proband's younger son was seen at age 25 years in 2013 with recurrent migraine headaches and two episodes of focal motor seizures with stiffening of his left arm and clenching of the fingers without loss of awareness. The arm and fingers then went numb and was followed by focal jerking of his left leg. Neurological examination was normal.

MRI showed multiple foci of T2 hyperintensity in the periventricular white matter and confluent areas involving the temporal lobes (Fig. 1C). In 2014 he commenced lamotrigine after a focal to bilateral tonic-clonic seizure. An interictal EEG showed bursts of poorly organised generalised 3–4 Hz spike-wave activity.

Levetiracetam was added after a generalised tonic-clonic seizure. He had three further seizures in 2017 in the context of medication non-adherence and excessive alcohol consumption. In March 2018 he scored 26/30 on the MoCA.

The proband's older son, aged 30 years-old, was asymptomatic. He did not have a history of migraine, epilepsy or cognitive impairment.

### 1.2. Genetic study

The search for a CADASIL mutation in the proband was first performed in 2009. Exons 3–6 of the *NOTCH3* gene were amplified by the polymerase chain reaction (PCR) and analysed by automated bidirectional fluorescent DNA sequencing. No *NOTCH3* mutation was identified compared to sequences in GenBank.

Testing was repeated in 2017 with amplification of exons 2–12 and exons 18–20 by PCR. Sequences were compared to the reference NM\_000435. 2. A mutation, c.1337 G > A [p.(Cys446Tyr)] was detected in exon 8. This mutation has not been reported previously in population databases (gnomAD, ExAC). Patients 2 and 3 both had the same mutation. Their brother, who did not have a history of epilepsy or symptoms suggestive of CADASIL, did not have the mutation.

### 1.3. Discussion

The majority of mutations causing CADASIL are cysteine-altering missense mutations. All three affected family members had epileptic seizures and the same *NOTCH3*:c.1337 G > A [p.(Cys446Tyr)]

mutation. In silico protein sequence analyses consistently predicted this variant to be damaging and to alter protein function. Similar variants, p.(Cys446Ser) and p.(Cys446Phe), have been reported in association with CADASIL, but not with epilepsy as an early symptom [2,3].

Seizures occur in only five to ten percent of CADASIL patients and rarely as an initial or early symptom. In one series of 102 CADASIL patients, only 10 had epileptic seizures of whom nine had a history of preceding stroke and it was presumed that the seizures had a structural aetiology [1]. In this series only one patient had focal seizures. Seizure recurrence occurred in five patients. None of the 29 families in this study had epilepsy as a prominent phenotype. In another series, only three percent of patients had seizures as an initial symptom of CADASIL [4]. None of the three patients we have reported had a history of stroke preceding onset of seizures.

The association between early epileptic seizures and p.(Cys446Tyr) in our patients may be coincidental and the seizures may represent what was previously termed an ‘idiopathic generalised epilepsy’. This is unlikely given the strong segregation of epilepsy and CADASIL in this kindred and the focal seizure semiology noted in the affected family members. The possibility of concurrent non-epileptic attacks cannot be completely excluded, but we believe this is an unlikely explanation for our patients’ symptoms. The third patient’s interictal EEG showed generalised epileptiform activity and the second patient sustained serious dental injuries during a seizure.

We suggest that testing for *NOTCH3*:c1337 G > A be considered in patients presenting with epilepsy as an early manifestation of CADASIL,

particularly when epilepsy precedes a history of stroke. Whether this mutation represents a distinct new phenotype requires further investigation.

#### Declarations of interest

None.

#### Acknowledgements

We would like to acknowledge Howard Potter (Molecular Pathology, Canterbury Health Laboratories), for his assistance with DNA sequencing.

#### References

- [1] Dichgans M, Mayer M, Uttner I, Bruning R, Muller-Hocker J, Rungger G, Ebke M, Klockgether T, Gasser T. The phenotypic spectrum of CADASIL: clinical findings in 102 cases. *Ann Neurol* 1998;44:731–9.
- [2] Lesnik Oberstein SA, van den Boom R, van Buchem MA, van Houwelingen HC, Bakker E, Vollebregt E, Ferrari MD, Breuning MH, Haan J, Dutch CRG. Cerebral microbleeds in CADASIL. *Neurology* 2001;57:1066–70.
- [3] Opherk C, Peters N, Herzog J, Luedtke R, Dichgans M. Long-term prognosis and causes of death in CADASIL: a retrospective study in 411 patients. *Brain* 2004;127:2533–9.
- [4] Desmond DW, Moroney JT, Lynch T, Chan S, Chin SS, Mohr JP. The natural history of CADASIL: a pooled analysis of previously published cases. *Stroke* 1999;30:1230–3.