



Volume-Staged CyberKnife Stereotactic Radiosurgery for Treatment of Drug-Resistant Epilepsy for a Spetzler-Martin Grade V Arteriovenous Malformation: A Case Report and Review of the Literature

Jeffrey I. Traylor¹, Garrett S. Johnson¹, Ramsey Ashour¹, Paiman Ghafoori², Robert J. Buchanan¹

Key words

- Arteriovenous malformation
- Drug-resistant epilepsy
- Spetzler-Martin grade
- Volume-staged stereotactic radiosurgery

Abbreviations and Acronyms

AVM: Arteriovenous malformation

D_{max}: Maximum dose

DRE: Drug-resistant epilepsy

MRI: Magnetic resonance imaging

SRS: Stereotactic radiosurgery

VS-SRS: Volume-staged stereotactic radiosurgery

From the Departments of ¹Neurosurgery and ²Women's Health, Dell Medical School, The University of Texas, Austin, Texas, USA

To whom correspondence should be addressed:

Jeffrey I. Traylor, B.S.

[E-mail: jeff.traylor@utexas.edu]

Citation: *World Neurosurg.* (2019) 125:329-332.

<https://doi.org/10.1016/j.wneu.2019.01.296>

Journal homepage: www.journals.elsevier.com/world-neurosurgery

Available online: www.sciencedirect.com

1878-8750/\$ - see front matter © 2019 Elsevier Inc. All rights reserved.

BACKGROUND

Cerebral arteriovenous malformations (AVMs) are pathologic connections of arteries and veins devoid of intervening capillaries within the brain parenchyma and pose a significant risk of morbidity from intracranial hemorrhage, epilepsy, and neurologic deficit.^{1,2} Seizures in particular are the second most common presentation of AVMs and are seen in up to 45% of cases.³ These seizures can be classified as sporadic, chronic, or drug-resistant epilepsy (DRE). Of these, DRE is reported in 1%–18% of cases, making this a rare presentation of AVM-induced epilepsy.³ Data on the management of DRE secondary to AVMs are sparse. Surgical resection has been used, but seizure control is significantly less likely to be achieved.⁴ In addition, high-grade AVMs (Spetzler-Martin grades IV and V) in eloquent brain regions with deep

■ **BACKGROUND:** Evidence to support the use of stereotactic radiosurgery (SRS) in the treatment of epilepsy secondary to cerebral arteriovenous malformations (AVMs) is emerging. However, these studies have not clearly demonstrated the use of SRS in the treatment of drug-resistant epilepsy (DRE) in high Spetzler-Martin grade (IV-V) AVMs.

■ **CASE DESCRIPTION:** We present a 48-year-old woman with DRE secondary to a Spetzler-Martin grade V cerebral AVM. She was treated with volume-staged SRS (VS-SRS) and achieved near-complete resolution of her seizures with incomplete obliteration of the AVM. Six years after treatment, she has experienced no serious complications.

■ **CONCLUSIONS:** VS-SRS successfully controlled seizures (Engel Outcome Measure of 1A) in a patient with intractable, DRE secondary to a high-grade cerebral AVM.

venous drainage are associated with significant morbidity and mortality.^{5,7} Treatment of these high-grade AVMs is challenging, and conservative management is generally recommended.⁸ The utility of volume-staged stereotactic radiosurgery (VS-SRS) for high-grade AVMs has been demonstrated, but its utility for managing DRE secondary to AVMs is still undefined.⁹⁻¹³ In this case report, we describe resolution of seizure activity in a patient with DRE secondary to a large Spetzler-Martin grade V cerebral AVM following treatment with VS-SRS.

CASE DESCRIPTION

A 48-year-old, right-handed female presented to our clinic with a 2-decade history of seizures secondary to what was deemed an inoperable right medial temporal lobe AVM. She was born at full term from a vaginal delivery and met all developmental milestones, though she possessed a mild underlying intellectual disability. At baseline, she was noted to have clear speech with delayed responses. Left hemianopsia was noted, but her neurologic examination was otherwise normal. She experienced 2–5 partial seizures per week,

occasionally progressing to generalized convulsions, despite multiple medication regimens. Her seizure episodes were characterized by right more than left myoclonus. At the time of her initial presentation, she was on a combination of 4 antiepileptic agents, still without control of her seizures, with significant quality-of-life impairment.

Brain imaging showed a Spetzler-Martin grade V AVM located in the region of the right Sylvian fissure, encompassing most of the temporal lobe and basal ganglia. It measured 6.2 cm and was supplied by the posterior and middle cerebral arteries with superficial and deep venous drainage (Figure 1). A saccular aneurysm involving the P1 segment of the right posterior cerebral artery measuring 5 × 6 mm was also noted, with multiple small vessels emanating from its dome.

Considering that her seizures were refractory to medical management and her AVM was not amenable to safe surgical resection or embolization, she was referred for VS-SRS treatment. Magnetic resonance imaging (MRI) planning was performed, and CyberKnife (Accuray Inc., Sunnyvale, California, United States) VS-SRS was delivered in 3 sessions at 12-week intervals.

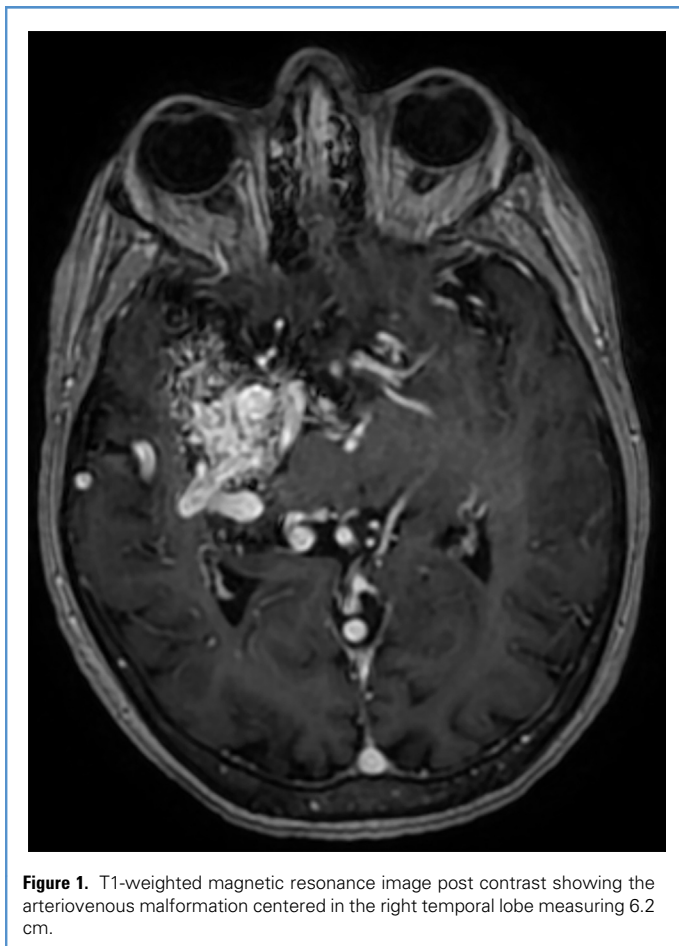


Figure 1. T1-weighted magnetic resonance image post contrast showing the arteriovenous malformation centered in the right temporal lobe measuring 6.2 cm.

During session 1, a volume of 7.0 mL was treated to a peripheral dose of 1600 cGy (maximum dose [D_{max}] 24.6 Gy, 65% isodose line) using 119 beams; in the second session a volume of 7.4 mL was treated to a peripheral dose of 1600 cGy (D_{max} 21.3 Gy, 75% isodose line) using 170 beams; and in the third session a volume of 8.3 mL was treated to a peripheral dose of 1600 cGy (D_{max} 21.3 Gy, 75% isodose line) using 143 beams. After treatment, she had a marked decrease in the frequency of her seizures. She continued on her 4-antiepileptic regimen and had continued seizure control. Her only reported seizures in the following 2 years occurred after not taking her medications for several days, and another instance following an assault during which she received mild head trauma. An MRI performed nearly 2 years after completion of VS-SRS showed the AVM to be significantly decreased in size (Figure 2). Now 6 years after SRS treatment, she has experienced no complications and

resolution of her seizure activity. She has achieved an Engel Outcome Measure of 1A, which denotes complete seizure relief without aura.¹⁴

DISCUSSION

The associated morbidity with cerebral AVMs results from the underlying pathogenesis; the lack of intervening capillaries between directly fistulized cerebral arteries and veins produces a turbulent high-flow, low-resistance system that draws blood away from higher-resistance vascular beds in adjacent tissue.¹⁵ The exact mechanism of epileptogenesis secondary to these lesions is largely unknown. However, numerous theories explaining this phenomenon have been described including underlying gliosis, disruption of the blood-brain barrier, ischemia, and hemosiderin deposition.¹⁶⁻¹⁹

Though the treatment of these lesions has evolved considerably over the past

several decades, there has been little evidence to support any 1 management approach for cerebral AVM patients, both in terms of controlling seizures or reducing hemorrhagic risk. Instead, conventional management options are stratified on the basis of Spetzler-Martin grade; patients with grade IV and V lesions were conservatively managed while those with grade I, II, and III lesions receive surgical intervention.^{5,20}

Recent studies investigating the efficacy of SRS for seizure resolution in AVM patients in particular have shown promising results. In a systematic review, Chen et al²¹ reported favorable seizure outcomes in cerebral AVM patients treated with SRS, although there was a significant difference in seizure-free status rates between complete and incomplete obliteration of the AVM. Przybylowski et al²² demonstrated better outcomes for simple partial or secondarily generalized seizure types following SRS, illuminating a possible indication for the use of SRS based on specific seizure symptoms. Ditty et al²³ further established long-term seizure control with successful discontinuation from antiepileptic medications after SRS management of cerebral AVMs.

For high-grade Spetzler-Martin grade AVMs, the role of SRS is only emerging. In 2017, Marciscano et al¹³ reported cure in patients with cerebral AVM with VS-SRS in approximately 40% of patients in an observational retrospective cohort study. That same year in a multi-institutional study, Patibandla et al¹⁰ described limited efficacy for single-session SRS in the management of Spetzler-Martin grade IV and V AVMs, with favorable outcome only achieved in a minority of unraptured high-grade AVMs, further complicating the perceived utility of SRS in these patients. The role of SRS in patients with DRE is also poorly understood. In a retrospective institutional cohort study, Lim et al²⁴ reported resolution of seizures in 8 of 15 total patients with DRE secondary to cerebral AVM.

Studies evaluating the effectiveness of SRS for seizure control in cerebral AVM patients have shown promising results, though they do not illustrate its utility for high-grade lesions or DRE. In our case, a patient with DRE secondary to an SM grade V AVM was treated with VS-SRS, with near-complete resolution of seizure

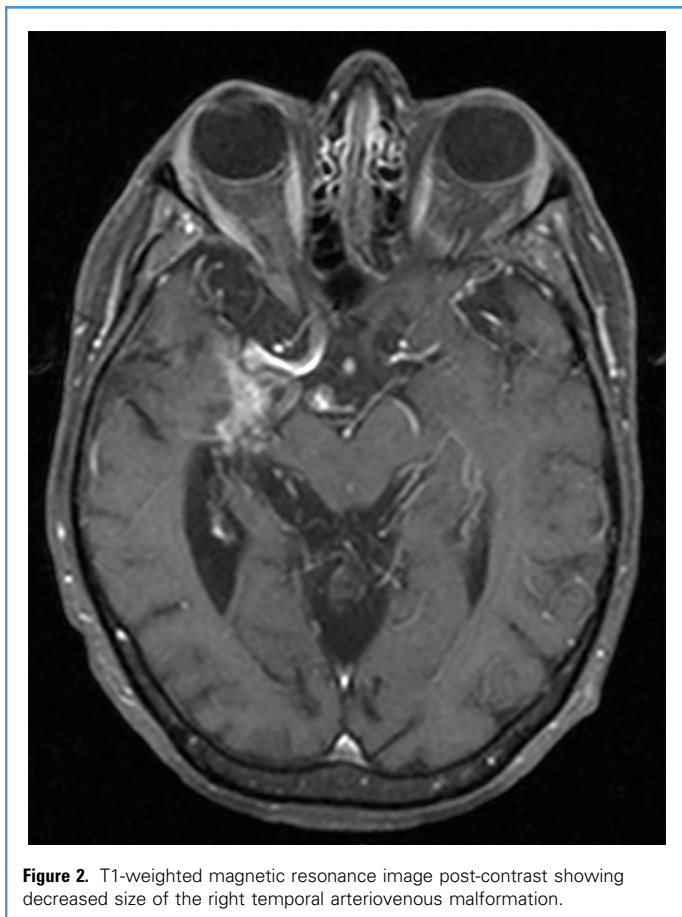


Figure 2. T1-weighted magnetic resonance image post-contrast showing decreased size of the right temporal arteriovenous malformation.

activity and without treatment-related complications. This report highlights SRS as a treatment option for DRE secondary to a high-grade cerebral AVM.

CONCLUSION

SRS can be considered for control of DRE in high-grade (Spetzler-Martin grade IV-V) cerebral AVMs after failure of medical management. Future studies comparing SRS with other treatment modalities for this patient population are warranted.

REFERENCES

1. Abecassis IJ, Xu DS, Batjer HH, Bendok BR. Natural history of brain arteriovenous malformations: a systematic review. *Neurosurg Focus*. 2014;37:E7.
2. Arteriovenous malformations of the brain in adults. *N Engl J Med*. 1999;340:1812-1818.
3. Schramm J. Seizures associated with cerebral arteriovenous malformations. *Handbook Clin Neurol*. 2017;143:31-40.
4. von der Brölie C, Simon M, Esche J, Schramm J, Bostrom A. Seizure outcomes in patients with surgically treated cerebral arteriovenous malformations. *Neurosurgery*. 2015;77:762-768.
5. Spetzler RF, Martin NA. A proposed grading system for arteriovenous malformations. *J Neurosurg*. 1986;65:476-483.
6. Davidson AS, Morgan MK. How safe is arteriovenous malformation surgery? A prospective, observational study of surgery as first-line treatment for brain arteriovenous malformations. *Neurosurgery*. 2010;66:498-504.
7. Spetzler RF, Ponce FA. A 3-tier classification of cerebral arteriovenous malformations. *Clinical article*. *J Neurosurg*. 2011;114:842-849.
8. Han PP, Ponce FA, Spetzler RF. Intention-to-treat analysis of Spetzler-Martin grades IV and V arteriovenous malformations: natural history and treatment paradigm. *J Neurosurg*. 2003;98:3-7.
9. Abula AA, Rutledge WC, Seymour ZA, et al. A treatment paradigm for high-grade brain arteriovenous malformations: volume-staged radiosurgical downgrading followed by microsurgical resection. *J Neurosurg*. 2015;122:419-432.
10. Patibandla MR, Ding D, Kano H, et al. Stereotactic radiosurgery for Spetzler-Martin Grade IV and V arteriovenous malformations: an international multicenter study. *J Neurosurg*. 2018;129:498-507.
11. Sirin S, Kondziolka D, Niranjan A, Flickinger JC, Maitz AH, Lunsford LD. Prospective staged volume radiosurgery for large arteriovenous malformations: indications and outcomes in otherwise untreatable patients. *Neurosurgery*. 2008;62(suppl 2):744-754.
12. Kano H, Kondziolka D, Flickinger JC, et al. Stereotactic radiosurgery for arteriovenous malformations, part 6: multistaged volumetric management of large arteriovenous malformations. *J Neurosurg*. 2012;116:54-65.
13. Marciscano AE, Huang J, Tamargo RJ, et al. Long-term outcomes with planned multistage reduced dose repeat stereotactic radiosurgery for treatment of inoperable high-grade arteriovenous malformations: an observational retrospective cohort study. *Neurosurgery*. 2017;81:136-146.
14. Engel J Jr. Outcome with respect to epileptic seizures. *Surg Treat Epilepsies*. 1993;609-621.
15. Mohr JP, Kejda-Scharler J, Pile-Spellman J. Diagnosis and treatment of arteriovenous malformations. *Curr Neurol Neurosci Rep*. 2013;13:324.
16. Leblanc FE. Cerebral seizures and brain tumors. *The Epilepsies, Textbook of Clinical Neurology*. In: Vinken PJ, Bruyn GW, eds. *Handbook of Clinical Neurology*. Amsterdam: Elsevier Science Publishers; 1974:295-305.
17. Stefan H, Pawlik G, Bocher-Schwarz HG, et al. Functional and morphological abnormalities in temporal lobe epilepsy: a comparison of interictal and ictal EEG, CT, MRI, SPECT and PET. *J Neurol*. 1987;234:377-384.
18. Wolf HK, Campos MG, Zentner J, et al. Surgical pathology of temporal lobe epilepsy. experience with 216 cases. *J Neuropathol Experiment Neurol*. 1993;52:499-506.
19. Englot DJ, Young WL, Han SJ, McCulloch CE, Chang EF, Lawton MT. Seizure predictors and control after microsurgical resection of supratentorial arteriovenous malformations in 440 patients. *Neurosurgery*. 2012;71:572-580.
20. Ogilvy CS, Stieg PE, Awad I, et al. Recommendations for the management of intracranial arteriovenous malformations: a statement for healthcare professionals from a special writing group of the Stroke Council, American Stroke Association. *Circulation*. 2001;103:2644-2657.
21. Chen CJ, Chivukula S, Ding D, et al. Seizure outcomes following radiosurgery for cerebral arteriovenous malformations. *Neurosurg Focus*. 2014;37:E17.

22. Przybylowski CJ, Ding D, Starke RM, et al. Seizure and anticonvulsant outcomes following stereotactic radiosurgery for intracranial arteriovenous malformations. *J Neurosurg.* 2015;122:1299-1305.
23. Ditty BJ, Omar NB, Foreman PM, et al. Seizure outcomes after stereotactic radiosurgery for the treatment of cerebral arteriovenous malformations. *J Neurosurg.* 2017;126:845-851.
24. Lim YJ, Lee CY, Koh JS, Kim TS, Kim GK, Rhee BA. Seizure control of Gamma Knife

radiosurgery for non-hemorrhagic arteriovenous malformations. In: Chang JW, Katayama Y, Yamamoto T, eds. *Advances in Functional and Reparative Neurosurgery.* Vienna, Austria: Springer Vienna; 2006:97-101.

Conflict of interest statement: The authors have no other conflict of interest, financial or otherwise, to disclose at this time.

Received 26 December 2018; accepted 31 January 2019

Citation: World Neurosurg. (2019) 125:329-332.

<https://doi.org/10.1016/j.wneu.2019.01.296>

Journal homepage: www.journals.elsevier.com/world-neurosurgery

Available online: www.sciencedirect.com

1878-8750/\$ - see front matter © 2019 Elsevier Inc. All rights reserved.