

Thrombolysis in an acute ischemic stroke patient with rivaroxaban anticoagulation

A case report

Yen-Tung Chao, MD^a, Chaur-Jong Hu, MD^{a,b,c}, Lung Chan, MD, PhD^{a,b,c,*}

Abstract

Rationale: Whether intravenous recombinant tissue plasminogen activator (r-TPA) therapy can be administered in acute ischemic stroke patients treated with novel oral anticoagulants (NOACs), including rivaroxaban, remains controversial.

Patient concerns: A 76-year-old woman with nonvalvular atrial fibrillation, who had been receiving 15 mg rivaroxaban once daily, was brought to the emergency department with right-side hemiparesis and aphasia. The onset of neurological deficits occurred 8 hours after the last dose of rivaroxaban administration.

Diagnosis: The patient was diagnosed with acute ischemic stroke.

Interventions: Intravenous infusion of 0.6 mg/kg of r-TPA (total dose: 29 mg) was performed 9 hours and 40 minutes after the last rivaroxaban administration. During r-TPA infusion, improvement in the patient's neurological deficit was observed.

Outcomes: The clinical picture evidently improved from with National Institutes of Health Stroke Scale 21 to 16 on completion of r-TPA treatment.

Lessons: Although current guidelines do not recommend administering thrombolytics in patients using NOACs with a doubtful anticoagulation status and administered within the last 24 or, even more strictly, 48 hours, this and other case studies suggest that r-TPA treatment could be considered in selected acute ischemic stroke patients receiving rivaroxaban or other Xa inhibitors, taking the patient's clinical condition and the prospective clinical benefits of r-TPA into account.

Abbreviations: aPTT = activated partial thromboplastin time, INR = international normalized ratio, NIHSS = National Institutes of Health Stroke Scale, NOACs = novel oral anticoagulants, PAR = protease-activated receptors, PT = prothrombin time, r-TPA = recombinant tissue plasminogen activator, Xa = ten activated.

Keywords: ischemic stroke, novel oral anticoagulants, rivaroxaban, thrombolysis, tissue plasminogen activator

1. Introduction

Whether intravenous recombinant tissue plasminogen activator (r-TPA) therapy can be administered in acute ischemic stroke patients treated with rivaroxaban remains controversial.^[1–12] Approximately, 1% to 2% of patients with nonvalvular atrial fibrillation will experience an acute ischemic stroke despite receiving novel oral anticoagulants (NOACs).^[13] Thus far, r-TPA treatment has not been recommended for patients receiving rivaroxaban because of the increased risk of intracranial

hemorrhage, in the absence of adequate drug elimination, and clearance or specific tests validating the lack of an anticoagulant effect.^[14,15] However, many of these patients will be critically evaluated at emergency rooms for eligibility for acute recanalization therapies including r-TPA and the use of intravenous thrombolysis could be safe under certain conditions. Withholding r-TPA therapy with no exception to all patients with acute ischemic stroke under rivaroxaban may also deny a considerable number of stroke patients an effective and innocuous treatment.

2. Case report

We report the case of a 76-year-old woman with a history of nonvalvular atrial fibrillation and hypertension, who had been receiving 15 mg rivaroxaban once daily since an episode of right middle cerebral arterial territory infarction 19 months earlier. Her CHADS₂-VAS_c was 6. Adequate adherence to treatment was confirmed by her son. She arrived in the emergency department with an abrupt onset of consciousness disturbance, expressive aphasia, and right hemiparesis that occurred 30 minutes before the initial evaluation. The National Institutes of Health Stroke Scale (NIHSS) was 21. The onset of neurological deficits occurred 8 hours after the last dose of rivaroxaban administration. Clinical data on admission were as follows: blood pressure, 121/76 mmHg; prothrombin time (PT), 16.4 seconds (control: 11.0–14.5 seconds); international normalized ratio (INR), 1.41; activated partial thromboplastin time (aPTT), 137.0 seconds (normal:

Editor: N/A.

Exempt from informed consent for the case, Taipei Medical University - Joint Institutional Review Board (TMU-JIRB) approval No. N201809044.

The authors have no conflicts of interest to disclose.

^a Department of Neurology, Taipei Medical University, Shuang Ho Hospital,

^b Department of Neurology, School of Medicine, College of Medicine, ^c Taipei Neuroscience Institute, Taipei Medical University, New Taipei City, Taiwan.

* Correspondence: Lung Chan, College of Medicine and Shuang-Ho Hospital, Taipei Medical University, New Taipei City, Taiwan (e-mail: cjustinmd@gmail.com).

Copyright © 2019 the Author(s). Published by Wolters Kluwer Health, Inc.

This is an open access article distributed under the Creative Commons Attribution License 4.0 (CCBY), which permits unrestricted use, distribution, and reproduction in any medium, provided the original work is properly cited.

Medicine (2019) 98:8(e14560)

Received: 19 October 2018 / Received in final form: 14 January 2019 /

Accepted: 23 January 2019

<http://dx.doi.org/10.1097/MD.0000000000014560>

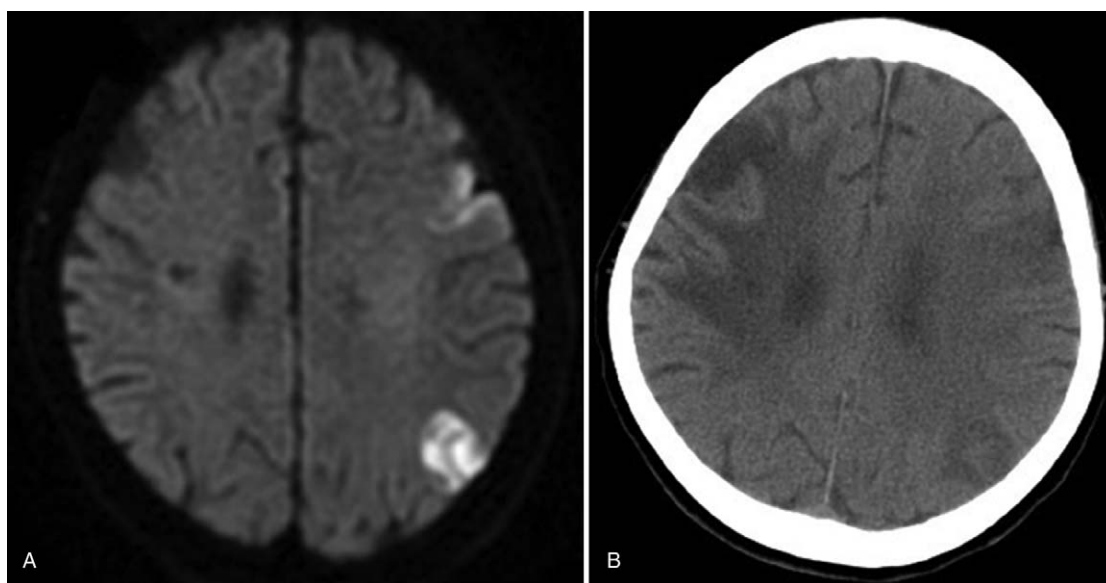


Figure 1. (A) Diffusion-weighted image. Hyperintense areas are observed in the left cortex and the posterior part of the middle cerebral arterial territory. (B) Computed tomography showing left cerebral infarction without hemorrhagic changes in the same site.

32.0–45.1 seconds); thrombocyte count, $133 \times 10^3 \text{ mm}^3$ (normal: 130×10^3 – $400 \times 10^3 \text{ mm}^3$); and creatinine level, 0.71 mg/dL, with an estimated glomerular filtration rate of 85.1 mL/min/1.73 m². Electrocardiography revealed atrial fibrillation. Conventional brain noncontrast computed tomography (CT) showed encephalomalacia at the right fronto-temporo-parietal lobe due to a previous infarction of the right middle cerebral arterial territory. CT angiography revealed luminal narrowing of the right cavernous internal carotid artery, left cavernous internal carotid artery, and basilar artery. An acute ischemic stroke was diagnosed. We did not initiate endovascular intervention because her son did not agree to this invasive treatment, citing personal reasons. After considering the patient's clinical condition and the prospective clinical benefits of r-TPA, we decided to treat the patient in spite of the guideline recommending an at least 24-hour interval between rivaroxaban intake and thrombolysis. Intravenous infusion of 0.6 mg/kg of r-TPA (total dose: 29 mg) was thus performed 9 hours and 40 minutes after the last rivaroxaban administration, with informed consent. During r-TPA infusion, improvement in the patient's neurological deficit was observed (NIHSS score, 16 on completion of infusion), and her blood pressure and heart rate were adequately controlled. Brain magnetic resonance imaging (Fig. 1A) showed gyriform diffusion restriction in the left frontal, occipito-temporal, and parietal cortico-juxtacortical imaging series 16 hours after the onset of symptoms. A brain CT scan (Fig. 1B) performed 24 hours after r-TPA administration revealed no hemorrhagic change, with an NIHSS score of 14. After 4 weeks, the patient was discharged with an NIHSS score of 13 and remaining neurological sequelae of the right hemiparesis and motor aphasia.

3. Discussion

The safety and protocol for use of thrombolytic therapy after recent NOAC intake has still not been established. No randomized trials on the safety of r-TPA with rivaroxaban have been performed. Both the guidelines on thrombolysis and many studies insist on the necessity of normal coagulant tests as crucial criteria

for r-TPA eligibility.^[16,17] However, conventional tests such as prothrombin time/international normalized ratio (PT/INR) and activated partial thromboplastin time (aPTT) are unreliable for measuring the anticoagulant effects of any NOACs.^[4,18] Although anti-Xa activity assays measure rivaroxaban concentration more precisely, they are not generally accessible, and their results may not be immediately available.^[19,20] Several other cases describing thrombolytic treatment in patients receiving rivaroxaban without hemorrhagic complications have been reported.^[1,6,8,21,22] The r-TPA dosages administered in such patients, including the standard protocol (0.9 mg/kg) and adjusted dose (0.6 mg/kg), are variably performed, with quite different outcomes.^[1,2,4–11] Fatal intraperitoneal hemorrhage with no clinical improvement was reported in a patient receiving r-TPA treatment at a dose of 0.6 mg/kg.^[2] Considering the prolonged aPTT test and uncertain anticoagulation status, we adopted a strategy of low-dose (0.6 mg/kg) r-TPA treatment. Nevertheless, one retrospective study indicated that intravenous r-TPA in NOAC patients (including 129 cases with rivaroxaban), as selected by their treating physician, is not associated with statistically significantly increased symptomatic intracranial hemorrhage risk (either serious systemic hemorrhage or r-TPA complication) compared with patients receiving warfarin or without an oral anticoagulant.^[23] Although rivaroxaban may favor hemorrhagic transformation, no correlation exists with the patient's clinical severity after intravenous thrombolysis.^[24] Moreover, one study on Wistar rats revealed down-regulation of protease-activated receptor (PAR)-1 and PAR-2 expression in peri-ischemic lesions in the rivaroxaban group compared with the warfarin group. PAR-1 and PAR-2 play a role in modulating the effects of coagulation factors such as thrombin, factor Xa, and TPA and are associated with inflammation and neurodegeneration in stroke.^[25] This mechanism may also explain why, after induced cerebral artery occlusion and reperfusion with r-TPA, Wistar rats on rivaroxaban had a significantly lower intracranial hemorrhage volume.^[25]

In our case, blood sampling was performed 9 hours and r-TPA administered 9 hours and 40 minutes after the last rivaroxaban intake, when the anticoagulant effect of rivaroxaban could be

potent. Specifically, intravenous infusion of 0.6 mg/kg of r-TPA (total dose: 29 mg) was performed in a patient with extended aPTT. Considering at once the stroke severity, the expected clinical benefit, and the lack of alternative treatment, we explained the risks and benefits of this treatment to her relatives and performed it with their informed consent. No adverse events or intracranial hemorrhage occurred. The results in this case could imply that routine coagulation tests cannot precisely reflect plasma concentration or the anticoagulant effect of rivaroxaban mentioned in other studies.^[26] However, this may also have been only a special case, so that whether the same clinical improvement and outcome could be reproduced is debatable.

4. Conclusion

Little information is available regarding cases treated with intravenous r-TPA while receiving rivaroxaban. Although current guidelines do not recommend administering thrombolytics in patients using NOACs with a doubtful anticoagulation status and administered within the last 24 or, even more strictly, 48 hours, this and other case studies, although limited and debatable, suggest that low-dosage and, if possible, individualized r-TPA treatment could be considered in selected acute ischemic stroke patients receiving rivaroxaban or other Xa inhibitors. However, additional studies are necessary to establish the optimal treatment strategy and safety profiles of thrombolysis with r-TPA in stroke patients treated with NOACs.

Acknowledgments

This manuscript was edited by Wallace Academic Editing.

Author contributions

Conceptualization: Yen Tung Chao.

Data curation: Yen Tung Chao.

Formal analysis: Yen Tung Chao.

Project administration: Chaur-Jong Hu.

Resources: Yen Tung Chao.

Software: Yen Tung Chao.

Supervision: Lung Chan, Chaur-Jong Hu.

Validation: Lung Chan.

Writing – original draft: Yen Tung Chao.

Writing – review & editing: Yen Tung Chao, Lung Chan.

Yen Tung Chao orcid: 0000-0001-8812-6748.

References

- [1] Ishihara H, Torii H, Imoto H, et al. Intravenous thrombolysis with recombinant tissue plasminogen activator in a stroke patient treated with rivaroxaban. *J Stroke Cerebrovasc Dis* 2014;23:e457–9.
- [2] Anan C, Oomura M, Saeki T, et al. Fatal intraperitoneal bleeding after intravenous administration of tissue plasminogen activator. *J Stroke Cerebrovasc Dis* 2015;24:e177–8.
- [3] Korya D, Dababneh H, Moussavi M, et al. Intravenous thrombolysis in a patient using factor Xa inhibitor. *J Vasc Interv Neurol* 2014;7:1–4.
- [4] Kawiorski MM, Alonso-Canovas A, de Felipe Mimbres A, et al. Successful intravenous thrombolysis in acute ischaemic stroke in a patient on rivaroxaban treatment. *Thromb Haemost* 2014;111:557–8.
- [5] van Hooff RJ, Nieboer K, De Smedt A, et al. Intravenous thrombolysis with recombinant tissue plasminogen activator for acute ischemic stroke in a patient treated with rivaroxaban. *Clin Neurol Neurosurg* 2014;122:133–4.
- [6] Landais A, Ginoux C. Intravenous thrombolysis for acute ischemic stroke in a patient receiving rivaroxaban. *J Stroke Cerebrovasc Dis* 2015;24:e73–4.
- [7] Fluri F, Heinen F, Kleinschnitz C. Intravenous thrombolysis in a stroke patient receiving rivaroxaban. *Cerebrovasc Dis Extra* 2013;3:153–5.
- [8] Nardetto L, Tonello S, Zuliani L, et al. Intravenous thrombolysis for acute stroke in a patient on treatment with rivaroxaban. *Neurol Sci* 2015;36:2291–2.
- [9] Bornkamm K, Harloff A. Safe intravenous thrombolysis in acute stroke despite treatment with rivaroxaban. *J Clin Neurosci* 2014;21:2012–3.
- [10] Neal AJ, Campbell BC, Chandratheva A, et al. Intravenous thrombolysis for acute ischaemic stroke in the setting of rivaroxaban use. *J Clin Neurosci* 2014;21:2013–5.
- [11] Seiffge DJ, Traenka C, Gensicke H, et al. Intravenous thrombolysis in stroke patients receiving rivaroxaban. *Eur J Neurol* 2014;21:e3–4.
- [12] Seiffge DJ, Hooff RJ, Nolte CH, et al. Recanalization therapies in acute ischemic stroke patients: impact of prior treatment with novel oral anticoagulants on bleeding complications and outcome. *Circulation* 2015;132:1261–9.
- [13] Powers WJ, Derdeyn CP, Biller J, et al. 2015 American Heart Association/American Stroke Association focused update of the 2013 guidelines for the early management of patients with acute ischemic stroke regarding endovascular treatment. *Stroke* 2015;46:3020–35.
- [14] Heidebuchel H, Verhamme P, Alings M, et al. Updated European heart rhythm association practical guide on the use of non-vitamin-K antagonist anticoagulants in patients with non-valvular atrial fibrillation: executive summary. *Eur Heart J* 2017;38:2137–49.
- [15] Heidebuchel H, Verhamme P, Alings M, et al. Updated European heart rhythm association practical guide on the use of non-vitamin K antagonist anticoagulants in patients with non-valvular atrial fibrillation. *Europace* 2015;17:1467–507.
- [16] Jauch EC, Saver JL, Adams HP, et al. Guidelines for the early management of patients with acute ischemic stroke: a guideline for healthcare professionals from the American Heart Association/American Stroke Association. *Stroke* 2013;44:870–947.
- [17] Alberts MJ, Bernstein RA, Naccarelli GV, et al. Using dabigatran in patients with stroke: a practical guide for clinicians. *Stroke* 2012;43:271–9.
- [18] Folyovich A, Varga V, Béres-Molnár KA, et al. Dilemma of indication for thrombolysis in a patient with acute ischemic stroke treated with a novel oral anticoagulant. *J Stroke Cerebrovasc Dis* 2014;23:580–2.
- [19] Samama MM, Contant G, Spiro TE, et al. Laboratory assessment of rivaroxaban: a review. *Thromb J* 2013;11:11.
- [20] Samama MM, Contant G, Spiro TE, et al. Evaluation of the anti-factor Xa chromogenic assay for the measurement of rivaroxaban plasma concentrations using calibrators and controls. *Thromb Haemost* 2012;107:379–87.
- [21] Cappellari M, Bovi P. Intravenous thrombolysis for stroke in patients taking non-VKA oral anticoagulants: an update. *Thromb Haemost* 2015;114:440–4.
- [22] Penge J, Hashi S, Simister R. Successful intravenous thrombolysis following full dose rivaroxaban 5 hours before ictus. *Br J Hosp Med (Lond)* 2015;76:244–5.
- [23] Xian Y, Federspiel JJ, Hernandez AF, et al. Use of intravenous recombinant tissue plasminogen activator in patients with acute ischemic stroke who take non-vitamin K antagonist oral anticoagulants before stroke. *Circulation* 2017;135:1024–35.
- [24] Rota E, Bruzzone G, Agosti S, et al. A case report of parenchymal hematoma after intravenous thrombolysis in a rivaroxaban-treated patient. *Medicine (Baltimore)* 2017;96:e9435.
- [25] Morihara R, Yamashita T, Kono S, et al. Reduction of intracerebral hemorrhage by rivaroxaban after tPA thrombolysis is associated with downregulation of PAR-1 and PAR-2. *J Neurosci Res* 2017;95:1818–28.
- [26] Jauch EC, Saver JL, Adams HP Jr, et al. Guidelines for the early management of patients with acute ischemic stroke: a guideline for healthcare professionals from the American Heart Association/American Stroke Association. *Stroke J Cereb Circ* 2013;44:870–947.