

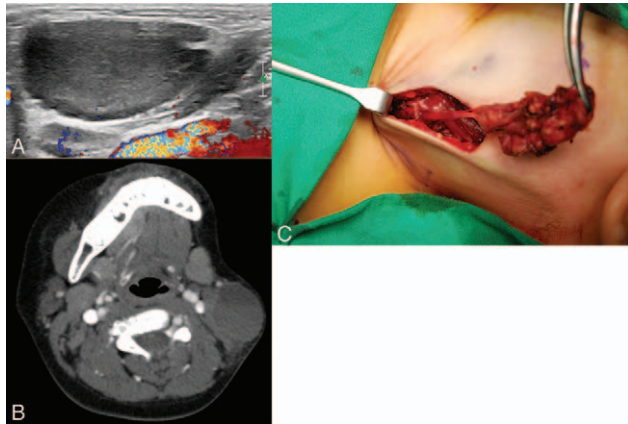FIGURE 1. Neck ultrasonography (A) and computed tomograph (B) scans demonstrate an approximately 4 cm cystic mass with hemorrhagic change in the left lateral neck, located lateral to the sternocleidomastoid muscle. (C) Intraoperative photo shows left external jugular vein aneurysm.

The treatment of choice for EJV aneurysm is surgical excision for cosmetic purposes and avoidance of potential complications, such as thromboembolism or rupture.^{1–5}

In conclusion, it is important to distinguish EJV aneurysm from other neck lesions, including congenital disease. In addition, it should be noted that in hemophilia patients, an EJV aneurysm may occur in a spontaneous or small trauma.

REFERENCES

1. Al-Shaikhi A, Kay S, Laberge JM. External jugular venous aneurysm: an unusual cause of a neck mass in a young child. *J Pediatr Surg* 2003;38:1557–1559
2. Verma RK, Kaushal D, Panda NK. External jugular vein aneurysm with thrombus presenting as painful neck mass: a case report. *Oman Med J* 2013;28:278–280
3. Başbuğ HS, Bitargil M, Karakurt A, et al. External jugular vein aneurysm in a young woman: an uncommon cause. *Int J Cardiovasc Acad* 2016;2:16–18
4. Kaur K, Bhardwaj M, Sangwan A, et al. Resection of left external jugular vein aneurysm—a challenge for anaesthetist and surgeon. *Egypt J Anaesth* 2016;32:241–242
5. Lucatelli P, Tommasino G, Guaccio G, et al. External jugular vein spontaneous aneurysm, diagnosis, and treatment with video. *Ann Vasc Surg* 2017;41:282e11–3

Unexpected Intracranial Hemorrhage and Death After Cranioplasty in a Patient With Massive Hemispheric Infarction

Guodao Wen, MD, Peng Zeng, MD, Jinyao Zhou, MD, Guangbing Wang, MD, Guiping Wu, MD, Wensheng Zeng, MD, and Dan Zhou, MD

Abstract: The benefits and common complications of cranioplasty are often mentioned, but fatal complications are rarely documented.

Here, the authors report a patient of intracranial hemorrhage and death after cranioplasty and discussed the possible mechanism. A 42-year-old man was admitted with the diagnosis of massive cerebral infarction in left fronto-temporo-parietal lobe, emergency surgery for decompressive large craniotomy and Encephalo-Myo-Synangiosis were performed. One year after surgery, cranioplasty was performed using a titanium mesh plate. Intraoperative cerebrospinal fluid leakage was occurred and dura mater was repaired using pieces of silk. During the postoperative anesthesia emergence, the patient had epileptic seizures and did not wake after surgery. The authors also observed about 150 mL bloody cerebrospinal fluid (CSF) in the subcutaneous vacuum drainage system within 2 hours. Emergency computed tomography of the brain showed epidural, subdural, subarachnoid hemorrhages in the posts ischemic area, the middle line left, and the brain stem swelling. The patient's family refused to immediately remove the titanium mesh plate. Finally, nonoperative treatment is invalid and the patient's neurological condition did not recover and he died 3 days after the surgery. In the authors' mind, patients with previous massive cerebral infarction and Encephalo-Myo-Synangiosis undergoing cranioplasty might be at heightened risk of a fatal event than other cranioplasty. Therefore, the patients should be paid more attention to prevent and treat the fatal complications.

Key Words: Cranioplasty, death, intracerebral hemorrhage, massive cerebral infarction

Cranioplasty is a standard neurosurgical procedure which is usually performed after decompressive craniotomy for several neurological conditions.^{1–3} The benefits and common complications of cranioplasty are often mentioned, but fatal complication are rarely documented.^{4,5} In a reported series of 239 patients, the overall complication rate was 23.8% and no deaths occurred.^{6,7} Here, we report a case of intracranial hemorrhage and death after cranioplasty and discuss the potential pathological mechanisms.

CLINICAL REPORT

A 42-year-old man was admitted with the diagnosis of massive cerebral infarction in left fronto-temporo-parietal lobe. On day 1, physical examination revealed that progressive neurological impairment (Glasgow Coma Scale 9 to 4) had happened, the pupil size of both eyes was not equal (left 5.0 mm, right 4.0 mm) and pupillary reaction to light was absent. Therefore, the patient underwent emergency large craniotomy (left fronto-temporo-parietal lobe bone flap) and Encephalo-Myo-Synangiosis. The MRI+MRA MRA scanning taken in half a month after operation showed massive cerebral infarction in left fronto-temporo-parietal lobe and an extensive left middle cerebral artery territory infarction.

After medicine conservative and comprehensive rehabilitation treatment for 2 months, the patient regained consciousness and had

From the Tungwah Hospital of Sun Yat-Sen University, Dongguan, China. Received November 6, 2018.

Accepted for publication January 27, 2019.

Address correspondence and reprint requests to Peng Zeng, MD, Tungwah Hospital of Sun Yat-Sen University, Dongguan 523000, China;

E-mail: 15261898010@163.com

The authors report no conflicts of interest. Copyright © 2019 by Mutaz B. Habal, MD ISSN: 1049-2275

DOI: 10.1097/SCS.00000000000005426

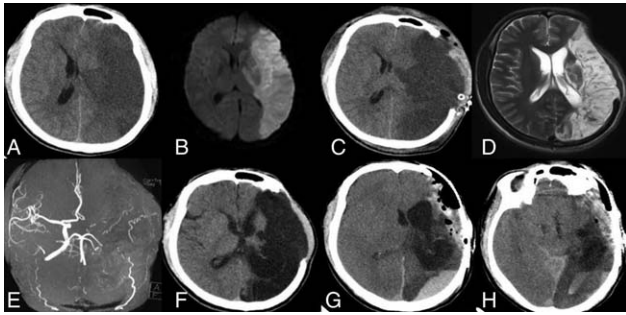


FIGURE 1. The imaging data of a 42-year-old man was admitted with the diagnosis of massive cerebral infarction. (A) Head CT scan showing massive cerebral infarction before decompressive large craniotomy and Encephalo-Myo-Synangiosis. (B) Head magnetic resonance imaging scan before decompressive large craniotomy and Encephalo-Myo-Synangiosis. (C) Head CT scan after decompressive large craniotomy and Encephalo-Myo-Synangiosis. (D) Head magnetic resonance imaging scan after decompressive large craniotomy and Encephalo-Myo-Synangiosis. (E) Head MRA scan showing an extensive left middle cerebral artery territory infarction. (F) Head CT scan showing massive cerebral infarction before cranioplasty. (G) Head CT scan showing epidural hematoma and subdural hematoma in the postischemic area after cranioplasty. (H) Head CT scan showing the middle line left and the brain stem swelling after cranioplasty. CT, computed tomography.

his phonation, and the right-sided hemiparesis also had improved (right lower extremity muscle strength grade 4).

One year after surgery, because of good wound healing and the patient's desire, he was newly admitted to the hospital for titanium mesh plate repositioning. Preoperative control computed tomography did not show any abnormality except for a large left postischemic area. Routine screenings were in the normal range, and antiplatelet drugs were stopped taking 2 weeks ago (Fig. 1).

Intraoperative cerebrospinal fluid (CSF) leakage occurred and dura mater was repaired tightly using pieces of silk. During the postoperative anesthesia emergence, the patient experienced generalized epileptic seizures and did not wake. We also observed about 150 mL bloody CSF in the subcutaneous vacuum drainage system within 2 hours after surgery. Emergency computed tomography of the brain showed epidural hematoma and subdural hematoma in the postischemic area, the middle line left, and the brain stem swelling.

The patient had been in a coma (GCS 3), and did not recover to normal respiration. The patient's family refused to remove the titanium mesh plate and any other surgeries. Finally, nonoperative treatment was invalid. The patient's neurological condition did not recover and he died 3 days after the surgery.

DISCUSSION

Cranioplasty is performed not only to restore the normal cranial architecture but also to protective functions of the skull in patients undergoing large craniectomy.^{1,4} The surgical procedure of cranioplasty is generally considered safe, and the reported mortality rate is low.¹

The exact mechanism underlying intracranial hemorrhage and death after cranioplasty has not yet been fully understood. Few similar cases were reported in other centers, and the authors in this previous report speculated that decrease in intracranial pressure, the subsequent rapid expansion of the brain and fatal vasomotor reaction leads to the reperfusion injury and cerebral vascular accident.^{4,5,8-12} However, from July 2010 to May 2018, 235 titanium mesh cranioplasties were performed at the authors' institution, only including 1 death. Every patient had the similar

surgical risk of reperfusion injury and cerebral vascular accident, and all surgeries were performed by skilled surgeons and the same methods.

Why only death for this patient? We suggested that the patients with previous massive cerebral infarction and Encephalo-Myo-Synangiosis undergoing cranioplasty might be at heightened risk of a fatal event than other cranioplasties.

First, the infarct brain may have a different compliance compared with normal brain under the long-term atmospheric pressure. The negative pressure difference owing to the elimination of atmospheric pressure that had been chronically applied to the infarct shrinking brain combined with the negative pressure applied by the closed subgaleal suction drain may have led to a massive brain shift toward the cranioplasty site and initiated a fatal vasomotor reaction.

Second, the infarct brain may likely induce epileptic seizure, especially in the infarct brain combined with secondary intracerebral hemorrhage. Postoperative seizure, may lead to sustained hypoxic brain, and then result in brain swelling.

Last but not the least, there were many specific physiological mechanisms in Encephalo-Myo-Synangiosis brain region: all kinds of inflammatory reaction cells, fibrocytes and blood capillary hyperplasia formed granulation swollen; local brain and temporal muscle was closely packed; pseudomeninges gradually formed. All the above factors may lead to hard to pull apart temporal muscle from brain tissue, and may raise the risk of postoperative hematoma formation.

CONCLUSION

Patients with previous massive cerebral infarction and Encephalo-Myo-Synangiosis undergoing cranioplasty might be at heightened risk of a fatal event than other cranioplasty. Therefore, the patients should be paid more attention to prevent and treat the fatal complications.

REFERENCES

- Piazza M, Grady MS. Cranioplasty. *Neurosurg Clin N Am* 2017;28:257-265
- Morton RP, Abecassis IJ, Hanson JF, et al. Timing of cranioplasty: a 10.75-year single-center analysis of 754 patients. *J Neurosurg* 2017;128:1648-1652
- Missori P, Curra A, Peschillo S, et al. Intracerebral hemorrhage after cranioplasty: an unpredictable treacherous complication due to reperfusion or possible systemic inflammatory response syndrome. *Neurol Sci* 2018;39:959-960
- Kato A, Morishima H, Nagashima G. Unexpected complications immediately after cranioplasty. *Acute Med Surg* 2017;4:316-321
- Cecchi PC, Rizzo P, Campello M, et al. Haemorrhagic infarction after autologous cranioplasty in a patient with sinking flap syndrome. *Acta Neurochir (Wien)* 2008;150:409-410
- Nomura M, Ota T, Ishizawa M, et al. Intracranial hypotension-associated cerebral swelling following cranioplasty: Report of two cases. *Asian J Neurosurg* 2017;12:794-796
- Zanaty M, Chalouhi N, Starke RM, et al. Complications following cranioplasty: incidence and predictors in 348 cases. *J Neurosurg* 2015;123:182-188
- Shen L, Zhou Y, Xu J, et al. Malignant cerebral swelling after cranioplasty: case report and literature review. *World Neurosurg* 2018;110:4-10
- Kaneshiro Y, Murata K, Yamauchi S, et al. Fatal cerebral swelling immediately after cranioplasty: a case report. *Surg Neurol Int* 2017;8:156
- Sviri GE. Massive cerebral swelling immediately after cranioplasty, a fatal and unpredictable complication: report of 4 cases. *J Neurosurg* 2015;123:1188-1193
- Lee GS, Park SQ, Kim R, et al. Unexpected severe cerebral edema after cranioplasty: case report and literature review. *J Korean Neurosurg Soc* 2015;58:76-78

12. Martin KD, Franz B, Kirsch M, et al. Autologous bone flap cranioplasty following decompressive craniectomy is combined with a high complication rate in pediatric traumatic brain injury patients. *Acta Neurochir (Wien)* 2014;156:813–824

Infected Lingual Thyroglossal Duct Cyst Mimicking Supraglottitis

Jen-Hao Hsiao, MD,* Wei-Chieh Chao, MD,*† and Yi-Chan Lee, MD*†

Abstract: A thyroglossal duct cyst (TGDC) is a common embryological remnant that typically presents as an anterior neck mass; however, this malformation can occur in any adjacent area, including the tongue base (lingual type), along the migration path of the thyroid during embryonic development. Lingual TGDC is often quiescent until infection occurs. Supraglottitis or inflammation of the supraglottis, is a potentially life-threatening disease. Because of the anatomical proximity of lingual TGDC to the supraglottis, lingual TGDC infection might be related to a presentation of supraglottitis. A 49-year-old male initially presented with clinical symptoms of acute supraglottitis. After intensive medical treatment resulting in no improvement, a computed tomography scan was performed. The result raised the suspicion of an infected lingual TGDC. Transoral marsupialization using a rigid laryngoscope was performed to drain the abscess inside the cyst. A diagnosis of lingual TGDC was made based on the characteristic histological pattern of the lesion. After treatment, a follow-up computed tomography scan showed no evidence of recurrence. To the authors' knowledge, only a few reports have pointed out similarities in the clinical and radiological findings between acute supraglottitis and an infected lingual TGDC. Clinicians should consider lingual TGDC during the differential diagnosis of supraglottitis, especially in patients with poor response to medical treatment.

Key Words: Epiglottitis, infection, lingual thyroglossal duct cyst, supraglottitis

The primitive thyroid gland originates from the foramen cecum and descends from the pharyngeal floor in front of the hyoid

From the *Department of Otolaryngology—Head and Neck Surgery, Chang Gung Memorial Hospital, Keelung; and †College of Medicine, Chang Gung University, Tao-Yuan, Taiwan.

Received November 25, 2018.

Accepted for publication January 27, 2019.

Address correspondence and reprint requests to Yi-Chan Lee, MD, Department of Otolaryngology—Head and Neck Surgery, Chang Gung Memorial Hospital, No. 222, Maijin Road, Anle District, Keelung City 20401, Taiwan (ROC); E-mail: alberttylee@gmail.com

This study was supported by a grant (CMRPG2G0231) from Keelung Chang Gung Memorial Hospital, Taiwan.

The authors report no conflicts of interest.
Copyright © 2019 by Mutaz B. Habal, MD
ISSN: 1049-2275

DOI: 10.1097/SCS.0000000000005427

bone to reach its final position anterior to the trachea by the end of week 7 of gestation.¹ During migration, the gland is connected to the tongue by the thyroglossal duct, which usually atrophies and involutes by week 10 of gestation. If any portion of the duct persists, secretions from its epithelial lining can cause inflammation and form a thyroglossal duct cyst (TGDC).²

Lingual TGDC, located at the base of the tongue, accounts for less than 3% of all TGDC remnant diseases.^{3,4} The size of the cyst may determine the presenting symptoms of the condition. Once infected, lingual TGDC can cause local swelling and pain at the base of the tongue.⁵ Acute supraglottitis or inflammation of the supraglottis, can be a life-threatening disease caused by sudden upper airway obstruction. Because of its proximity to the epiglottis, an acute infection of the lingual TGDC can cause symptoms similar to those of acute supraglottitis. Herein, we report a patient who presented with an infected lingual TGDC that mimicked acute supraglottitis.

PATIENT PRESENTATION

A 49-year-old male visited our emergency department with the chief complaint of throat swelling and pain for 2 days. Additional symptoms were dysphagia with pooling saliva, mild shortness of breath, and difficulty with tongue protrusion. The patient denied any underlying disease or history of head and neck surgeries. His body temperature, pulse, blood pressure, and respiration were all within normal limits. On physical examination, no obvious neck mass was identified. The lateral soft-tissue neck radiograph showed a “thumb sign,” the manifestation of a swollen and enlarged epiglottis, and a “vallecula sign,” the obliteration of the linear air shadow between the base of the tongue and the epiglottis⁶ (Fig. 1A). On flexible laryngoscopy, the lingual side of the epiglottis was cherry red, swollen, and pushed backward, which caused

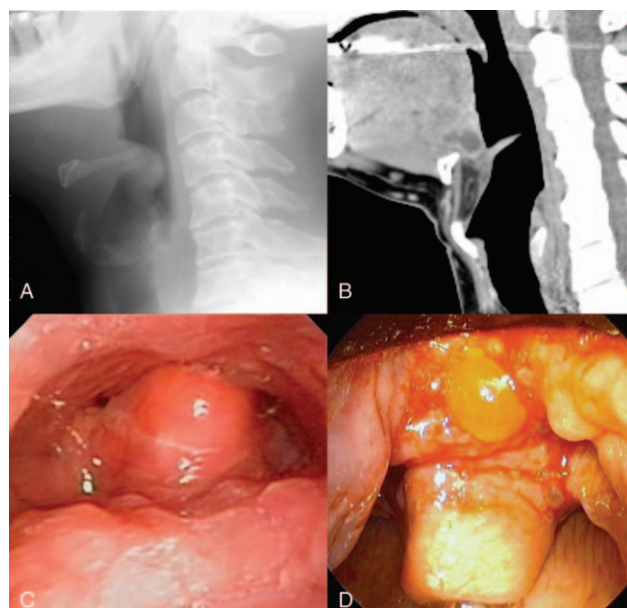


FIGURE 1. (A) The lateral soft tissue neck radiograph showed a “thumb sign,” a manifestation of an swollen and enlarged epiglottis, as well as a “vallecula sign,” the obliteration of the linear air shadow between the base of tongue and epiglottis. (B) On flexible laryngoscopy, the lingual side of epiglottis was cherry-red, swollen, and pushed backward causing about 90% reduction of the airway space. (C) The midline head and neck computed tomography with contrast sagittal view showed a 2.5 cm cystic lesion buried in the tongue base and close to the medial region of the hyoid bone, in favor of lingual thyroglossal duct cyst. (D) During marsupialization, much mucoid discharge from the cyst.