

## CASE REPORT

# Intraventricular haemorrhage and seizures in a patient with dementia: a case of chronic neurobrucellosis

APHRODITE SPYROU, KONSTANTINOS S. NATSIS, EVANGELOS PAPAMICHALIS, HARILAOS MOURTZINOS

Department of Neurology, General Hospital of Serres, Serres, Greece

Address correspondence to: A. Spyrou. Tel: (+30) 23 2109 4505. Email: [aphrodite\\_sp@hotmail.com](mailto:aphrodite_sp@hotmail.com)

## Abstract

Brucellosis is the most commonly reported zoonosis. Nervous system participation can occur at any stage of the disease either in acute or subacute or chronic form. Isolated nervous system involvement or neurobrucellosis is a relatively rare form of the disease. We describe an unusual case of an older patient with dementia with recent onset of seizures in the context of primary isolated intraventricular haemorrhage, diagnosed as chronic neurobrucellosis.

## Keywords

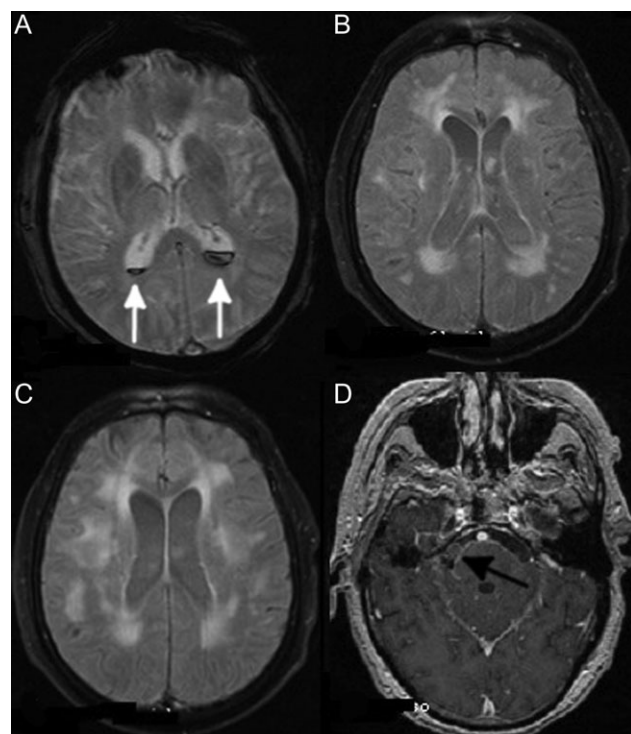
*neurobrucellosis, dementia, intraventricular haemorrhage*

## Introduction

Brucellosis is a bacterial zoonotic infection caused by the bacterial genus *Brucella* and it is transmitted to humans by direct or indirect contact with infected animals or their products. Although brucellosis usually manifests itself as an acute febrile illness, the spectrum of its clinical manifestations is wide since it is a multi-systemic disease. Isolated nervous system involvement or neurobrucellosis is a relatively rare form of the disease. We describe an unusual case of an older patient with recent onset of seizures in the context of primary isolated intraventricular haemorrhage, diagnosed as chronic neurobrucellosis.

A 76-year-old man was admitted to our hospital due to recent-onset generalised tonic-clonic seizures. He had a 3-year history of progressive dementia and neurosensory hearing loss. After the postictal phase the patient was alert, disoriented and afebrile. His systemic examination was unremarkable. Neurologic examination revealed extrapyramidal rigidity, bilateral intention tremor, gait instability and frequent myoclonic jerks in both upper and lower limbs. Neck stiffness and positive Brudzinski sign were also noted. MMSE provided a low score of 15/30 indicating a patient with severe dementia.

Brain MRI showed extended bilateral leucoencephalopathy of the periventricular area (Figure 1B and C) and haemorrhagic material in the ventricular system without signs of subarachnoid haemorrhage in T2\* sequence (Figure 1A). Gadolinium enhancement of the arachnoid was also noted (Fig. 1D). MRA was negative for the presence of aneurysms or stenosis of intracranial vessels. CSF analysis showed 720 cells 60% lymphocytes, 35% polymorphonuclear, 10 mg/dl glucose, 2053 albumin. Serological tests for syphilis, HIV, hepatitis B and C and *Borrelia* were negative. Ziehl-Neelsen staining was also negative. In CSF culture *Brucella* Melitensis was grown. Wright's reaction was negative in blood and positive in the CSF (titre 1:40). PCR in CSF was positive for *Brucella* Melitensis and confirmed the diagnosis of brucellosis. Repeated Wright's test in serum and bone marrow biopsy were reported normal. Quadruple antibiotic treatment with rifampicin 600 mg 1½ × 1 for 1 year, streptomycin 1 g for 6 months, vibramycin 100 mg 1×2 for 1 year and sulfamethoxazole/trimethoprim 800/160 mg 1×2 for 2 months was decided in addition to antiepileptic treatment with lacosamide 100 mg twice daily. In follow up 3 months later the patient was clinically stable and seizure free.



**Figure 1.** (A) Intraventricular haemorrhage in lateral ventricles as shown in T2\* gradient echo (white arrows). (B, C) Extended leukoencephalopathy in the periventricular and subcortical white matter of both hemispheres. (D) Gadolinium enhancement of the arachnoid in T1 Gd+ image (black arrow).

## Discussion

Brucellosis is the most commonly reported zoonosis in our country and the incidence of the disease in Greece is among the highest in Europe. The average annual reported incidence of the disease was 2.2/100,000 population [1]. Nervous system participation can occur at any stage of the disease and has various manifestations. Rarely, neurological findings may be the only manifestation of the disease. It usually takes the form of meningitis or meningoencephalitis either in acute or subacute or chronic form [2, 3]. Dementia and neurosensory hearing loss are common manifestations of chronic neurobrucellosis as in our patient. Diagnosis is usually confirmed by detection of specific antibodies in blood and CSF or positive CSF cultures with positivity in <50% cases [4].

Our patient did not have any systemic manifestation of the disease beyond the neurological signs and symptoms.

Additionally, blood Wright's testing and cultures as well as bone marrow biopsy were negative indicating isolated CNS involvement. Diagnosis of neurobrucellosis based on the isolation of *brucella melitensis* in CSF culture and the positive PCR. In addition to leukoencephalopathy and neurosensory hearing impairment, which are frequent manifestations of nervous system involvement, primary intraventricular bleeding without subarachnoid haemorrhage has not previously been reported in the literature as far as we know.

Inflammation of the blood vessels in neurobrucellosis can be explained by two mechanisms. The first one is the creation of mycotic aneurysms resulting in subarachnoid haemorrhage and the second one is the inflammatory process that occurs at the blood vessels resulting in lacunar infarcts, small haemorrhages, or venous thromboses.

Our case is unique due to the isolated bleeding in the ventricles, without evidence of subarachnoid haemorrhage. However, magnetic angiography did not indicate the presence of aneurysm or vascular lesions.

---

**Declaration of Conflict of Interest:** None.

**Declaration of Sources of Funding:** None.

**Declaration of Patient Consent:** Written informed consent for publication of their clinical details and images was obtained from the patient's proxy.

---

## References

1. EDC. European Centre for Disease Prevention and Control: Annual Epidemiological Report on Communicable Diseases in Europe 2009. Stockholm: European Centre for Disease Prevention and Control, 2009.
2. Neurobrucellosis Kizilkilic O, Calli C. Neuroimaging Clinics of North America, 2011.
3. Shakir RA, Al-Din AS, Araj GF, Lulu AR, Mousa AR, Saadah MA. Clinical categories of neurobrucellosis. A report on 19 cases. *Brain* 1987; 110: 213–23.
4. Haji-Abdollahi M, Rasooli-Nejad M, Jafari S, Hasibi M, Soudbakhsh A. Clinical and laboratory findings in neurobrucellosis: review of 31 cases. *Arch Iran Med* 2008; 11: 21–5.

**Received 3 December 2018; editorial decision 29 January 2019**