

- Kugler, J., Knörl, G., Empt, J. (1973) 'Die Behandlung therapieresistenter Epilipsien mit Dipropylacetat.' *Münchener Medizinische Wochenschrift*, **115**, 1103-1119.
- Voss, H. von, Petrich, C., Karch, D., Schulz, H. U., Göbel, U. (1976) 'Sodium valproate and platelet function.' *British Medical Journal*, **2**, 179.
- Winfield, D. A., Benton, P., Espir, M. L., Arthur, L. J. (1976) 'Sodium valproate and thrombocytopenia.' *British Medical Journal*, **2**, 981.

## Cortical Blindness Associated with Occipital Atrophy: a Complication of *H. influenzae* Meningitis

**Lewis H. Margolis    Bennett A. Shaywitz    Stephen G. Rothman**

### Introduction

Cortical blindness is a rare and generally unexplained complication of bacterial meningitis. This communication reports a case of persistent cortical blindness secondary to *Hemophilus influenzae* type-b meningitis with an associated anatomical lesion in the vicinity of the visual cortex, as determined by computerized axial tomography (CT scan). To our knowledge this is the first description of an associated anatomical abnormality in a child with cortical blindness secondary to bacterial meningitis.

### Case Report

G.A., a three-year-old white male was well until 24 hours prior to admission, when he developed a temperature of 39°C. He was examined at a local hospital and sent home, but later developed a temperature of 40.6°C. He was then admitted to the local hospital and transferred to Yale-New Haven Hospital for evaluation. During the journey he was given a dose of intravenous mannitol (1g/kg) because of a dilated right pupil. On admission he was stuporous and had marked nuchal rigidity. The optic discs were normal bilaterally and the pupils were equally reactive. He did not seem to follow light, but this was difficult to assess because of his stuporous level of consciousness. Examination of the CSF indicated an opening pressure of 300mm H<sub>2</sub>O, CSF glucose 13mg/dl, protein 107mg/dl, 1380 red blood cells and 1300 total nucleated cells, 98 per cent granu-

locytes. Within minutes after the lumbar puncture he suffered a respiratory arrest but was ventilated by 'Ambu' bag within seconds and was soon intubated. Antibiotic therapy was begun with chloramphenicol (100mg/kg/day) and penicillin G (300,000U/kg/day).

Symptoms resolved rapidly and within 24 hours his behaviour became more normal. 48 hours after admission penicillin and chloramphenicol were discontinued and ampicillin (400mg/kg/day) was begun. Four days after admission he developed focal seizures of the right arm and it became clear that his eyes did not follow light. A repeat lumbar puncture indicated non-xanthochromic fluid with an opening pressure of 200mm H<sub>2</sub>O, CSF glucose 64mg/dl, protein 25mg/dl, 1590 red blood cells, and 1080 total nucleated cells, 90 per cent granulocytes. An electroencephalogram demonstrated moderate generalized slowing, most pronounced in the left temporal region. A Technetium brain-scan revealed increased bilateral occipital activity, consistent with subdural empyema or meningeal inflammation. CT scan performed 14 days after admission (Fig. 1) was consistent with hemorrhagic infarction in the occipital area. At the time of discharge the patient continued to exhibit evidence of cortical blindness, as well as minor lower extremity weakness.

Computerized tomography performed 2½ months after his illness demonstrated bilateral occipital atrophy (Fig. 2). In the six months since his discharge there has been no other neurological abnormality apart from persisting cortical blindness: his intellectual development appears to remain normal.

### Discussion

Cortical blindness, characterized by loss of vision with normal pupillary response, has a number of reported causes in chil-

Correspondence to Bennett A. Shaywitz, M.D., Yale University School of Medicine, 333 Cedar Street, New Haven, Connecticut 06510.

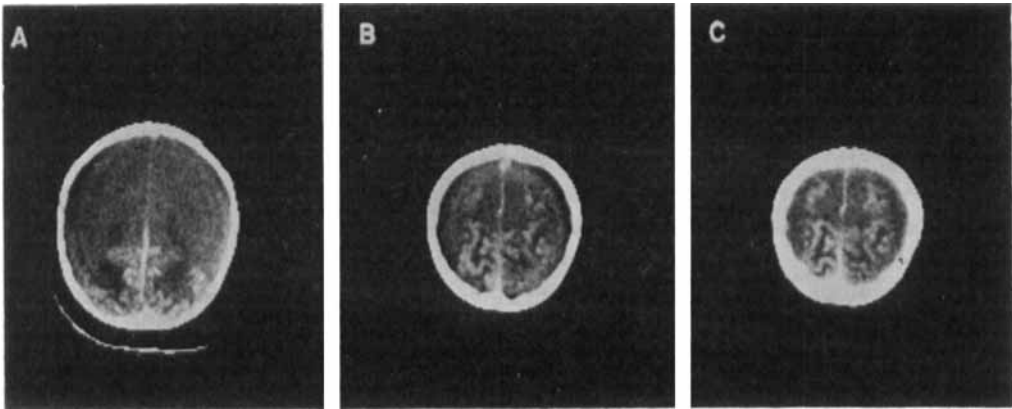
## CASE REPORTS

dren. McAuley (1964) reported a child of 2 years 7 months who suffered a cardio-respiratory arrest and hypothermia after falling through ice. Early in his treatment this child exhibited cortical blindness associated with an abnormal EEG, characterized by "flattening and irregular delta waves", which returned to regular 5-6/sec activity in the occipital area as he regained vision within about eight weeks. Weinberger *et al.* (1962) described three children aged between  $2\frac{1}{2}$  and 3 years who developed temporary cortical blindness following cardiac arrest.

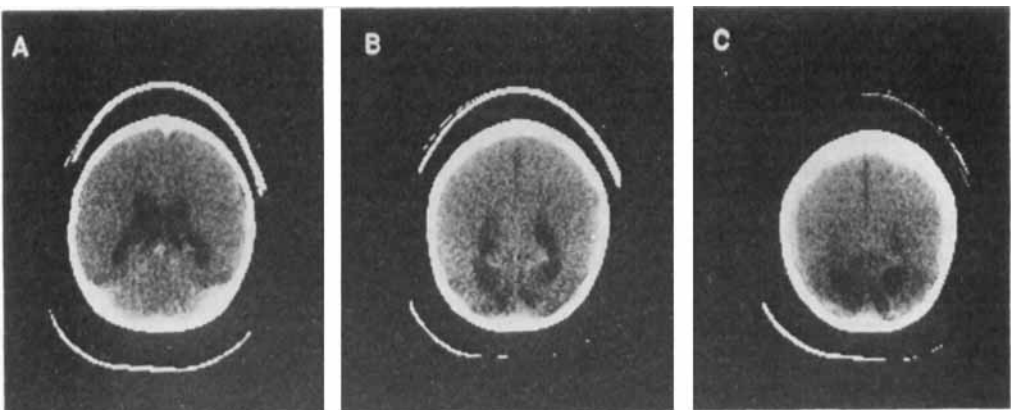
Griffith and Dodge (1968) described six

children with transient cortical blindness secondary to head trauma. In two, electroencephalograms demonstrated bilateral occipital slowing, which resolved, but the authors emphasize the uncertain significance of this finding because posterior slowing frequently follows head trauma in children.

Acers and Cooper (1965) described cortical blindness secondary to bacterial meningitis in two children. One child, four months old, failed to respond to light or other visual stimuli five days after the onset of *H. influenzae* meningitis, but had apparently normal vision one month later.



**Fig. 1.** Serial CT sections through the superior portion of the brain, demonstrating diffuse high density throughout the cortical sulci.



**Fig. 2.** Serial scans done 10 weeks after the acute illness demonstrate symmetrical dilatation of the occipital pole, suggesting localized occipital atrophy.

The second, a five-month-old with pneumococcal meningitis, was still blind at follow-up seven months after the illness.

Barnet *et al.* (1970) examined visual responses (VERS) in six children with cortical blindness and found depressed responses in three patients who remained blind, but normal or near normal VERS in two children who soon regained their vision. In a subsequent study, however, Duchowny *et al.* (1974) suggested that the VERS did not aid in determining a prognosis for the return of vision, although there was correlation between specific VER findings and the concurrent neurological status. They described four cases with proven bacterial meningitis, and in three of these the complication was temporary. The first child, a 16½-month-old with *H. influenzae*, had minimal residual blindness one month after her illness. The second was a 26-month-old girl with meningococcus who recovered from her blindness about six weeks after the meningitis. A 16-month-old boy with *H. influenzae* recovered normal vision by the fifteenth day of illness. However, the fourth child, a 7½-month-old girl, remained blind and was severely intellectually retarded following pneumococcal meningitis.

The mechanism of cortical blindness associated with meningitis remains ill-defined. Pathologically, subarachnoid exudate, arteritis, focal necrosis of veins, thrombophlebitis, subdural exudate and temporary venous occlusion have all been described and may relate to the pathogenesis of cortical damage (Adams *et al.* 1948, Smith and Landing 1965). Dodge and Swartz (1965) emphasized that cortical damage can only in part be explained by anatomical findings and that a 'toxic factor', aspiration, shock, fever and increased CSF pressure may all contribute to brain damage.

We have described a case of cortical blindness following *H. influenzae* menin-

gitis in a three-year-old boy. A Technetium scan demonstrated increased uptake in the occipital area, consistent with an effusion or inflammation. 11 days later, computerized tomography showed a serpiginous high-density structure corresponding to the cortical gyral pattern and thought to be cortical hemorrhagic infarction. One mechanism to explain the hemorrhage is transtentorial herniation of the temporal lobes, leading to transient compression of the posterior cerebral arteries. The dilated pupil, the high opening CSF pressure, the presence of 1380 red blood cells, and the respiratory arrest support this possibility. However, if the hemorrhage had occurred secondary to herniation, we would have expected the CT scan to demonstrate more resolution of blood two weeks after the presumed event. This suggests that the hemorrhage occurred at a later time in the illness. Another possible mechanism is that venous occlusion, arteritis or thrombophlebitis may have produced the hemorrhage. Finally, it is possible that the initial effusion on Technetium scan was a thick exudate which resulted in cerebral necrosis, but the clinical course is not consistent with a significant subdural effusion. When the blindness persisted, a repeat CT scan 10 weeks later demonstrated symmetrical dilatation of the occipital poles, suggesting localized occipital atrophy.

The persisting blindness six months later and the established atrophy demonstrated by computerized tomography make it unlikely that this child will recover his vision.

*Acknowledgement:* This study was supported in part by a grant from The National Institute of Health (NS 12384).

#### AUTHORS' APPOINTMENTS

Lewis H. Margolis, M.D., Instructor in Pediatrics; Bennett A. Shaywitz, M.D., Associate Professor of Pediatrics and Neurology; Stephen G. Rothman, M.D., Associate Professor of Radiology; Yale University School of Medicine. New Haven, Connecticut 06510.

## CASE REPORTS

### SUMMARY

A three-year-old child with *H. influenzae* meningitis developed cortical blindness. Computerized tomography demonstrated occipital hemorrhage, and a subsequent scan showed occipital atrophy. The literature on cortical blindness in children is reviewed. This is the first description of cortical blindness secondary to meningitis with an associated anatomical defect.

### RÉSUMÉ

*Cécité corticale associée à une atrophie occipitale:  
complication d'une méningite à Hémophilus influenzae*

Un garçon de trois ans, atteint de méningite à *H. influenzae*, présente une cécité corticale. Une tomo-densitographie montra des hémorragies occipitales et un scanner ultérieur révéla une atrophie occipitale. Il s'agit là de la première description d'une cécité corticale secondaire à une méningite avec altération anatomique associée.

### ZUSAMMENFASSUNG

*Corticale Blindheit mit occipitaler Atrophie:  
eine Komplikation der H. influenza Meningitis*

Bei einem dreijährigen Jungen trat nach einer *H. influenza* Meningitis eine corticale Blindheit auf. Die Computertomographie zeigte eine occipitale Blutung und spätere Kontrolluntersuchungen ergaben eine occipitale Atrophie. Dies ist die erste Beschreibung einer corticalen Blindheit nach Meningitis mit einem anatomischen Defekt.

### RESUMEN

*Ceguera cortical asociada con atrofia occipital:  
una complicación de la meningitis por H. H. influenzae*

Un niño de tres años de edad con meningitis por *H. H. influenzae* desarrolló una ceguera cortical. La TAC demostró una hemorragia cerebral y los Scanners subsiguientes mostraron una atrofia occipital. Esta es la primera descripción de ceguera secundaria a meningitis con un defecto anatómico asociado.

### REFERENCES

- Acers, T. E., Cooper, W. C. (1965) 'Cortical blindness secondary to bacterial meningitis.' *American Journal of Ophthalmology*, **59**, 226-229.
- Adams, R. D., Kubik, C. S., Bonner, F. J. (1948) 'Clinical and pathological aspects of influenzal meningitis.' *Archives of Pediatrics*, **65**, 354-376; 408-441.
- Barnet, A. B., Manson, J. I., Wilner, E. (1970) 'Acute cerebral blindness in children,' *Neurology*, **20**, 1147-1156.
- Dodge, P. R., Swartz, M. N. (1965) 'Bacterial meningitis—a review of selected aspects. II. Special neurologic problems, postmeningitis complications and clinico-pathological correlations.' *New England Journal of Medicine*, **272**, 1003-1010.
- Duchowny, M. S., Weiss, I. P., Majlessi, H., Barnet, A. B. (1974) 'Visual evoked responses in childhood cortical blindness after head trauma and meningitis.' *Neurology*, **24**, 933-940.
- Griffith, J. F., Dodge, P. R. (1968) 'Transient blindness following head injury in children.' *New England Journal of Medicine*, **278**, 648-651.
- McAuley, F. D. (1964) 'Prolonged visual failure following cardiac arrest due to accidental hypothermia.' *British Journal of Ophthalmology*, **48**, 628-629.
- Smith, J. F., Landing, B. H. (1965) 'The clinical and pathological aspects of influenzal meningitis.' *Journal of Neuropathology and Experimental Neurology*, **19**, 248-265.
- Weinberger, H. A., van der Woude, R., Maier, H. C. (1962) 'Prognosis of cortical blindness following cardiac arrest in children.' *Journal of the American Medical Association*, **179**, 126-129.